



# EDT Journal

European Journal for  
Dental Implantologists



## Implant Placement and Immediate Final Rehabilitation

A Contribution by Axel Kirsch, DDS, DMD, Rainer Nagel, DDS, Dentist,  
Gerhard Neuendorff, MDT, Janez Fiderschek, MDT, and Karl-Ludwig  
Ackermann, DDS, DMD, all Filderstadt/Germany



Kindly offered by:

**camlog**



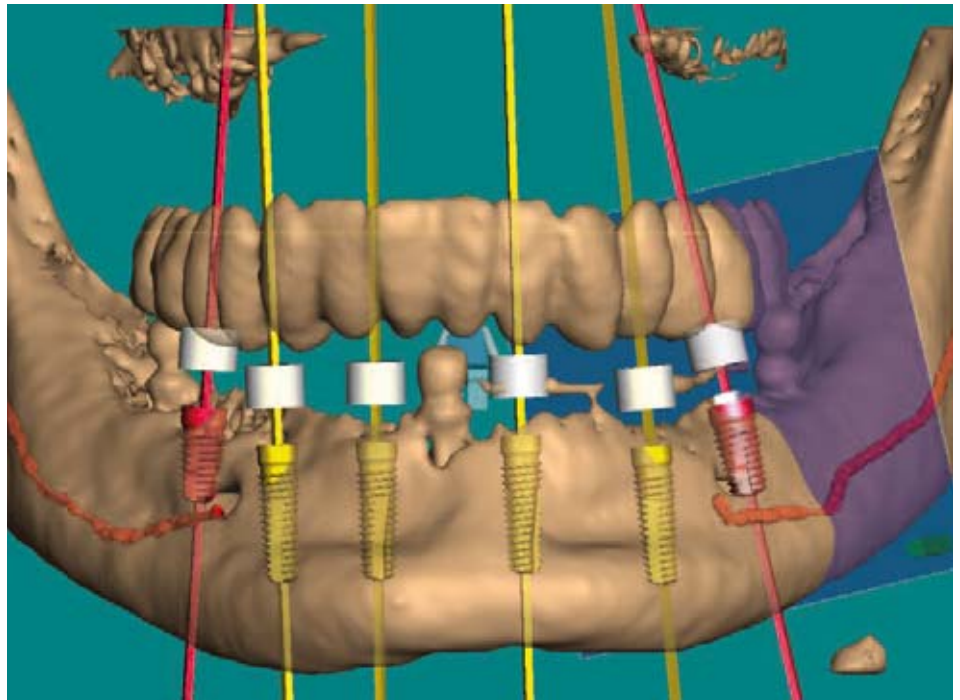
NEW IMPLANTS, NEW ABUTMENTS  
**LIBERTY OF CHOICE**  
NATURALLY FROM **CAMLOG**

Reliable implants, patented Tube-in-Tube™ connection, and from now on as an option: platform switching. Camlog offers more. More information: [www.camlog.com](http://www.camlog.com)

a perfect fit®

**camlog**

CT based three-dimensional planning giving rise to stent-guided implant placement and immediate delivery of a final rehabilitation



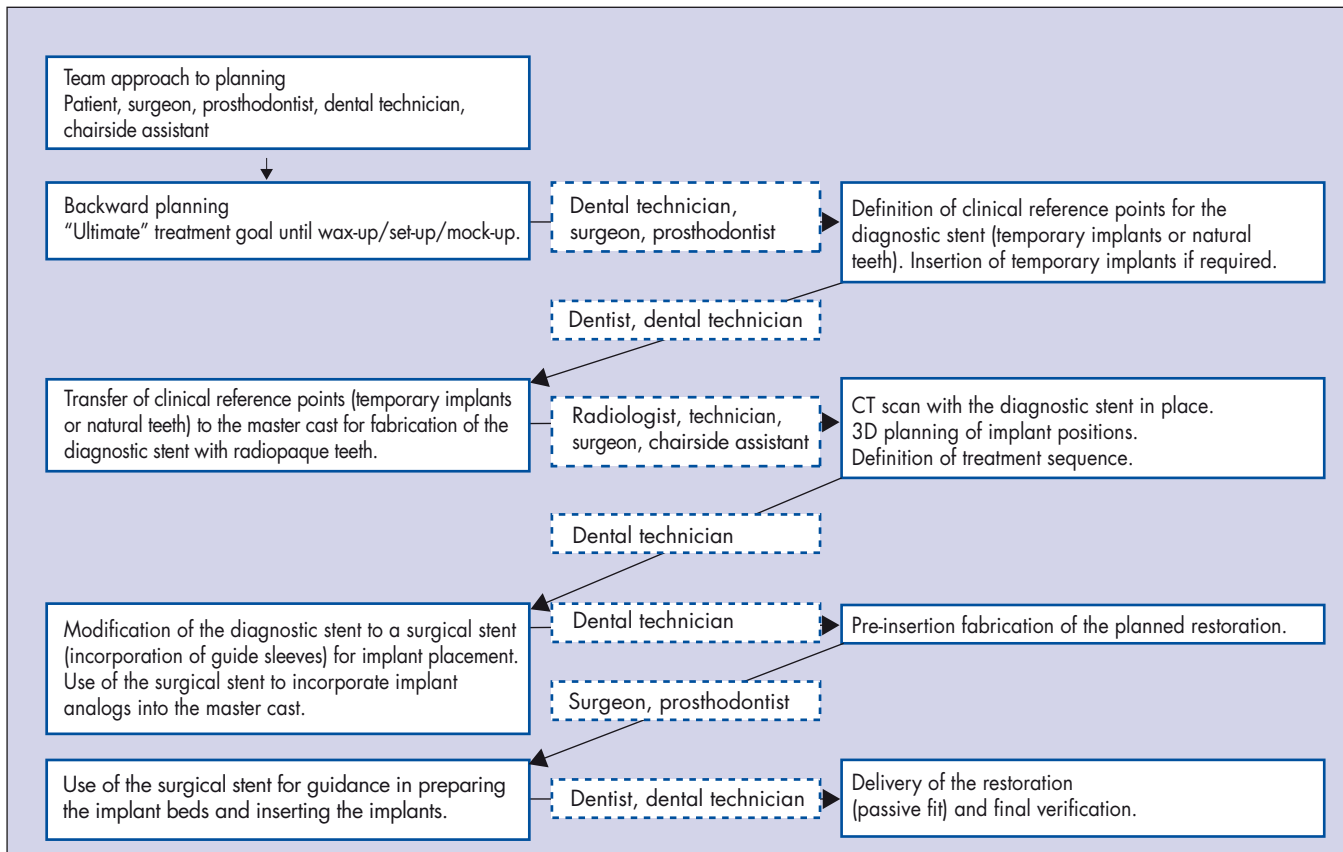
# Implant Placement and Immediate Final Rehabilitation

Axel Kirsch, DDS, DMD, Rainer Nagel, DDS, Dentist, Gerhard Neuendorff, MDT, Janez Fiderschek, MDT, and Karl-Ludwig Ackermann, DDS, DMD, all Filderstadt/Germany

**New technology allows for the placement of dental implants and the final rehabilitation at the same visit. This requires precise three-dimensional radiographics, exact reproduction of the clinical situation in the dental laboratory, construction of a surgical stent which rigidly controls implant placement and fabrication of the final rehabilitation. Extensive collaboration of the clinical, diagnostic and laboratory teams are required. A case presenting with an edentulous mandible is used to illustrate the protocol. Using the Camlog Guide technology the final rehabilitation is placed immediately following implant placement.**

For three-dimensional planning based on CT scanning, the reference points of the clinical situation need to be precisely transferred to the planning template. Experience has shown that mucosa-supported surgical stents are inadequate for this purpose. This can be overcome by using temporary implants or reference points on natural teeth for fixation and reference. These reference points can be used to position the diagnostic stent back precisely on the master cast. After the chosen positions for the implants have been determined using the standard rules of backward planning, drilling sleeves are secured precisely onto the template. This allows precise placement of the implant analogs into the mas-

ter cast in terms of position, depth and axial orientation. The technician can only fabricate a precisely fitting final rehabilitation prior to implant placement if the master cast accurately reflects the implant position that will be achieved. The same stent can then be used during the surgical procedure, enabling implants to be inserted in the mouth exactly as planned on the master cast. Precise transfer is ensured, as the initial reference points are used again. Essential requirements for this purpose include high-precision accessories which are included with the Camlog Guide system and exact adjustment of all equipment during positioning of the guide sleeves.



### Extended backward planning (overview)

#### 1. Evaluation and documentation of baseline situation (history and findings)

This will give rise to a record showing the baseline condition of the oral system and its deficits.

#### 2. Definition of potential rehabilitation

Options of functional and aesthetic restoration are discussed and coordinated in a team-oriented approach.

#### 3. Definition of fixation points for the stent for the CT scan, planning, implant placement and final restoration

Any temporary implants that may be required are placed at this time.

#### 4. Transfer of reference/fixation points to the master cast

A planning template with radiopaque teeth is fabricated on the master cast.

#### 5. CT scan with the diagnostic stent in place, followed by 3D implant planning

Treatment options are discussed in a team-oriented approach, including the patient's input. The patient is informed about any risks as well as about any functional or aesthetic limitations of therapy. Alternative options are discussed.

#### 6. Definition of the treatment sequence

Treatment steps are defined in terms of sequence and scope. The anticipated result is outlined.

#### 7. Modification of the diagnostic stent to a surgical stent

Based on the data supplied by the CT analysis software, drilling sleeves are polymerized into the planning stent. These sleeves are used to position implant analogs into the master cast.

#### 8. Fabrication of the restoration

As the implant position has been precisely defined on the master cast and this can be reproduced intraorally, the rehabilitation can be fabricated prior to implant placement.

#### 9. Implant insertion

With the help of the surgical stent, the implants are precisely positioned in terms of location, depth and axial orientation.

#### 10. Delivery of the rehabilitation

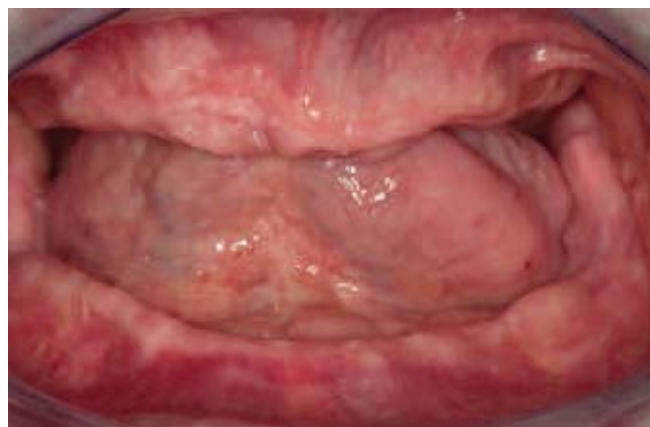Following abutment connection and wound closure, the previously completed rehabilitation is delivered. Tolerances cannot be completely avoided, but the passive-fit technique with appropriate abutments is able to compensate for these inaccuracies.

The Camlog Guide system allows for template-guided preparation of implant sites and insertion of Camlog Screw Line implants. These can be immediately restored with a temporary or definitive rehabilitation. Alternatively, they can be restored following osseointegration. Currently implemented planning software includes implant3D (med3D) and coDiagnostix (IVS).

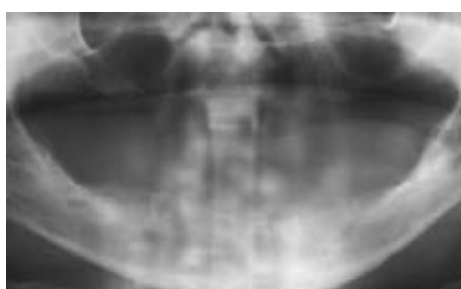**Case report: Edentulous mandible**

**Screw-retained fixed denture using  
Camlog Guide technology**

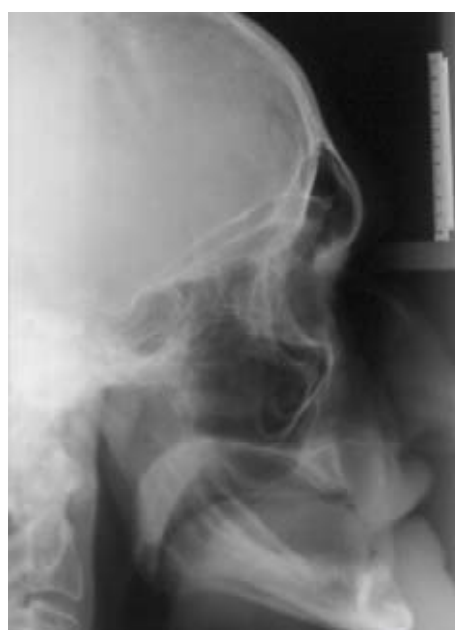The case of a 64-year-old male with an atrophic edentulous mandible is presented. His denture was unstable and accompanied by a loss of occlusal vertical dimension (Figs. 1 to 6).



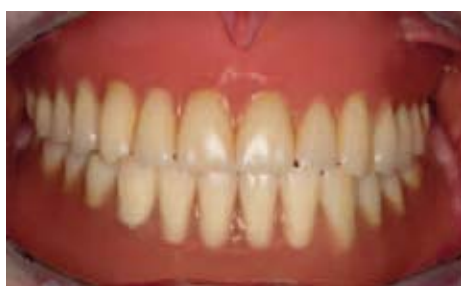*Fig. 1 Frontal view of the patient at presentation.*



*Fig. 2 Panorex view of the baseline situation.*



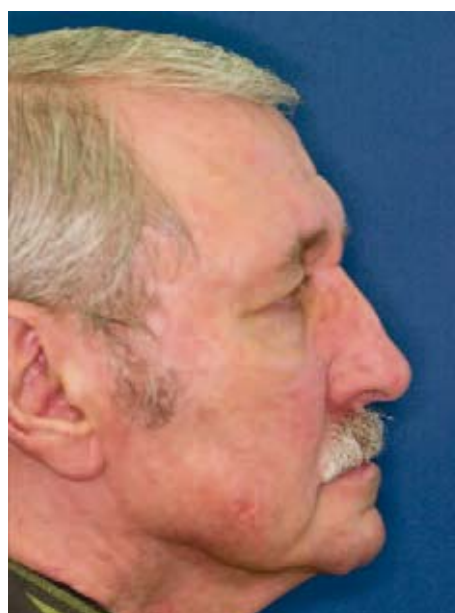
*Fig. 3 Lateral cephalograph of the baseline situation.*



*Fig. 4 Existing dentures in intercuspation.*



*Fig. 5 Facial view of the patient.*



*Fig. 6 Profile view of the patient.*

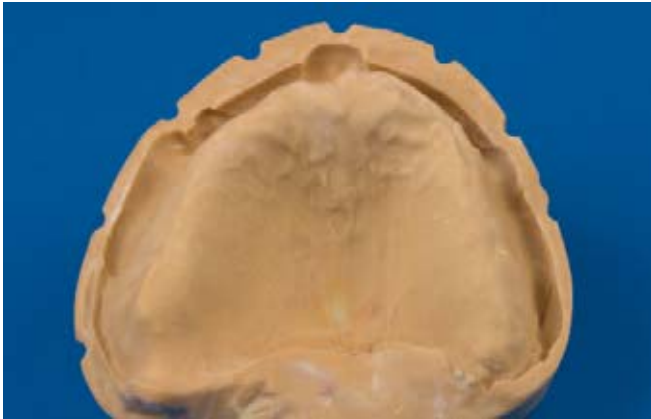

Fig. 7 Diagnostic cast of the maxilla.

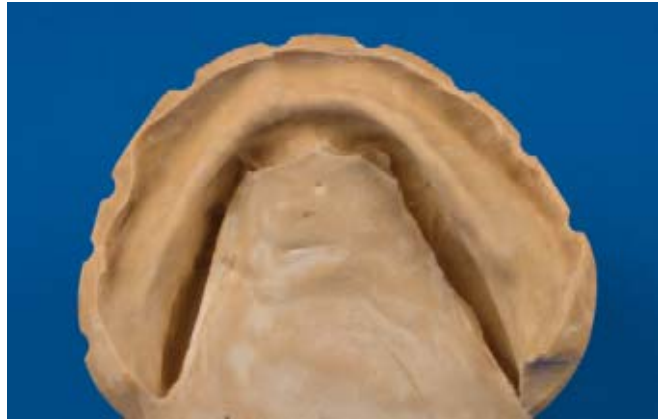

Fig. 8 Diagnostic cast of the mandible.

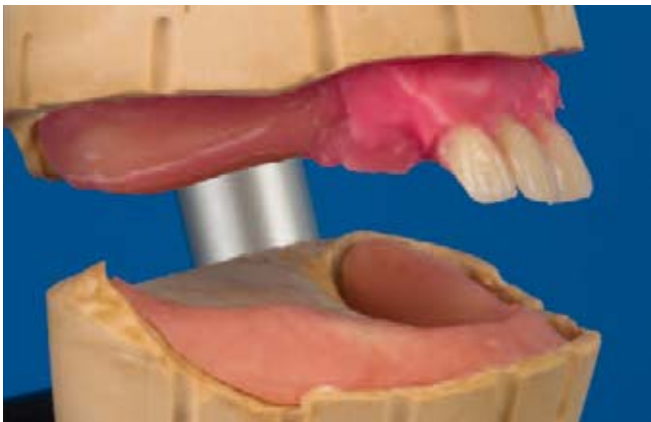

Fig. 9 Set-up of the anterior teeth.

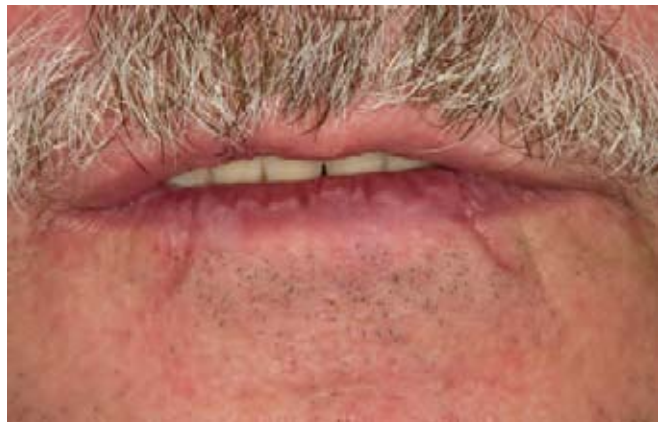

Fig. 10 Aesthetic verification of the anterior tooth set-up.

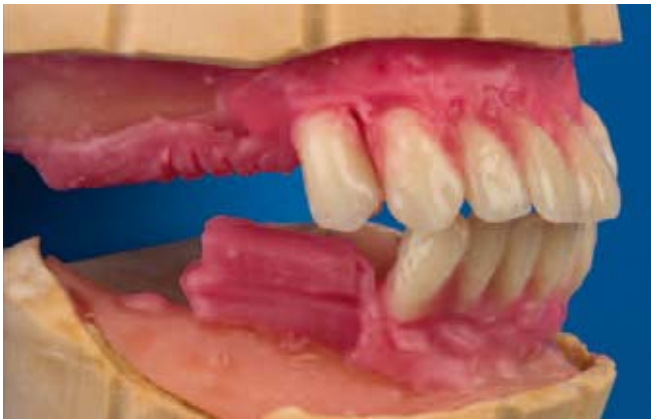

Fig. 11 Set-up of the mandibular anterior teeth.

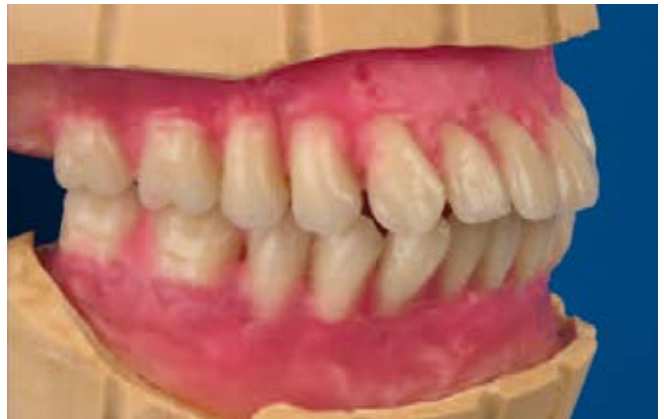
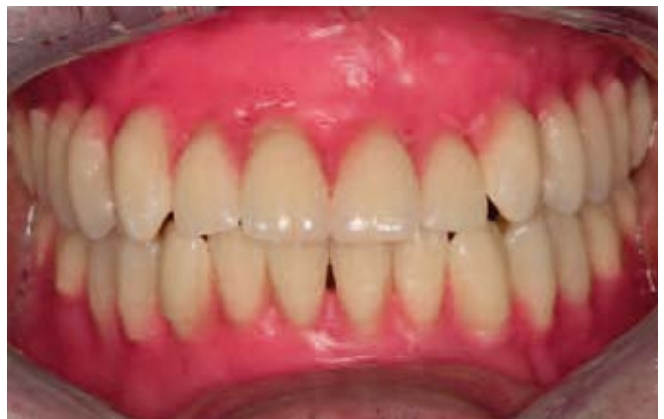
Fig. 12 Completed set-up of both dentures.

An ideal wax-up was performed and tried in the patient to test out phonetic, functional and aesthetic requirements. After approval, the wax-up was used as the foundation for the design and construction of the surgical stent and for the final definitive rehabilitation (Figs. 7 to 13).

Fig. 13  
Functional and aesthetic try-in.



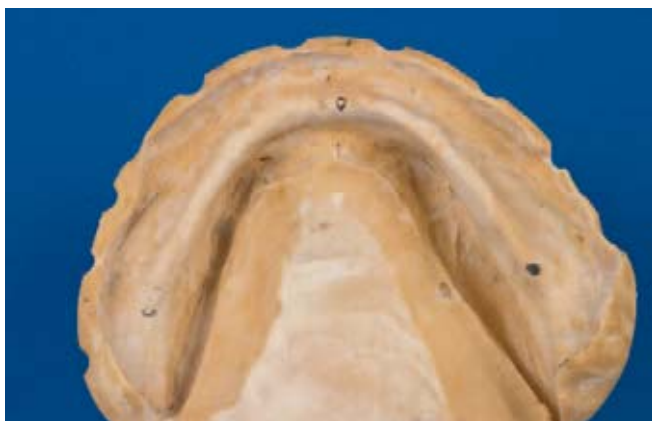

Fig. 14 Markings for the temporary implants.

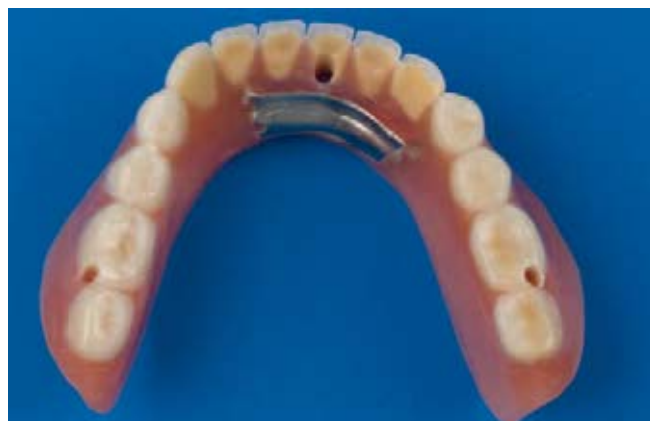

Fig. 15 Existing denture with drill holes for positioning.

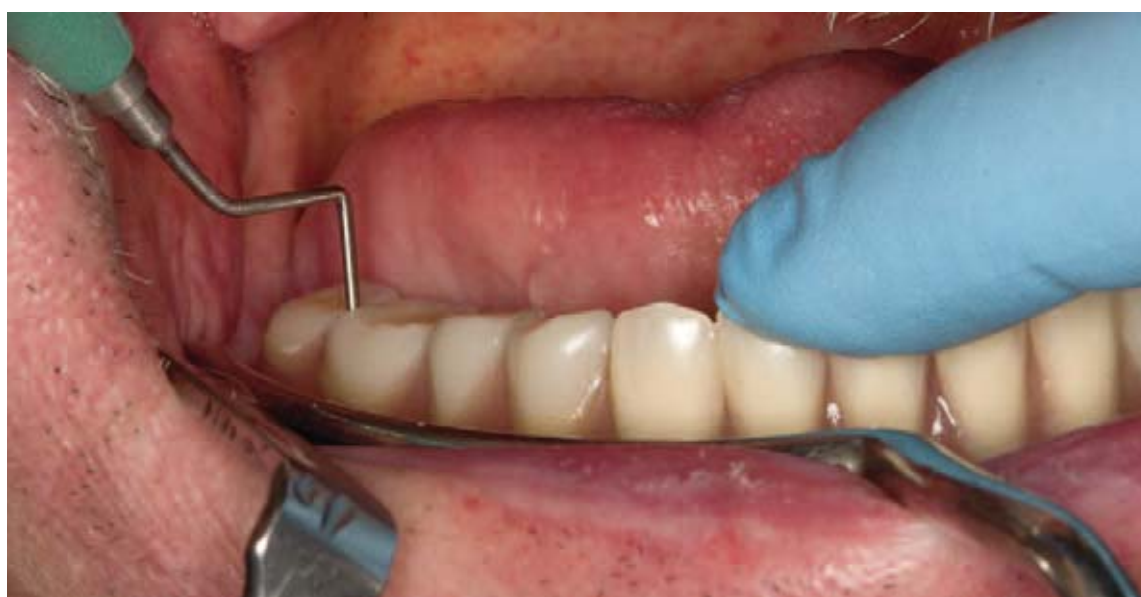

Fig. 16  
A probe is used to transfer the positions for the temporary implants to the patient's mouth (puncture incision).

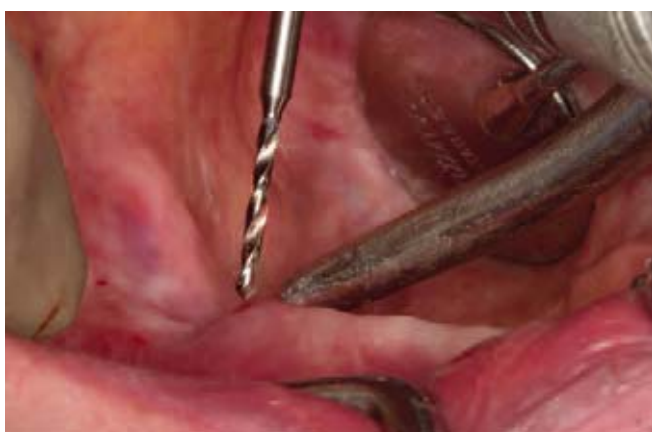

Fig. 17 A twist drill is used to place the temporary implants transgingivally.

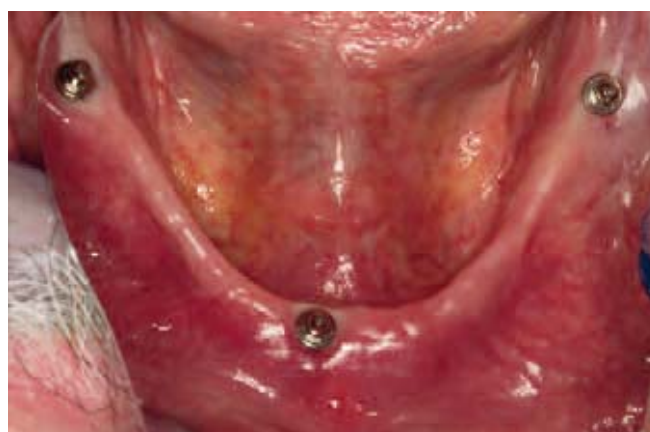

Fig. 18 Temporary implants in situ. The broad-based triangular configuration is clearly visible.

A preliminary cast was used to define the position of the temporary implants (Fig. 14). A wide-spaced triangular configuration serves best for appliance stabilization. These temporary implants must not be placed where the definitive implants are anticipated. They are critical for maintaining stability, precision and control throughout the whole process. For their

placement, holes are drilled into the existing denture (Fig. 15). A probe is then passed through these holes and into the mucosa to mark the desired position (Fig. 16). Temporary 11 mm long small diameter screw implants with ball attachments are then placed transgingivally in those locations (Figs. 17 and 18).

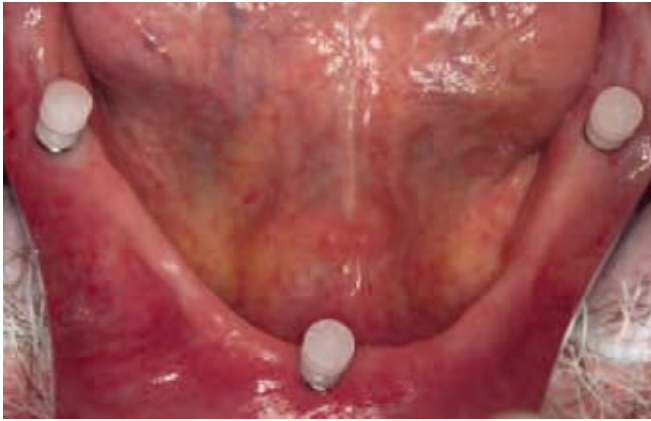

Fig. 19 Impression copings placed on the temporary implants.

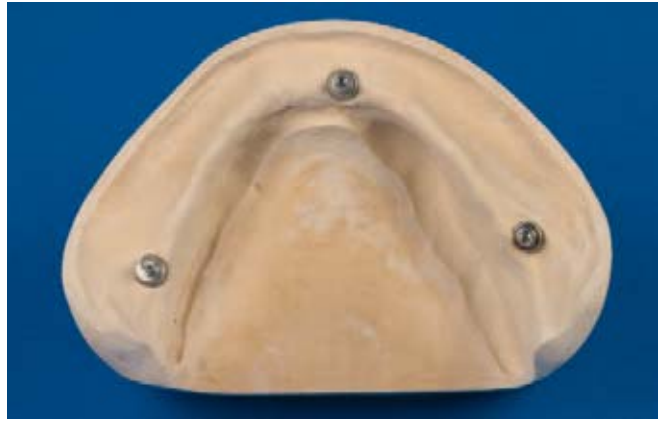

Fig. 20 Master cast with laboratory analogues of the temporary implants (ball attachments).

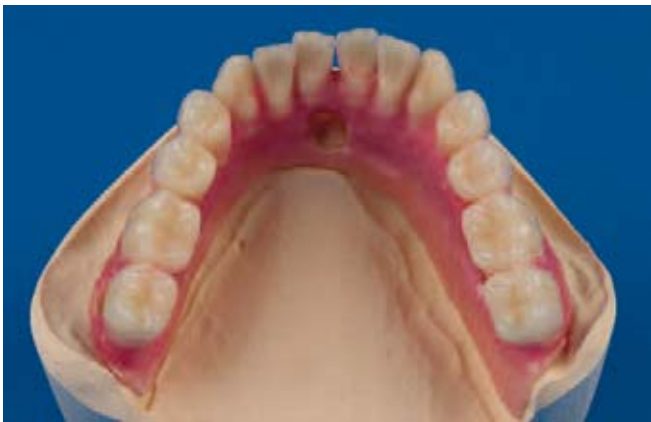

Fig. 21  
Master cast with the  
mandibular arch set-up.  
Note the recesses to  
accommodate the ball  
attachments.

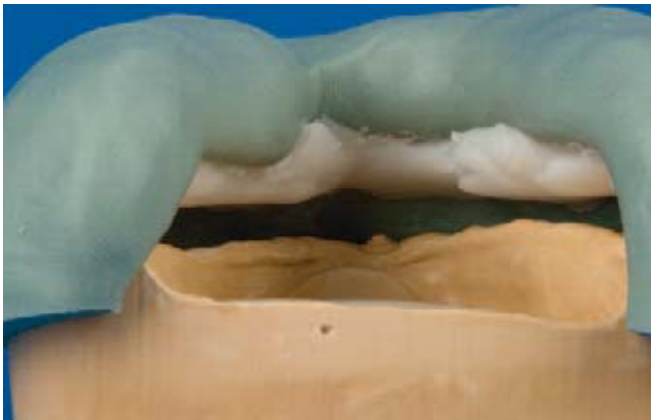

Fig. 22 Silicone bite rim with the radiopaque dental arch.

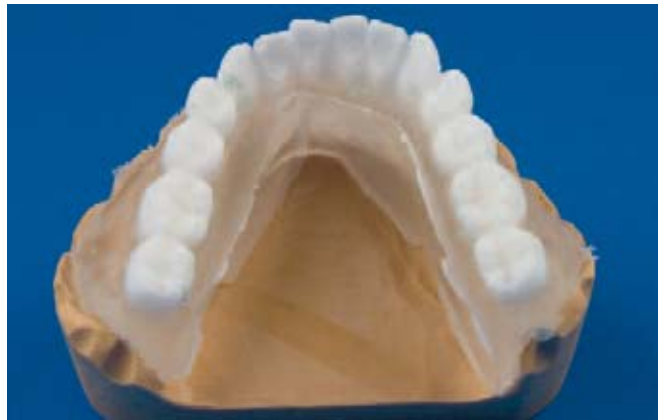

Fig. 23 CT diagnostic stent.

After taking the final impression, a master cast was created (Figs. 19 and 20) and the previously set-up denture was adjusted to fit this cast (Fig. 21). A silicone putty matrix covering over the teeth of the set-up and down to the model base was made. When cured this was removed and the set-up was removed from the master cast. A mixture of acrylic resin with barium sulphate was then poured into the portion of the matrix containing the teeth. This reproduced the arch of teeth and would be the radio-opaque foundation of the diagnostic stent used for the CT survey. After taking care to block out the ball attachments of the temporary implants the space between the radiopaque arch

and the master model was filled in with transparent acrylic (Figs. 22 and 23). The process of fabricating the CT diagnostic stent was completed by incorporating a radiopaque toy brick as a baseline reference unit for orientation within the implant3D planning software. Safety markers provide additional verification (Figs. 24 and 25). For precise transfer of the positions of the temporary implants to the CT diagnostic stent, the housings of the ball attachments were secured in place right in the patient's mouth with self-curing resin (Figs. 26 to 29). Finally, an orthopantomograph was obtained to verify that the housings were correctly seated on the ball attachments (Fig. 30).



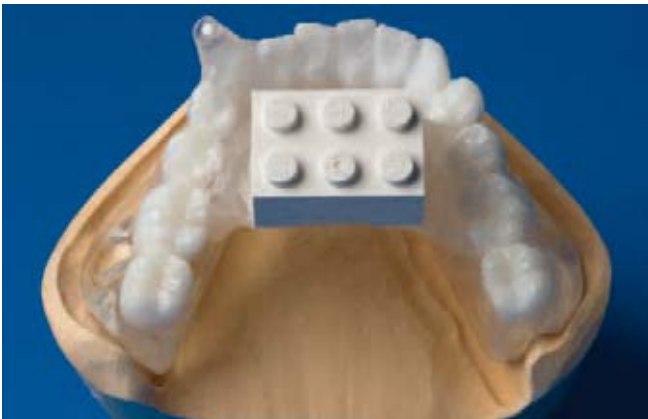

Fig. 24 CT diagnostic stent with a toy brick and safety markers for reference.



Fig. 25 Detail of the safety markers.

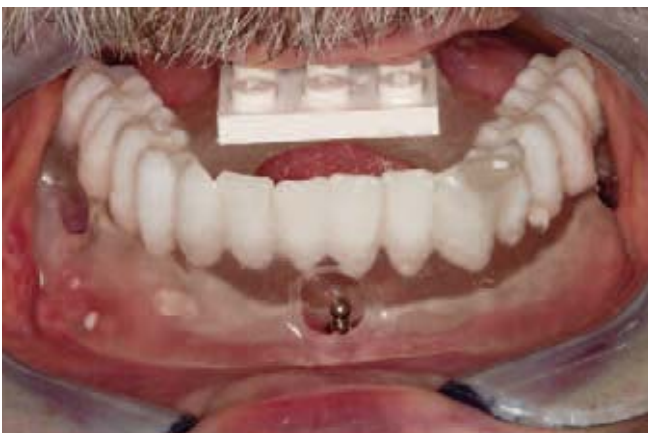

Fig. 26 CT diagnostic stent in situ. The holes for the ball attachments are clearly visible.

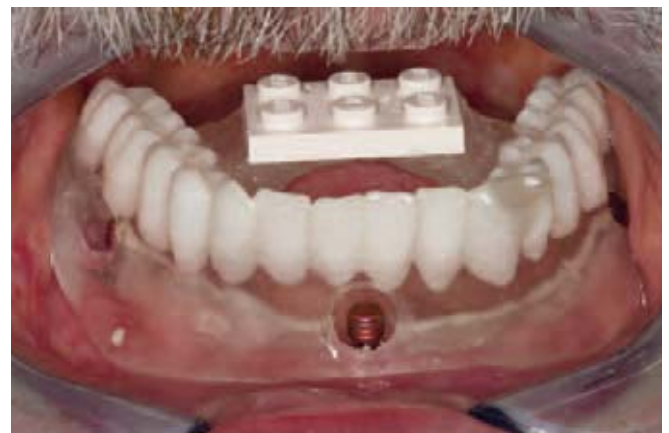

Fig. 27 CT diagnostic stent in situ. The matrices of the ball attachments have been placed on the temporary implants.

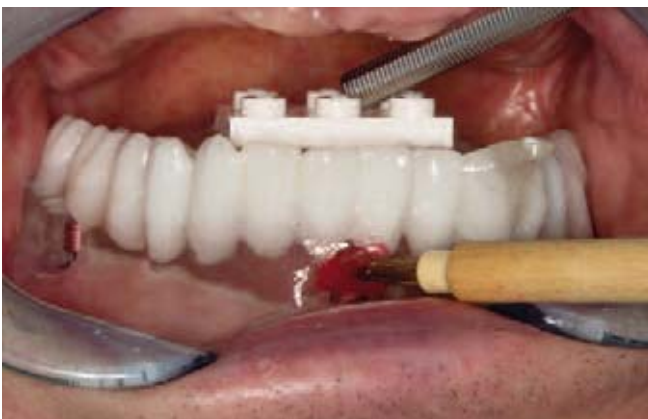

Fig. 28 Intraoral polymerization of the housings placed on the temporary implants.

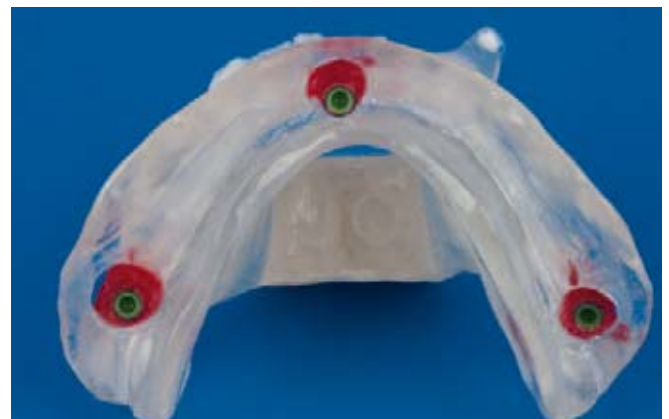
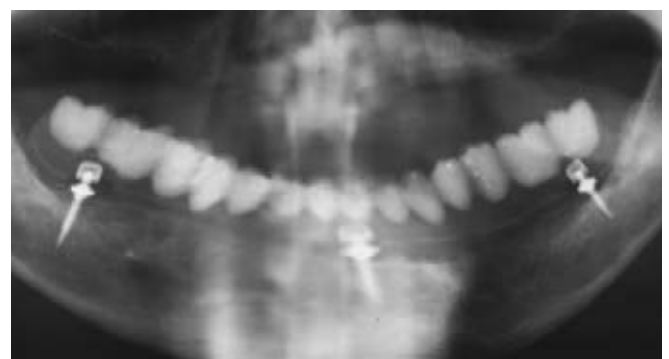
Fig. 29 Basal view of the CT template with polymerized housings.

Fig. 30  
Verification radiograph  
of the CT diagnostic stent.  
The gap between the ball  
attachment and the  
housing is due to a non-  
radiopaque intermediate  
resin component.



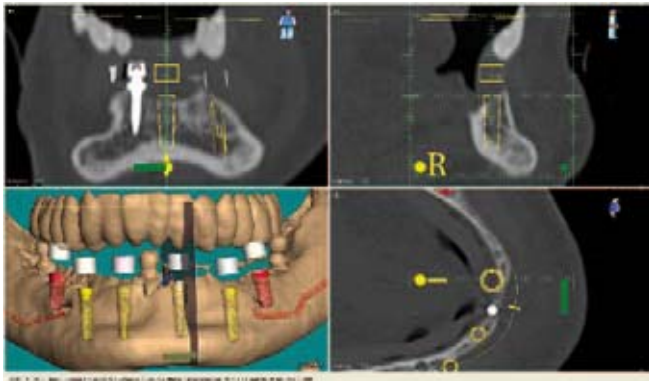


Fig. 31 Three-dimensional planning of an implant at site 32 using the med3D software. It is evident that the diagnostic stent is correctly positioned on the ball attachments.

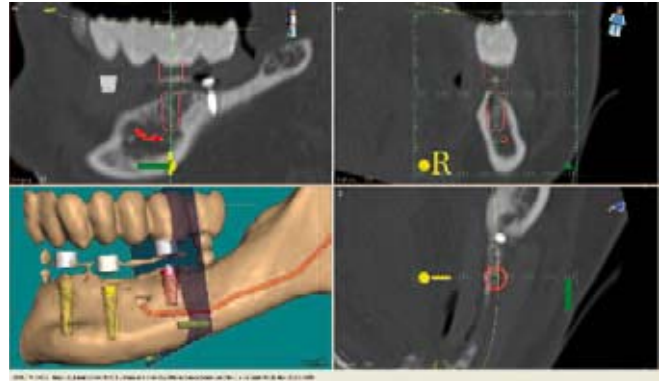


Fig. 32 Three-dimensional planning of an implant at site 35. If the inferior alveolar nerve is repositioned labially, an implant of optimal length can be selected.

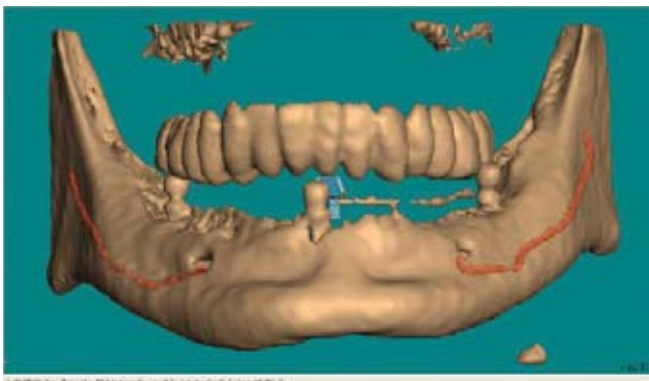


Fig. 33 Three-dimensional view in med3D. Only the radiopaque arch of the stent is illustrated. The inferior alveolar nerve is indicated by the lines.

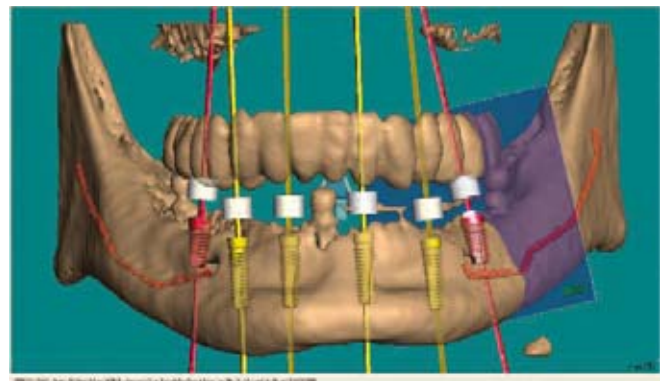


Fig. 34 Three-dimensional view in med3D with the planned implants in view. Divergent implant axes can be minimized by viewing long axial projections.

Once the CT scan had been obtained, implant planning could proceed. The CT data was scanned and adjusted (with the toy brick serving as the baseline reference for orientation). Virtual implant placement was performed using a restoratively driven approach, derived primarily from the desired tooth position as shown by the radiopaque dental arch on the diagnostic CT stent. Anatomical parameters, including jaw configurations and nerve locations, also needed to be taken into consideration (Figs. 31 to 35). Following adjustment of the hexapod (zero position), gypsum was used to mount the diagnostic stent inside the device (Fig. 36). Again, the toy brick was used as the baseline reference. In this specific case, the diagnostic stent was inserted with the device exactly in zero position. Upon completion of the analysis, the implant3D planning software generated a list with specific parameters for adjustment of the hexapod, for the safety markers and for each sleeve position. The mounted stent can be moved in all three dimensions by adjusting the length of the legs (Fig. 37). Once the height stop had been adjusted with the feeler tip, the safety markers were checked (Fig. 38). If these did not agree, then the data transfer between the computer and laboratory could be considered



Fig. 35 Laboratory instruments included with the Camlog Guide system.

Camlog Guide laboratory instruments include a template drill, placement instrument, verification pin, implant analogs, implant mounts and guide sleeves (yellow = 3.8 mm; red = 4.3 mm).

flawed. If that was the case, then the stent would have had to be remounted with gypsum again. Prior to drilling the sleeve holes, the sleeve placement instrument was inserted in line with the sleeve, and the depth stop was calibrated to zero using the reference brick (Fig. 39). The legs were adjusted to match the sleeve, the special drill was applied and the sleeve placed using a light-curing resin for stabilization (Figs. 40 to 42).

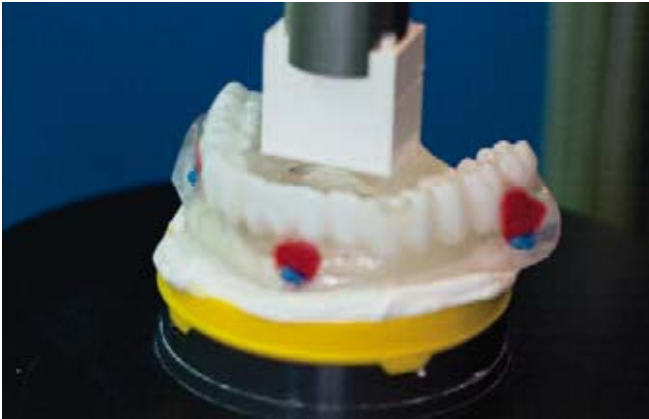


Fig. 36 The CT diagnostic stent is attached and secured to the sleeve positioning device with gypsum.



Fig. 37 Adjusting the lengths of the hexapod legs.

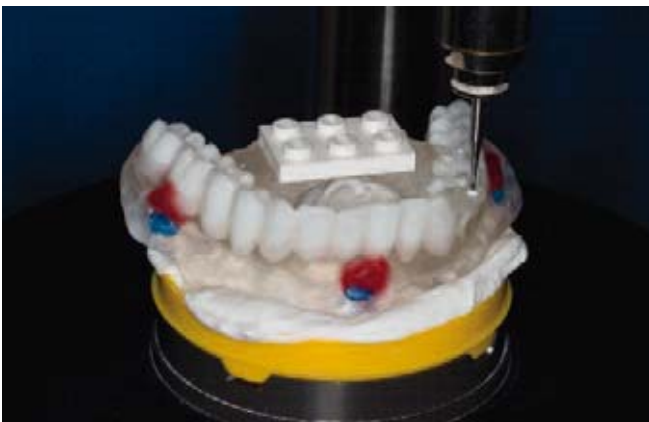


Fig. 38 Verification of the left safety marker.




Fig. 39 Calibration of depth stop prior to positioning the guide sleeves.

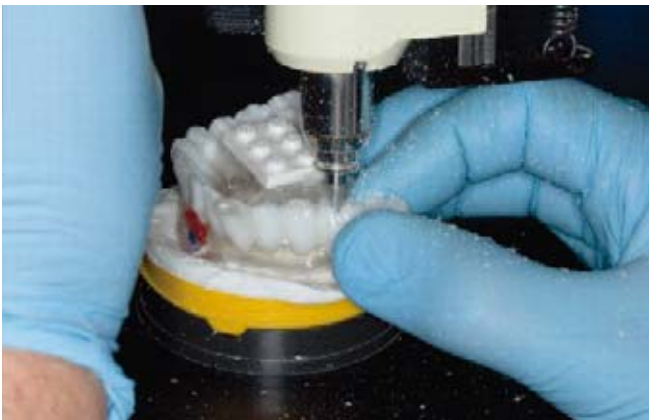


Fig. 40 Drilling of the sleeve channel.



Fig. 41 Sleeve placement instrument with a sleeve (4.3 mm in diameter) attached.



Fig. 42  
Application of  
a light-curing  
adhesive.




Fig. 43 The guide sleeve is lowered to the depth stop.



Fig. 44 Light-curing of the adhesive.

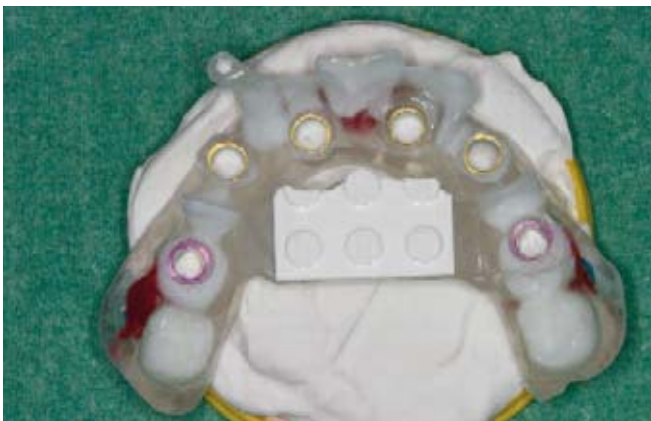

Fig. 45 The holes in the master cast must be drilled such that the laboratory implants can be simultaneously inserted. If necessary, the holes need to be expanded.




Fig. 46 Sheet of paper with printed verification markings.

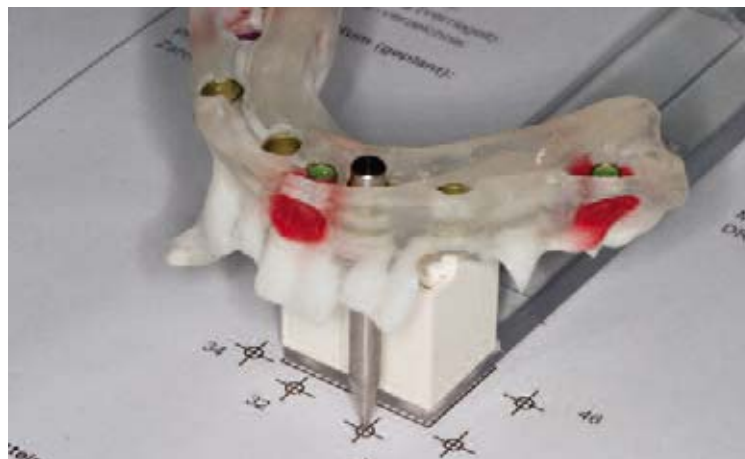


Fig. 47 Template on the verification board, with the verification pin inserted.

The sleeve holder needed to be lowered until the depth stop was reached (Figs. 43 and 44). Once all the sleeves were firmly in place, the diagnostic stent was carefully removed from the device and cleaned (Fig. 45). To allow space for insertion of the contra-angle handpiece during the surgical procedure, the resin teeth of the diagnostic stent was then reduced down to the level of the sleeve. To verify the position and axial orientation, a paper hardcopy with printed verification markings was mounted to a verification board along with the template (Fig. 46). The tip of the

pin must hit the centre of each marking (Fig. 47). This verification ensured that the template had been accurately fabricated and that the sleeves were accurately positioned. Any and all discrepancies must be corrected before the stent can be used clinically as a surgical guide stent. After repositioning the template on the master cast (making sure that the female attachments clicked into place), the intended implant positions were marked on the cast. A gypsum cutter created holes for the implant analogs (Figs. 48 to 51). The mounts carrying the screw

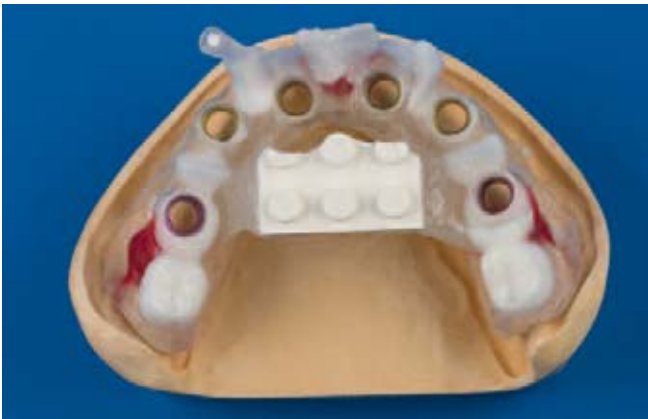

Fig. 48 Completed template, placed on the master cast.

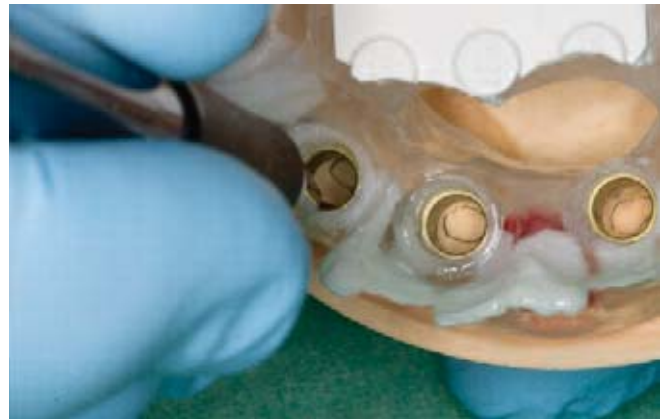

Fig. 49 Marking of implant position through the sleeve.

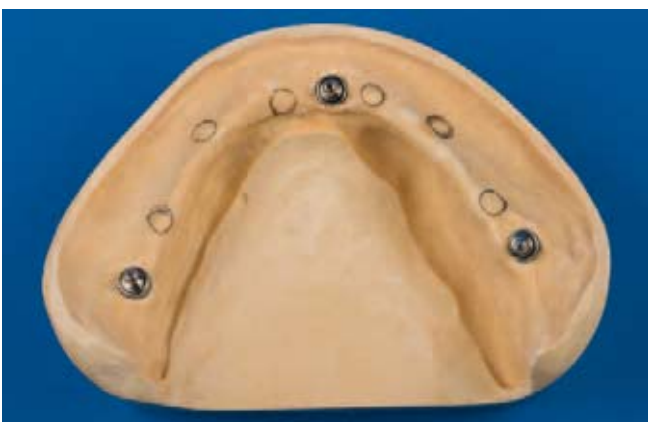

Fig. 50 Master cast with implant positions marked.

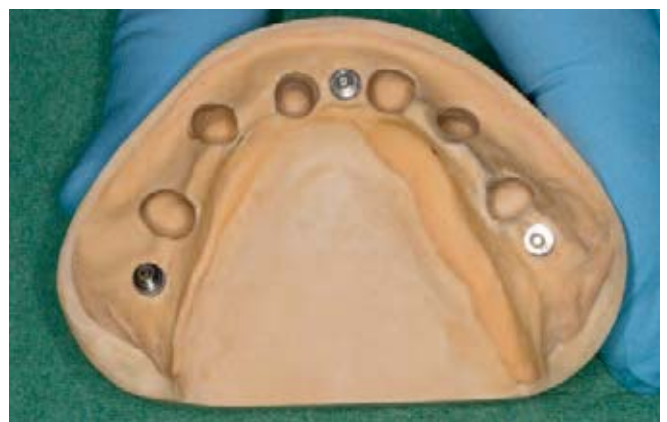

Fig. 51 Holes drilled to accommodate the implant analogs.

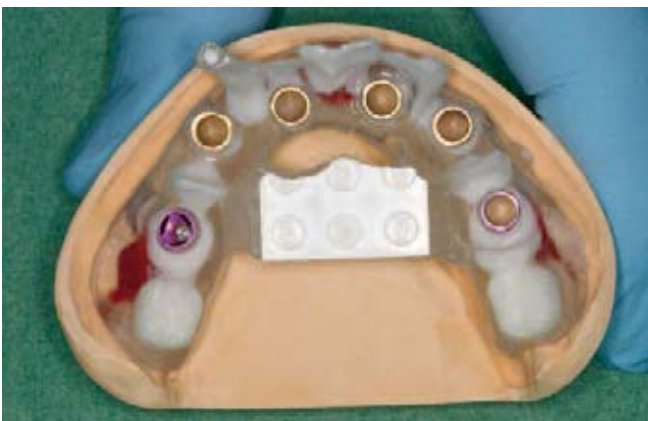

Fig. 52 Verifying the drill-hole size.

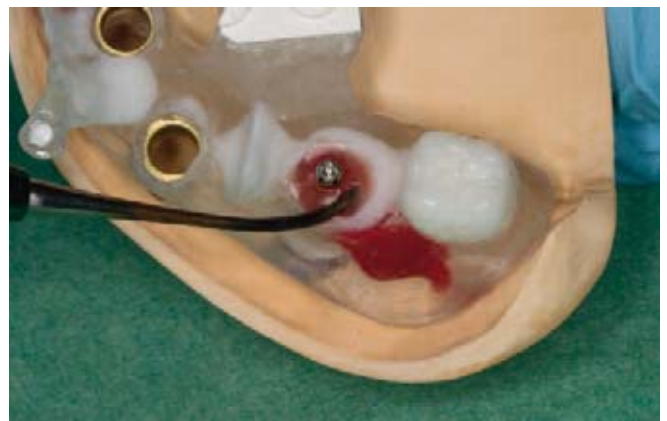


Fig. 53 Fixation of the insertion head with sticky wax (site 35).

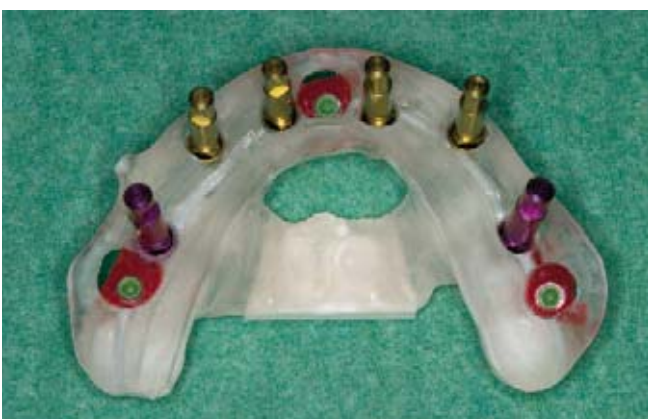

Fig. 54  
Basal view of template with  
all implant analogs.

retained implant analogs were guided through the sleeves of the stent and checked for their passive fit (Fig. 52). Sticky wax fixed the mounts in the desired cam position (flat side = cam position; Fig. 53). The accuracy of the stent was verified once again prior to incorporating the implant analogs into the cast (Fig. 54).

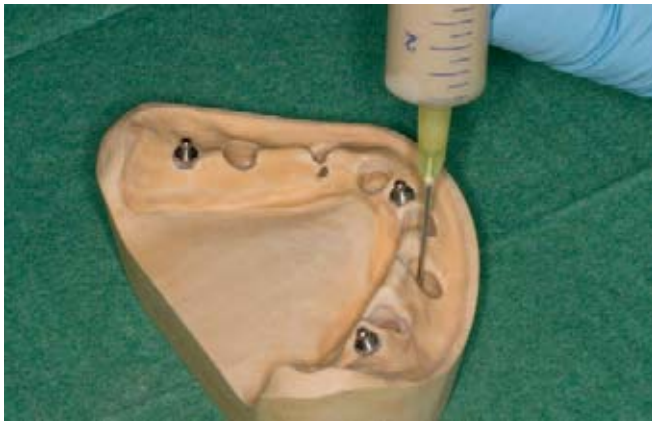

Fig. 55 A syringe is used to introduce the adhesive into the drill holes (do not overfill).

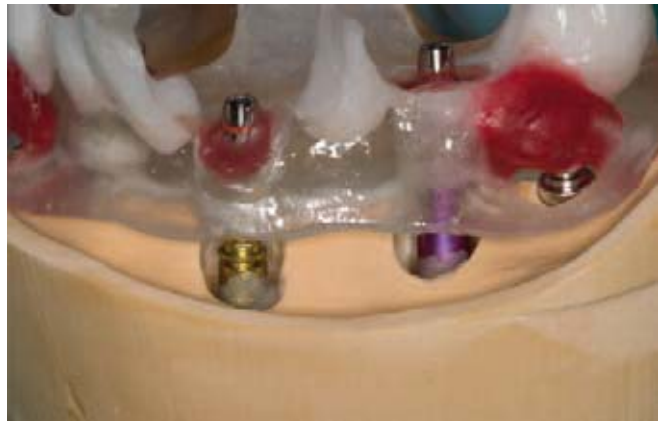

Fig. 56 Template placed on the implant analogs bonded to the master cast. Note the clearance around each implant analog.

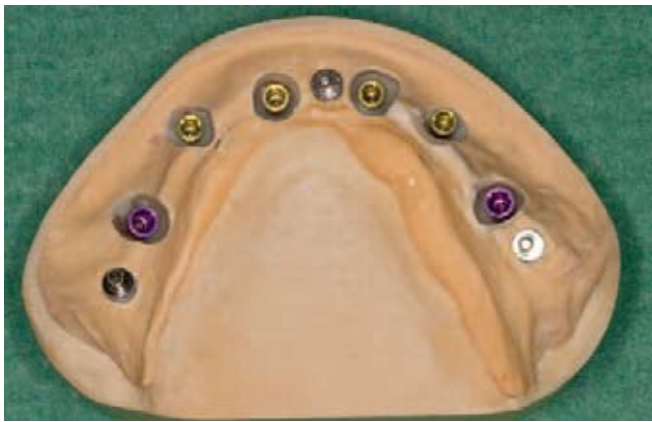

Fig. 57 Master cast with the bonded implant analogs.

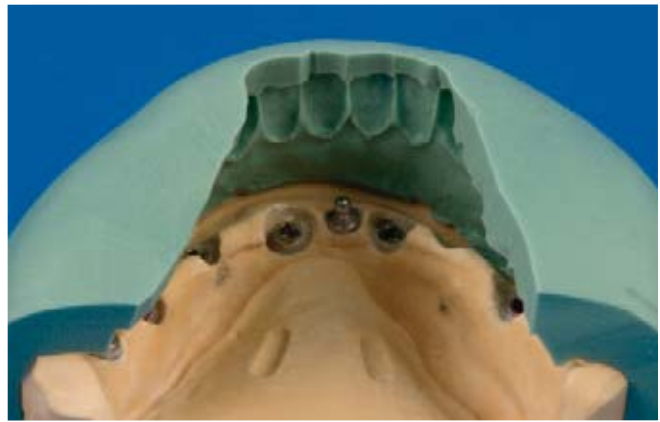


Fig. 58 Vestibular silicone bite rim. The space available for the prosthetic structure is clearly visible.

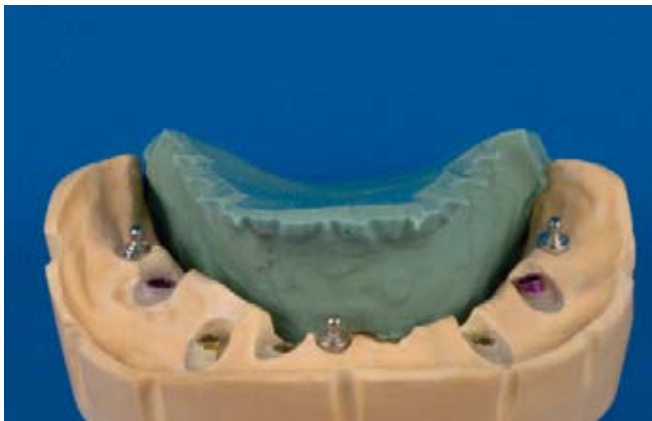


Fig. 59 Lingual silicone bite rim.

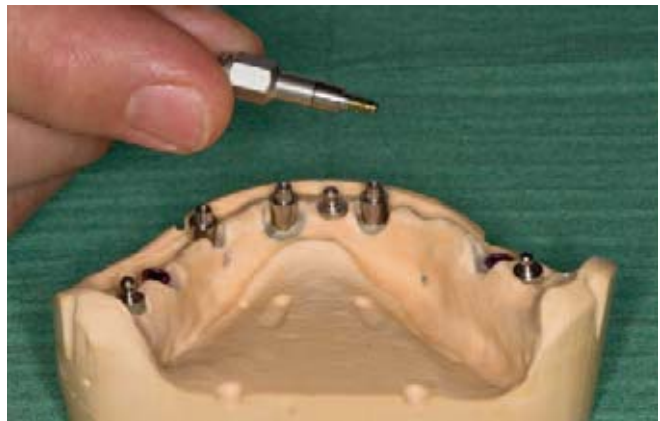

Fig. 60 Master cast with screwed-in bar abutments.

The holes in the master cast must be drilled so that the implant analogs can all be inserted simultaneously. If necessary the holes can be enlarged to allow for this. After filling the holes in the cast with resin, the stent was placed on the cast so the housings clicked into place (Figs. 55 and 56). In this way, the precise vertical positioning and axial orientation for the implants were precisely transferred to the cast. The luting of the implant analogs followed the same

principles as for intraoral impressions and had to be performed very carefully. Once the stent had been removed, the remaining adhesive gaps were filled (Fig. 57). The vestibular/lingual putty matrices indicated the space requirements for the prosthesis (Figs. 58 and 59). Based on the gingival/vertical clearance to be expected, appropriate bars for the passive-fit technique were screwed to place (Fig. 60).

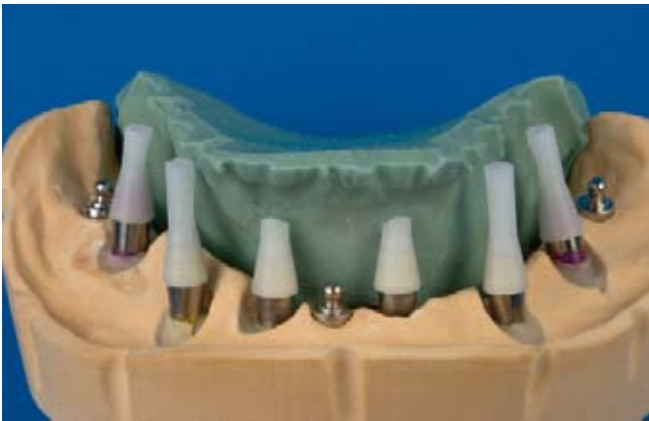

Fig. 61 Reduced bar sleeves. The lingual bite rim is placed for verification.



Fig. 62 Elements of a Camlog bar abutment. Bottom to top: implant analog, screwed-in bar abutment, bonding base, castable bar sleeve, prosthetic screw.

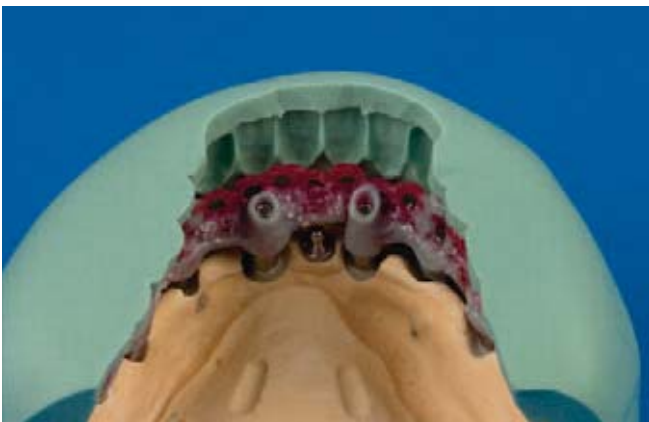

Fig. 63 Finished wax-up of the metal base. Verification with a vestibular bite rim.

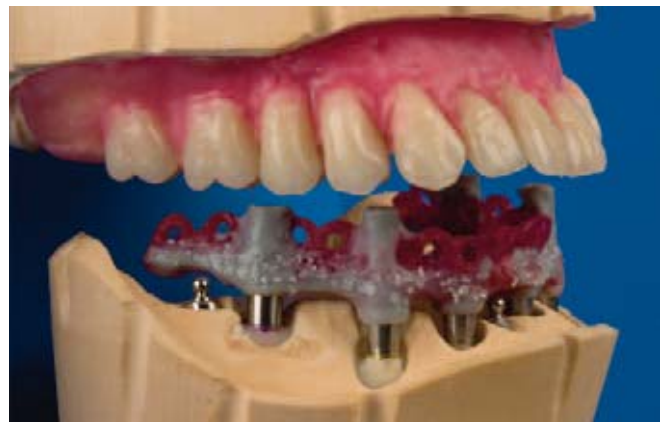

Fig. 64 Finished wax-up of the metal base. Verification on the articulator.

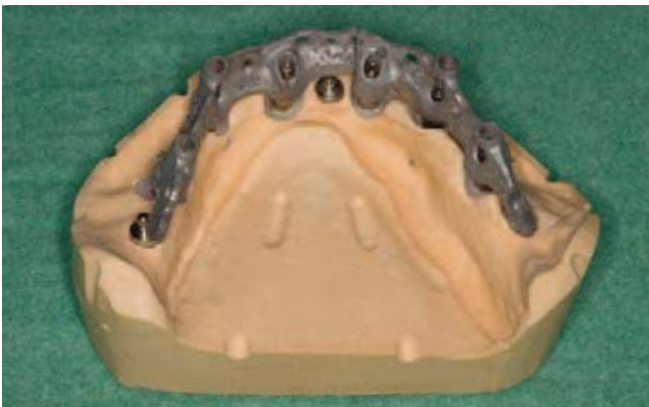

Fig. 65 Cast titanium frame fitted to the master cast.

As described above, this technique is used for stressfree postoperative delivery of the restoration. The way of achieving this will be discussed later, in connection with the delivery phase. The putty matrix was used to verify the space requirements during fabrication of the prosthesis. Care must always be taken to ensure that both the abutments and the metal base are located within the body of the rehabilitation and that sufficient space remains for the

teeth and resin base. In accordance with the processing instructions, the bonding bases and castable bar sleeves were placed on the implant analogs and mounted with the prosthetic screw. Using the lingual bite rim, the sleeves were adjusted to optimal length. This differs from when these components are used on a bar abutment, because in this procedure it means keeping the maximum length of the sleeve, extending up to the occlusal plane or, in the anterior segment, just behind the teeth. In doing so, the lingual bevel needs to be taken into consideration (Figs. 61 and 62). Subsequently, the framework was waxed up, including retention elements for the denture teeth but not the gingival portion. As a special feature, lingual windows were cut into the bar sleeves. These were necessary to enable removal of any excess material from the prosthetic screws after intraoral bonding. The same could not be achieved from the occlusal plane, given the long chimney. After a final verification with bite rims and in the articulator, the base was cast in titanium (Figs. 63 to 65).

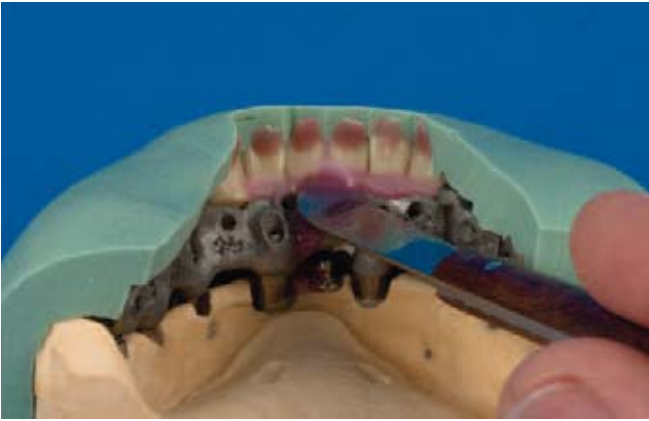


Fig. 66 The vestibular bite rim is used to adopt the aesthetic set-up.

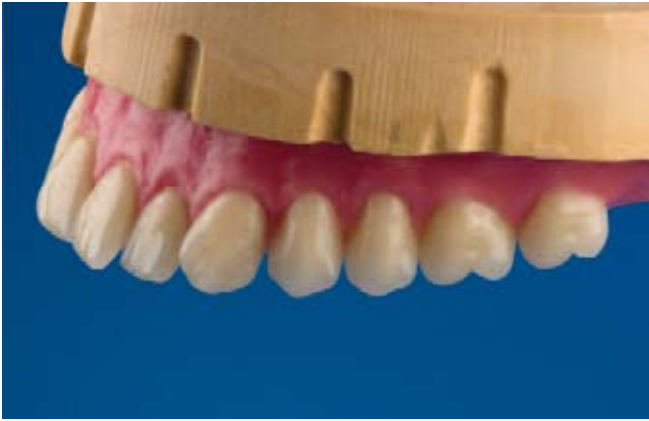

Fig. 67 Wax-up of the maxillary denture.

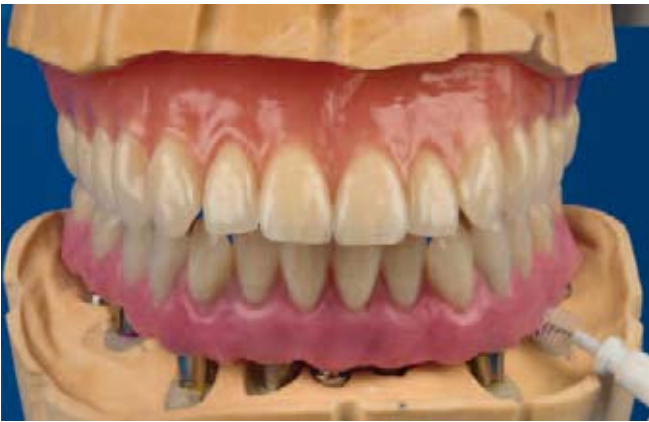

Fig. 68 Final verification of the mandibular rehabilitation wax-up.

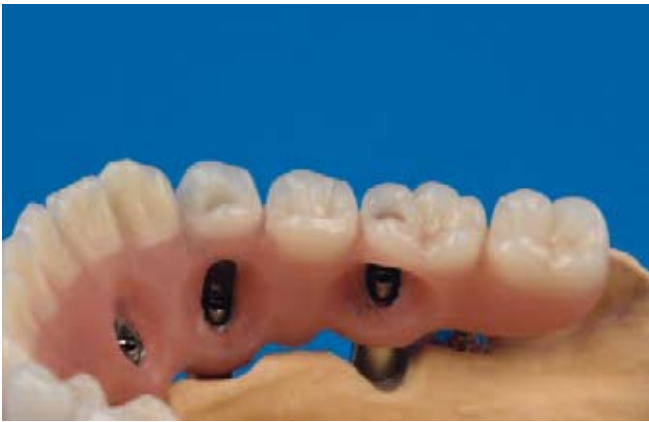

Fig. 69 Lingual fenestration of the bar sleeves for screw verification.

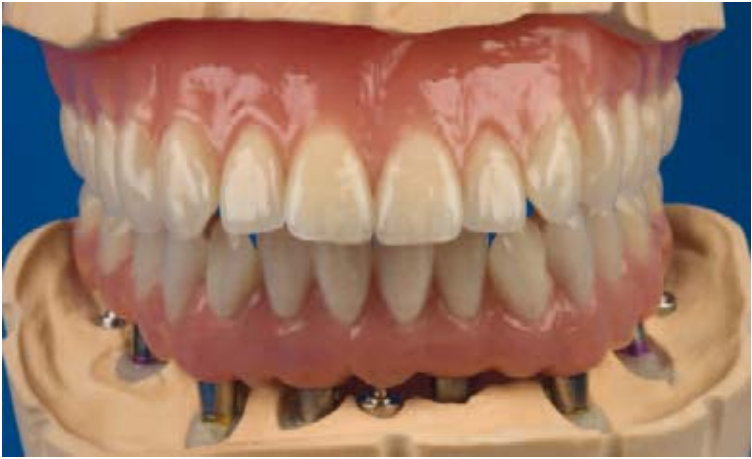

Fig. 70  
Finished maxillary  
and mandibular  
appliances in the  
articulator.

The framework was then trimmed and fitted passively to the model. To transfer the tooth positions from the wax-up, a small amount of sticky wax was used to secure the teeth in the putty matrix, which was then placed on the master cast and filled with wax (Fig. 66). This is a simple and quick way of adopting the set-up from the aesthetic try-in. After completing the wax-up of the maxillary denture (Fig. 67), the occlusion relative to the mandibular wax-up was checked and refined. The gingival portion of the

mandibular rehabilitation must offer access for a brush to cleanse underneath (Fig. 68). The wax-up was then processed into resin. The windows offering access to the prosthetic screws can be clearly seen (Fig. 69). They can be closed intraorally using a cold-curing resin at a later time. Fabrication of the restorations was now complete (Fig. 70).





Fig. 71 Implant driver, implant mount, Screw Line implant, pilot drill and shaping drills of incremental length (9, 11 and 13 mm).

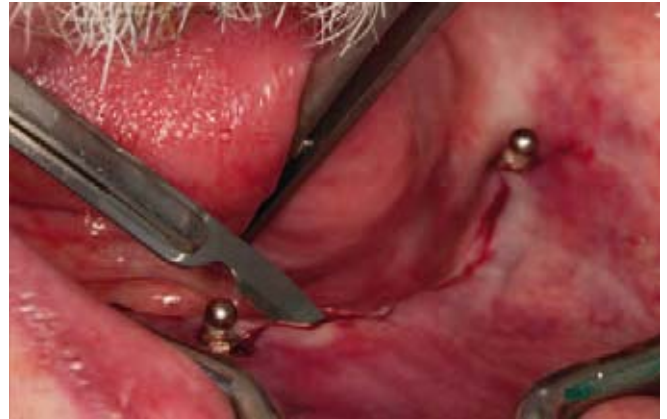

Fig. 72 Crestal incision to elevate a split-thickness flap.

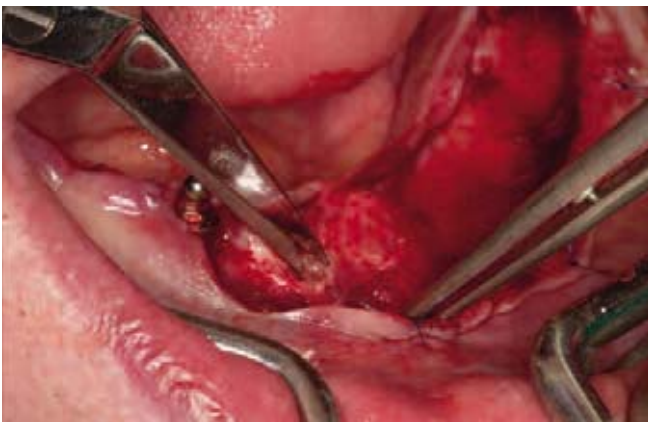

Fig. 73 Partial removal of vestibular muscles.

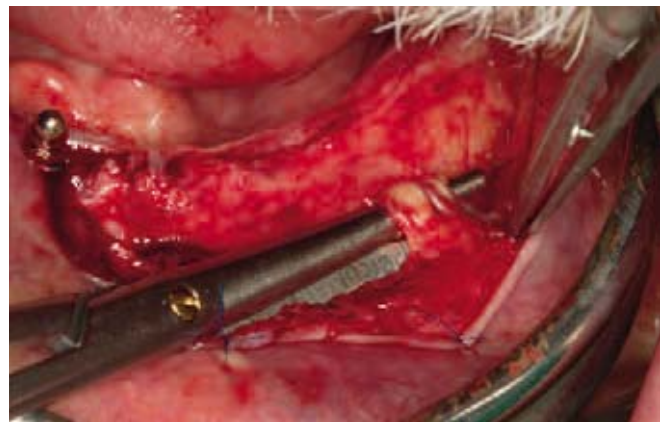


Fig. 74 Surgical exposure of inferior alveolar nerve (left side).

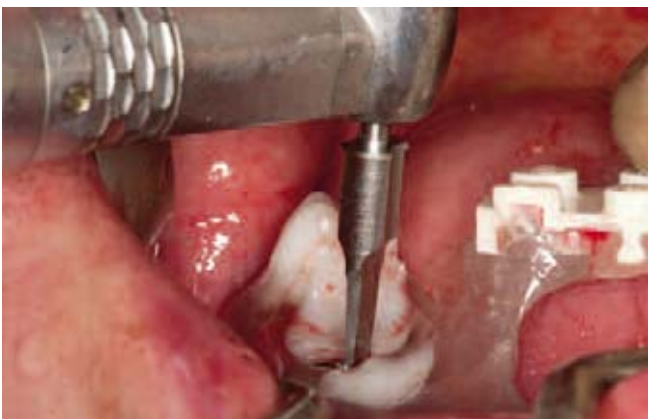

Fig. 75 The shaping drill is inserted into the sleeve.

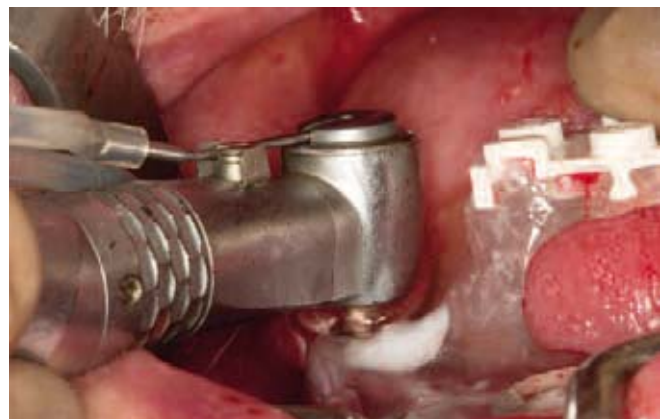

Fig. 76 Shaping drill advanced all the way into the sleeve.

The implants were placed using local anaesthesia (Fig. 71). Following elevation of a crestal split-thickness flap, the vestibular muscles were reduced to create a stable vestibular region (Figs. 72 and 73). To be on the safe side, the left inferior alveolar nerve was exposed and distracted labially prior to implant placement (Fig. 74). Care had to be taken that the housings clicked in place on the ball attachments as the surgical stent was inserted. An appropriate instrument (e.g. a probe, twist drill or round bur) was

used to mark the implant position through the template. After that, the periosteum was removed with a trephine matched to the planned implant diameter (the surgical stent was removed for this step). After the stent was replaced, drills were placed and passed down through the sleeves until the required diameter and length were reached. Deeper channels required switching to incrementally longer drills which were lowered until the depth stop was reached (Figs. 75 and 76).

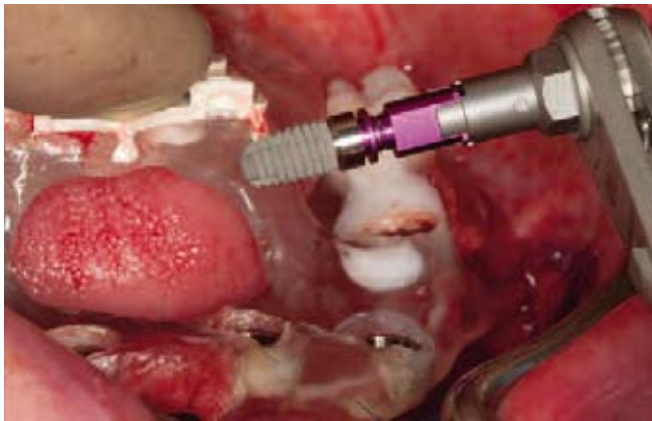

Fig. 77 Camlog Screw Line implant with a Camlog Guide implant mount placed into an implant driver and a torque ratchet.

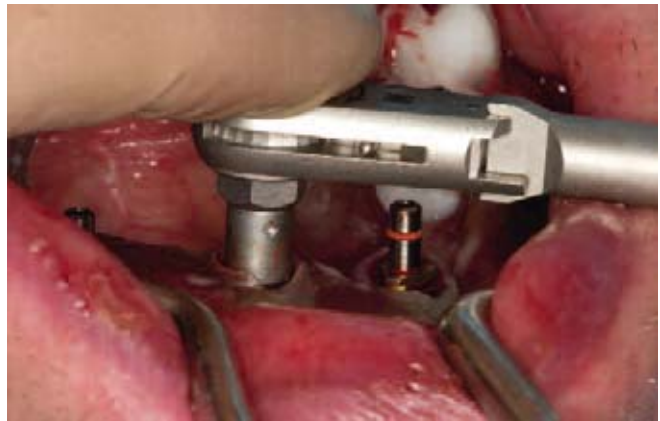

Fig. 78 Fully inserted implant.

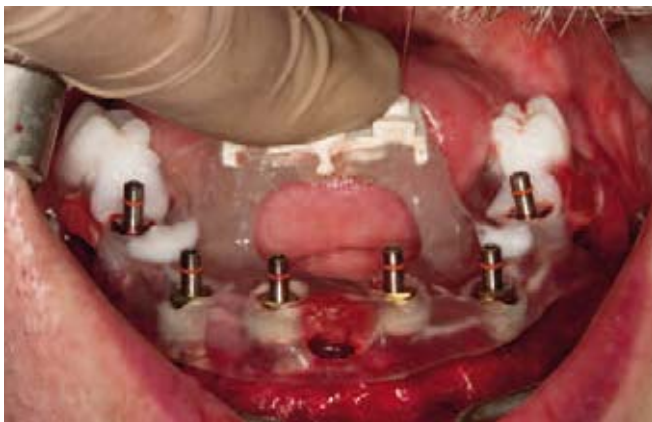

Fig. 79 Overview of implants placed.

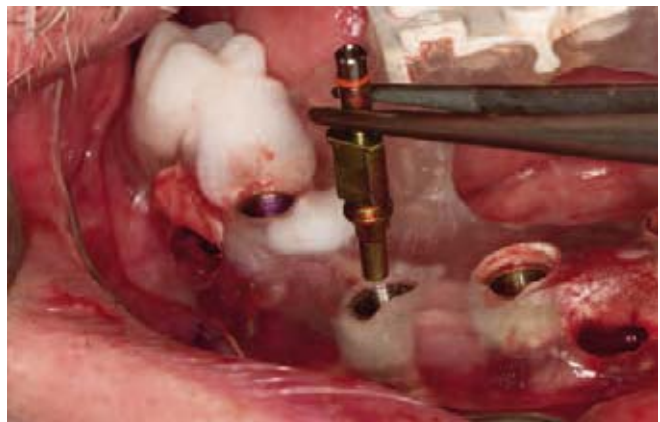


Fig. 80 Removing the released implant mount.

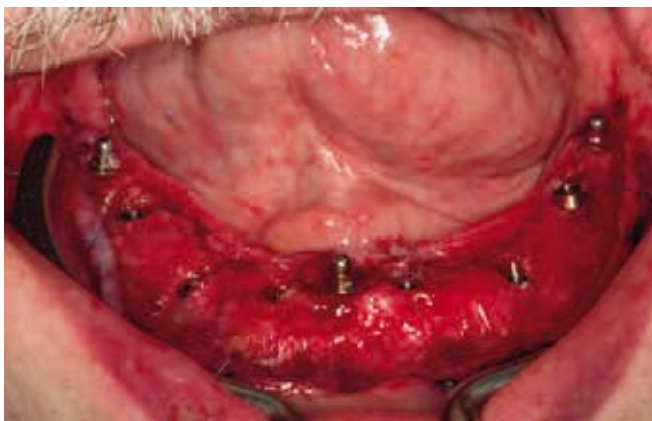

Fig. 81 Intraoral overview after implant placement and template removal.

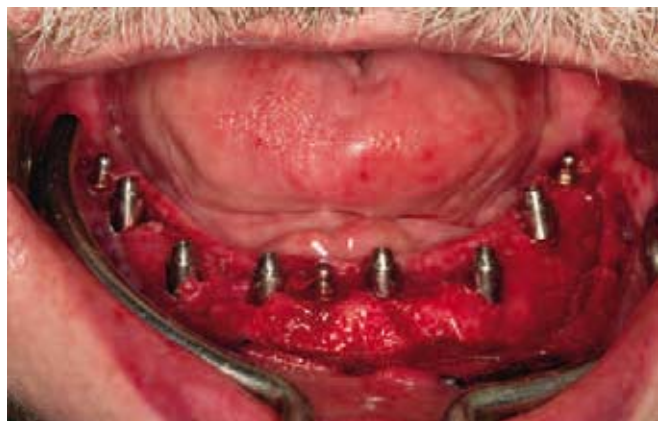

Fig. 82 Bar abutments screwed in place.

The Screw Line implants for the Camlog Guide system come with a special implant mount that matches the sleeve diameter. The different diameters are colour coded (Fig. 77). The implant mount also features a depth stop at its upper edge, which will come to rest against the edge of the sleeve once the planned insertion depth is reached. An implant driver in a torque ratchet was used to tighten the implant (Fig. 78).

The primary stability of the implant was checked against the force required for insertion. When all implants had been placed and the retaining screws released, each implant mount and the surgical stent were removed (Figs. 79 to 81). The insides of the implants were cleaned and covered with an anti-bacterial gel. After screwing the bar abutments refined by the laboratory to the implants, the wounds were sutured closed. This completed the implant procedure (Fig. 82). To verify the fit of the

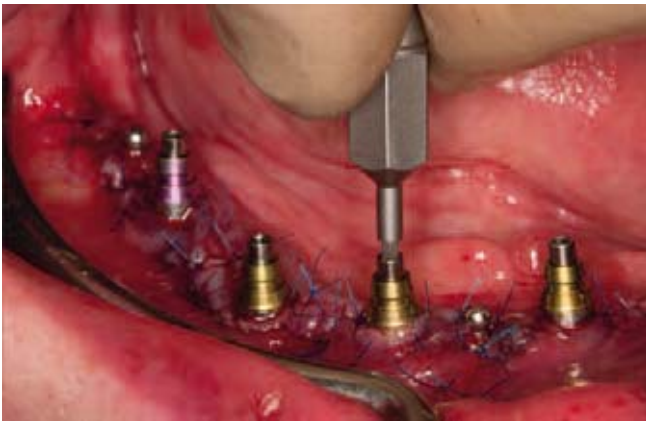


Fig. 83 Tightening the prosthetic screws on the bonding bases and suturing.

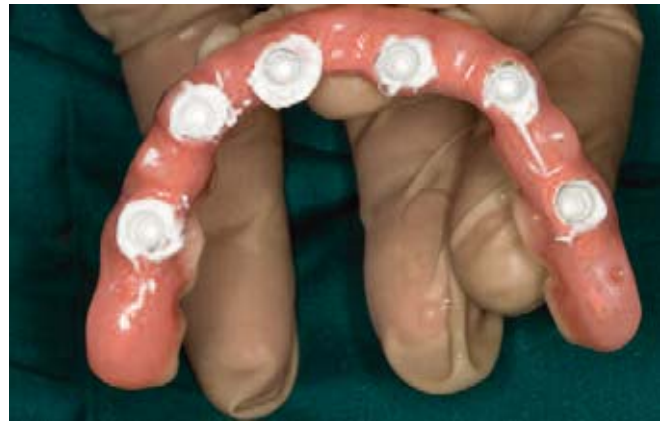

Fig. 84 Basal view of the bar sleeves after verification with Fit Checker.

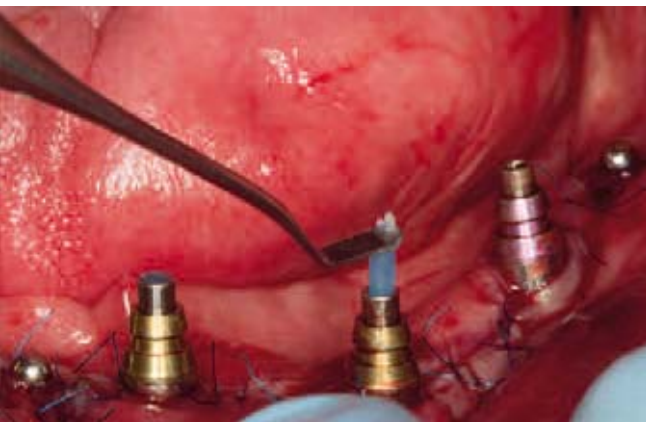

Fig. 85 Closing the Allen screw heads with wax.

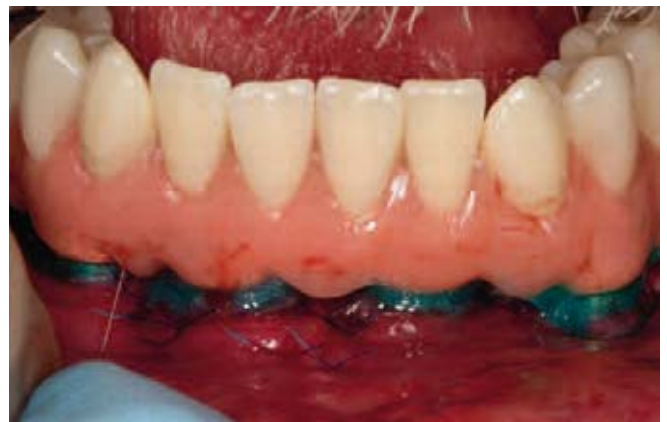

Fig. 86 The mandibular rehabilitation inserted for bonding. The bonding sites are covered with oxygen blockers.

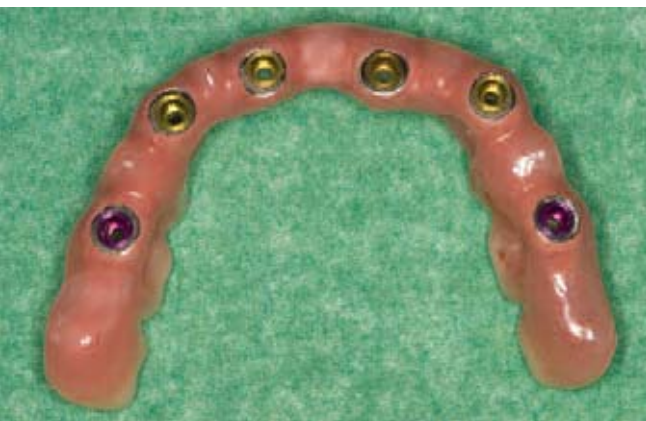

Fig. 87 Basal view of the denture following bonding of the bonding bases.

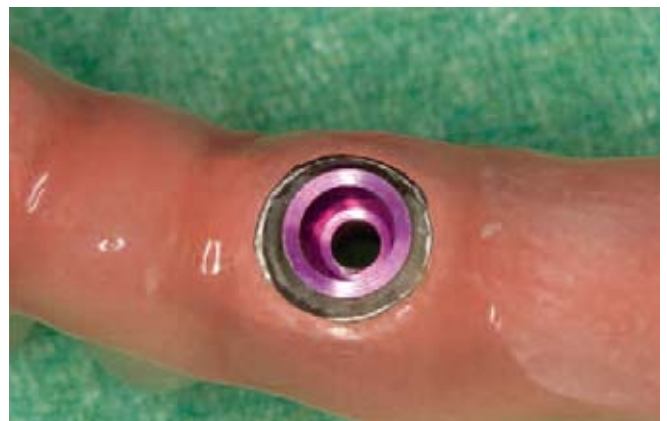


Fig. 88 Detail of an adhesive base.

rehabilitation prior to cementation, the bonding bases were mounted to the bar abutment with the prosthetic screws (Fig. 83). The basal portions of the sleeves were filled with Fit Checker (Fig. 84), and the rehabilitation was then placed over the bar abutments. In this way, any positional discrepancies that would prevent bonding of the bonding bases were identified. Prior to definitive bonding, the screw heads were filled with wax for protection (Fig. 85). Adhesive was applied sparingly to the basal seg-

ments of the metal base, and all excess material was immediately removed through the lingual windows of the bar sleeves. An oxygen blocker was used for polymerization (Fig. 86). Once the adhesive had hardened, the prosthetic screws were released through the bar sleeve chimneys and the rehabilitation was removed (Fig. 87). The adhesive gaps offer a certain space to compensate for any small discrepancies between the proposed and actual implant positions (Fig. 88).

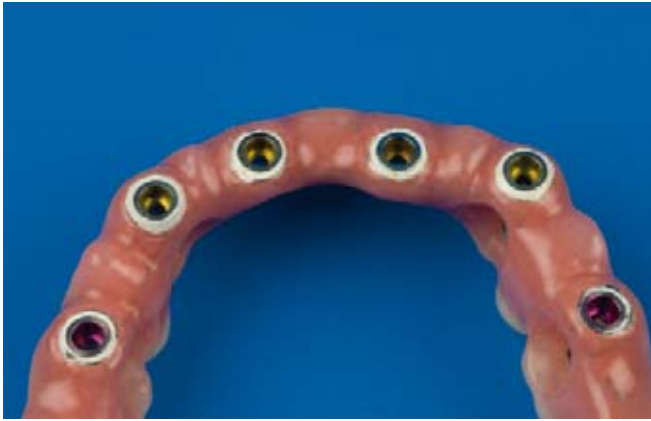

Fig. 89 Basal view of rehabilitation after adhesive correction and polishing.

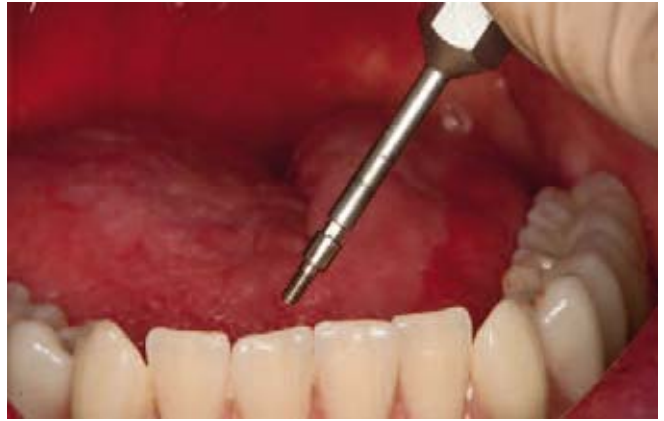

Fig. 90 The finished mandibular rehabilitation is screwed in place.

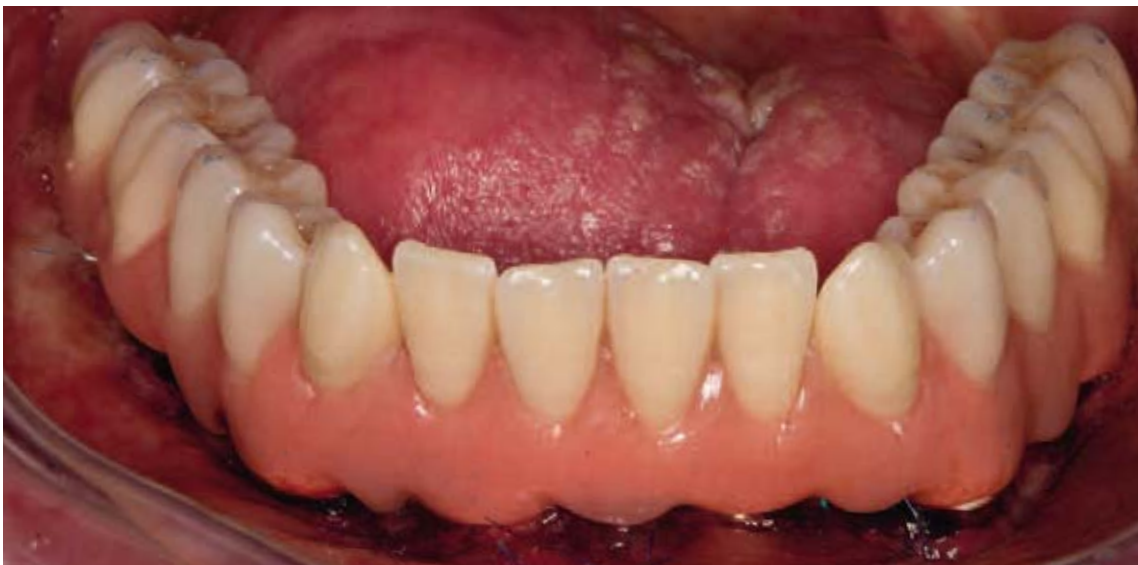

Fig. 91 Frontal view of the mandibular rehabilitation.

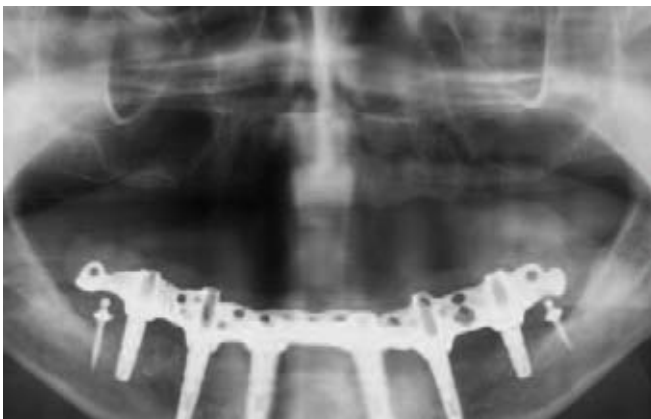


Fig. 92 Verification radiograph.

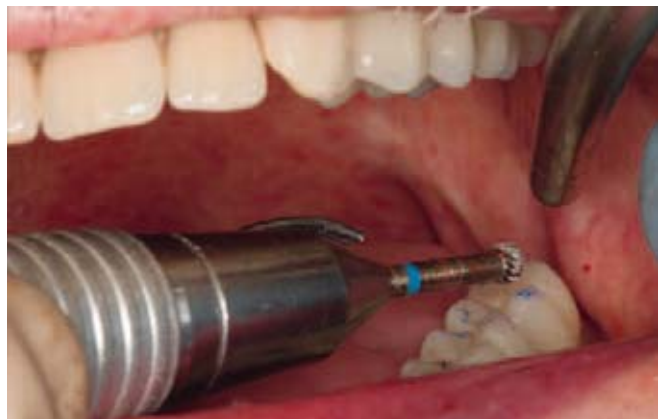

Fig. 93 Adjustment of occlusion/articulation.

This is the way that a passive fit of the rehabilitation can be ensured. In the laboratory, an adhesive was used to close any residual gaps remaining between the bonding base and the metal base. The rehabilitation was cleaned and polished (Fig. 89), then positioned in the patient and screwed to place (Figs. 90 and 91). Occlusal relationships were checked and adjusted as needed. A radiograph was obtained

for verification (Figs. 92 and 93). Approximately seven days later, the sutures were removed (Figs. 94 and 95). A follow-up examination one month later revealed healing to be excellent (Figs. 96 and 97). The patient was informed of maintenance requirements, especially with regard to cleansing underneath the rehabilitation. He has been followed up at short recall intervals with no adverse events.

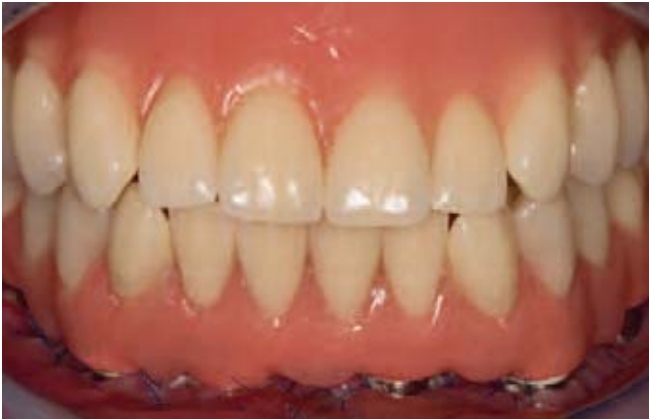

Fig. 94 Retracted view in intercuspation following suture removal (one week).




Fig. 95 Facial portrait view of the patient (one week).

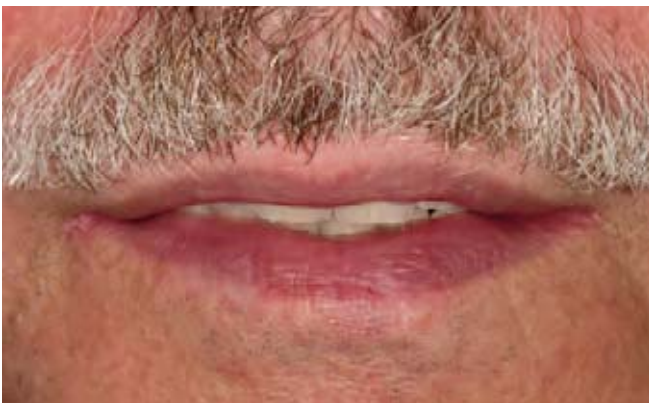

Fig. 96 Perioral view (one month).

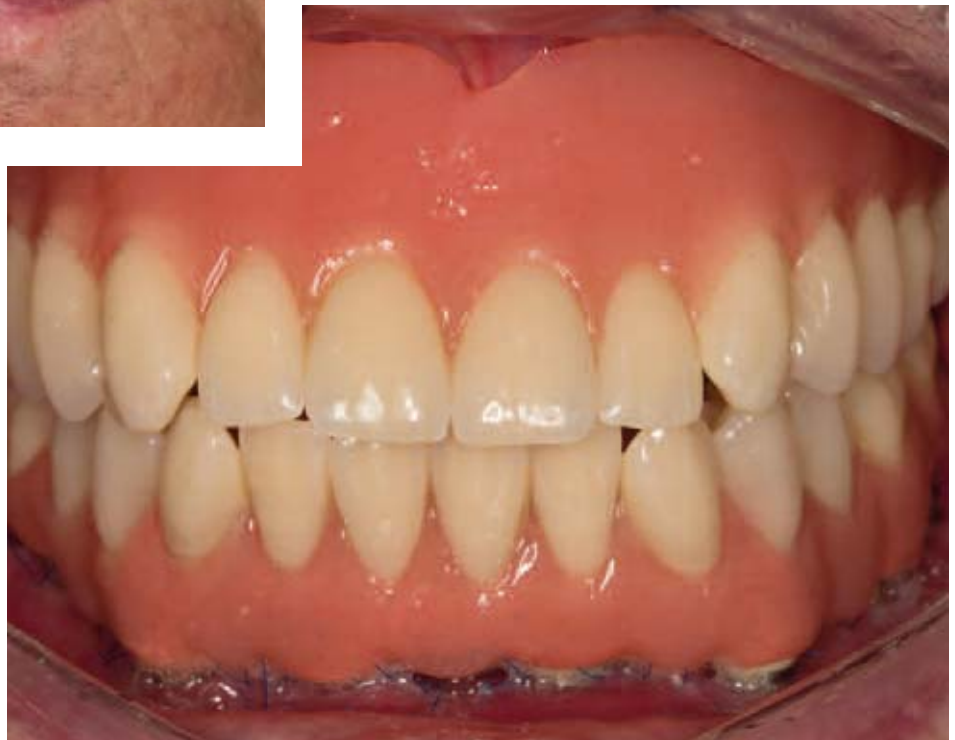

Fig. 97 Retracted view in intercuspation (one month).

Patients prefer to avoid periods without teeth or chewing function, and the approach outlined in this paper succeeds in meeting this expectation. The Camlog Guide system, used with a backward planning strategy, allows implant-supported restorations to be delivered immediately following implant placement. Requirements for success include accurate CT-based planning and exact

transfer of the planned details to clinical and laboratory procedures.

Preliminary studies have been conducted to evaluate the precision of this technique by superimposing preoperative and postoperative CT scans. These studies have yielded mean values of 0.35 mm for translational deviation and 3.18 degrees for angular deviation. ■

## References

- Ackermann K-L, Frank E: Implantatprothetik \_ Erweiterte Befunderhebung und Diagnostik. wissen kompakt 1 (2008), Springer Medizin Verlag.
- Ackermann K-L, Kirsch A, Focke A, Mozer D, Nagel R, Neuendorff G, Schär A, Wagner B: CAMLOG Compendium 2 Prothetik, Thieme Verlagsgruppe Stuttgart (2005).
- Bahat O, Fontanesi RV, Preston J: Reconstruction of the hard and soft tissues for optimal placement of osseointegrated implants. *Int J Periodontics Restorative Dent.* 1993; 13(3):255-75.
- Chee WW, Donovan TE: Treatment planning and soft tissue management for optimal implant aesthetics. *Ann Acad Med Singapore.* 1995 Jan; 24(1):113-7.
- Cordaro L, Torsello F, Ercoli C, Gallucci G: Transition from failing dentition to a fixed implant-supported restoration: a staged approach. *Int J Periodontics Restorative Dent.* 2007 Oct; 27(5):481-7.
- Duella GV: The utilization of an interdisciplinary team approach in esthetic, implant, and restorative dentistry. *Gen Dent.* 2004 Mar-Apr; 52(2):116-9.
- Edinger D, Kahler E, Hilgers R: Untersuchung der Rotationsspassgenauigkeit. *BDIZ EDI konkret* (2007) 2:68-71.
- el Askary A el-S: Esthetic considerations in anterior single-tooth replacement. *Implant Dent.* 1999; 8(1):61-7.
- Elian N, Ehrlich B, Jalbout ZN, Classi AJ, Cho SC, Kamer AR, Froum S, Tarnow DP: Advanced concepts in implant dentistry: creating the "aesthetic site foundation". *Dent Clin North Am.* 2007 Apr; 51(2):547-63, xi-xii.
- Garber DA, Belser UC: Restoration-driven implant placement with restoration-generated site development. *Compend Contin Educ Dent.* 1995 Aug; 16(8):796, 798-802, 804.
- Hahn JA: Surgical and prosthetic concepts for optimal aesthetics: a case report. *Int J Dent Symp.* 1995; 3(1):44-7.
- Kirsch A, Neuendorff G, Ackermann K-L, Nagel R, Dürr W: Die Camlog-Verbindung. Voraussetzung für ein zuverlässiges implantatprothetisches Behandlungskonzept der Zahn-für-Zahn-Restauration. *Quintessenz* 50, 1-18 (1999).
- Kirsch A, Dürr W, Neuendorff G, Ackermann K-L, Nagel R: Das Camlog-Implantatsystem. *Interdisziplin J Proth Zahnheilk* 2, 352-360 (1999).
- Kirsch A, Ackermann K-L, Neuendorff G, Nagel R: Neue Wege in der Implantatprothetik. *Interdisziplin J Proth Zahnheilk* 2 (1999).
- Kirsch A, Ackermann K-L, Nagel R, Neuendorff G, Focke A, Mozer D, Schär A, Wagner B: CAMLOG Compendium 1 Chirurgie, Thieme Verlagsgruppe Stuttgart (2007).
- Lee EA, Jun SK: Achieving aesthetic excellence through an outcome-based restorative treatment rationale. *Pract Periodontics Aesthet Dent.* 2000 Sep; 12(7):641-8; quiz 650.
- Lee EA, Jun SK: Aesthetic design preservation in multidisciplinary therapy: philosophy and clinical execution. *Pract Proced Aesthet Dent.* 2002 Sep; 14(7):561-9; quiz 570.
- Lee EA, Jun SK: Management of complex implant aesthetics: ensuring restorative design continuity with a comprehensive outcome-based strategy. *Pract Proced Aesthet Dent.* 2001 Sep; 13(7):515-23; quiz 524.
- Nagel R, Ackermann KL, Kirsch A: Sofortimplantation und Sofortbelastung. Das Einzelzahn-Sofortimplantat mit provisorischer Versorgung. *ZMK Magazin für Zahnheilkunde* 2001; 17(1-2):20-23
- Nishimura RD, Beumer J 3rd, Perri GR, Davodi A: Implants in the partially edentulous patient: restorative considerations. *Oral Health.* 1998 Oct; 88(10):19-20, 23-4, 27-8.
- Reinert M, Geis-Gerstorfer J: Vergleichende Untersuchung zur Passgenauigkeit von prothetisch-zahn-technischen Komponenten verschiedener Implantatsysteme. *Deutsche Zahnärztliche Zeitschrift* (2007) 62:668-674.
- Rose LF, Salama H, Bahat O, Minsk L: Treatment planning and site development for the implant-assisted periodontal reconstruction. *Compend Contin Educ Dent.* 1995 Aug; 16(8):726, 728, 730 passim; quiz 742.
- Saadoun AP, Le Gall MG, Touati B: Current trends in implantology: part II-treatment planning, aesthetic considerations, and tissue regeneration. *Pract Proced Aesthet Dent.* 2004 Nov-Dec; 16(10):707-14; quiz 716.
- Salama H, Garber DA, Salama MA, Adar P, Rosenberg ES: Fifty years of interdisciplinary site development: lessons and guidelines from periodontal prosthesis. *J Esthet Dent.* 1998; 10(3):149-56.
- Tischler M: Dental implants in the esthetic zone. Considerations for form and function. *N Y State Dent J.* 2004 Mar; 70(3):22-6.
- Vlasis JM, Lyzak WA, Senn C: Anterior aesthetic considerations for the placement and restoration of nonsubmerged endosseous implants. *Pract Periodontics Aesthet Dent.* 1993 Dec; 5(9):19-27; quiz 29.
- Yanase RT: Prosthodontic treatment planning: current practice, principles, and techniques. *J Calif Dent Assoc.* 2003 Apr; 31(4):311-4.

## Contact Address

**IMZ Arbeitsgemeinschaft**  
Talstraße 23  
70794 Filderstadt  
GERMANY  
Phone: +49 711 70881-55  
r.nagel@kirschackermann.com



Dr Axel Kirsch



Dentist Rainer  
Nagel



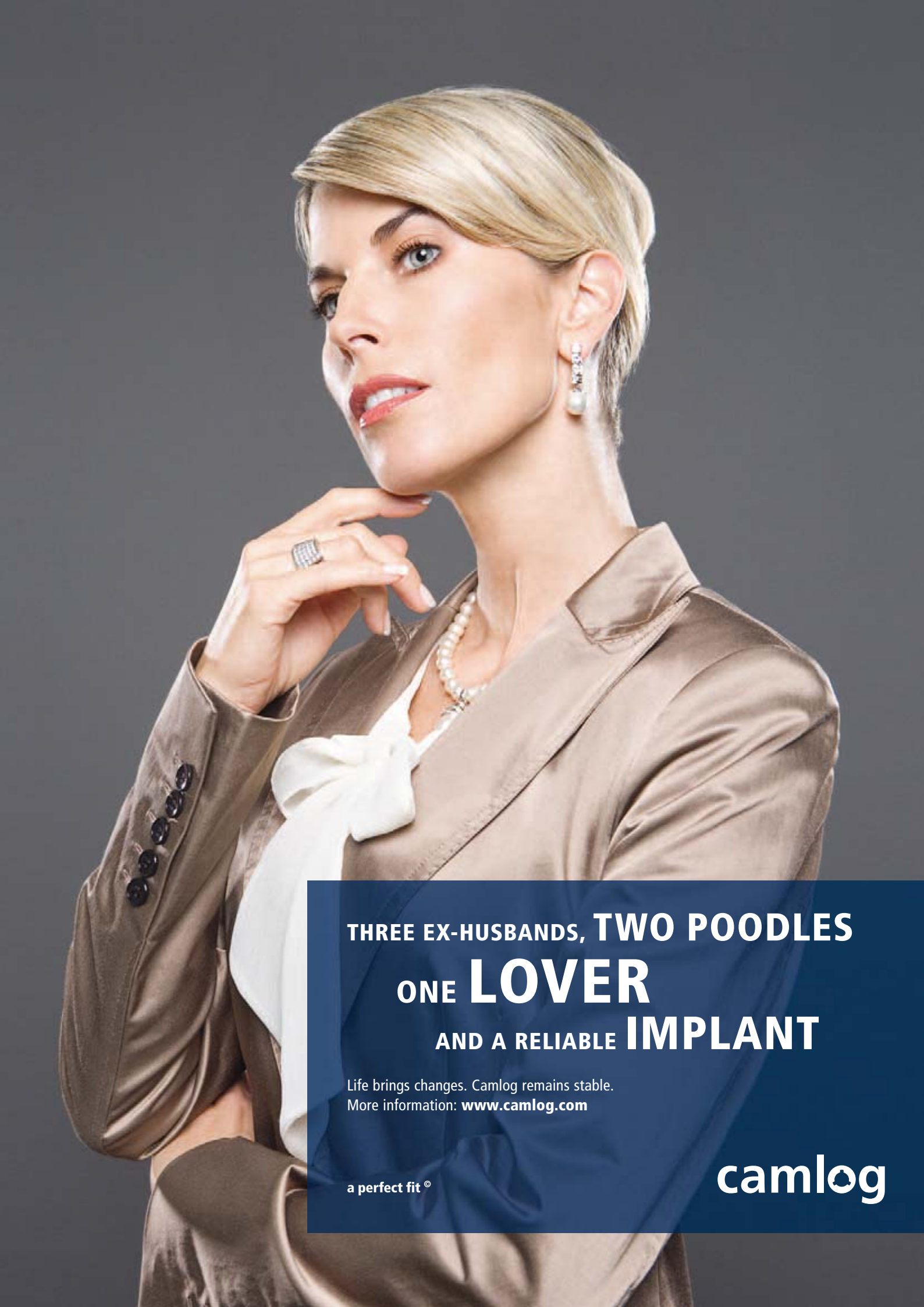Dr Karl-Ludwig  
Ackermann



MDT Gerhard  
Neuendorff

Notes

A large, empty light gray rectangular area intended for taking notes, occupying the majority of the page below the 'Notes' header.



THREE EX-HUSBANDS, TWO POODLES  
ONE **LOVER**  
AND A RELIABLE **IMPLANT**

Life brings changes. Camlog remains stable.  
More information: [www.camlog.com](http://www.camlog.com)

a perfect fit<sup>®</sup>

**camlog**