

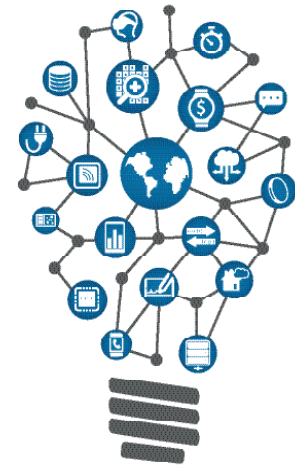
July 2018  
The CAMLOG Partner Magazine



**INNOVATIVE AND INSPIRING  
THE OR GLOBAL SYMPOSIUM**

**18**

# DIGITIZATION BRINGS US CLOSER TO OUR CUSTOMERS.



## Dear readers

Digitization in the world of dentistry is picking up speed. Many other industries are already far ahead and are predominantly working in digital processes, now the dental industry and implant dentistry are catching up. CAMLOG is very well positioned here; our products are increasingly being used in digital workflows. In 2018, for example, more CAMLOG implants in Germany have already been restored using digital workflows via a titanium base or individualized prosthetics than with conventional standard prosthetics.

This development is being driven forward by patients, dentists and laboratories alike. In addition to the desire for higher productivity, the demand for esthetic individual restorations is constantly increasing. However, this demand can no longer be met without the possibilities of digitization and has also been instrumental in moving CAMLOG into a new direction.

In the future, the focus will be on the various services involving the entire implant restoration for implant planning, scanning, design and the complete case-related delivery of all necessary analog and digital components.

However, the services are not made possible by individual institutions, but only by networks of dentists, laboratories and industrial partners. The networks are now becoming more flexible and allow participants any number of entries and exits in the future.

However, we are also responsible for mastering the increasing complexity of all workflows in the networks. Challenges such as large data volumes, different data formats and different in- and outsourcing possibilities will become more and more manageable through platforms in the future, without the users having to deal with this complexity.

The change in dentistry is in full swing, but the most important element for CAMLOG remains you as our users and your patients, even in times of digitization. We will accompany you during these challenges and build your individual digital network for you, just as you wish. This automatically brings us closer to our customers and enables all CAMLOG users to move into digitization.








As a manufacturer of implants, we have the opportunity to invest in innovative platforms and thus also to develop workflows that enable new forms of cooperation for the networks.

I have been involved in IT for more than 30 years, and there have always been trends and developments, whereby every user had to decide for himself which development he wanted to participate in.

But the speed of change is faster than ever, according to the futurologists Brynjolfsson and McAfee\* we have been on the famous second half of the chessboard since 2006. With each new field, the performance of digital systems doubles according to Moore's law and enables techniques that were not feasible 18 months ago. The considerable social effects of this development are still largely ignored today and will still present us with great challenges over the coming decades.

Markus Stammen  
Director CAD/CAM and IT

# CONTENT

	<b>COVER STORY</b>	
	• Knowledge transfer in royal surroundings – 1,200 enthusiastic participants at the OR Global Symposium in Rotterdam	4
	<b>SCIENCE / CLINICAL RESEARCH</b>	
	• Research Award and Poster Competition	10
	<b>CASE STUDY</b>	
	• CERALOG® Implants – the solution for special patient needs	12
	• Restoration of an edentulous maxilla – combined procedure with facial sinus lift	18
	• Immediate fixed rehabilitation – the restoration of edentulous jaws with the aid of a modified practice concept	22
	<b>NEWS</b>	
	• 100 % CAMLOG campaign – why every fourth implant in Germany comes from CAMLOG	28
	• The new Medical Devices Directive – 2017/745 EEC	30
	<b>ABOUT CAMLOG</b>	
	• ALLTEC DENTAL in Austria – Interview with Alexander Jirku and Pierre Rauscher	32
	<b>PRACTICE MANAGEMENT</b>	
	• Avoiding leadership errors – communicating effectively and motivating employees	34
	<b>LIFESTYLE</b>	
	• Hello future, we're coming!	38

**logo** – the CAMLOG Partner Magazine • **Publication dates:** twice per year • **Publisher:** CAMLOG Vertriebs GmbH • Maybachstr. 5 • D-71299 Wimsheim  
 Telephone: +49 7044 9445-100 • Telefax: +49 800 9445-000 • [www.camlog.com](http://www.camlog.com), **Editorial staff:** Oliver Ehehalt (responsible), Michael Ludwig, Anela Mehic, Françoise Peters, Andrea Stix, Ingrid Strobel • **Photos:** CAMLOG and its licensors • **Photos:** all photos are by CAMLOG except the photos on pages.2, 30, 35-37, 38-39: stock.adobe.com/de, p. 4-11: OR Foundation, p. 12-27: see list of authors • **Design:** Kerstin Gerhardt, Duc-An Do • **Print:** Wurzel Mediengruppe, Esslingen.

**Note:** Named contributions express the opinion of the author and not necessarily the opinion of the publisher. Names marked with ® are registered trademarks of their respective manufacturers.





## KNOWLEDGE TRANSFER IN ROYAL SURROUNDINGS – 1,200 ENTHUSIASTIC PARTICIPANTS AT THE OR GLOBAL SYMPOSIUM IN ROTTERDAM

The Oral Reconstruction (OR) Foundation hosted its global symposium in Rotterdam and honored King Willem-Alexander of the Netherlands by holding the meeting on his birthday – the "Koningsdag" on April 27. Rotterdam was thus enlivened by 1,200 congress visitors for three days, who flocked to the trendy Dutch metropolis from 39 countries.

The motto of the World Symposium sounded as promising as the royal setting: "The Future of the Art of Implant Dentistry". To this end, the scientific committee, chaired by Professor Irena Sailer and Dr. Ben Derksen, had put together an attractive two-day main program of current focus topics: soft tissue management, digital workflow, restorative concepts especially for elderly

patients, ceramic implants and much more. Twelve hands-on workshops plus a theoretical workshop in English, German and Spanish as well as two workshops with simultaneous translation into Chinese left nothing to be desired to deepen a topic that was of particular personal interest. The additional symposium for dental professionals included important aspects for the team. A total of 57 speakers,

moderators and experts from twelve countries offered an excellent mixture of science and everyday clinical practice with enormous practical relevance. The World Symposium also showed greatness at the accompanying industrial exhibition. 21 companies highlighted their products and solutions for oral implant and restorative dentistry.





**"Functional" gingiva**

In the first session of the main scientific program, the internationally renowned speakers Professor Mariano Sanz, Professor Anton Sculean and Dr. Edward P. Allen acknowledged the importance of healthy peri-implant soft tissue for implant success and demonstrated techniques for thickening and widening the gingiva using different grafts and tunnel/pouch techniques. A sufficiently broad band of keratinized gingiva is crucial for both implants and recession covers of natural roots. According to Edward P. Allen, this

consisted of both free and fixed gingiva and he therefore suggested speaking more accurately of "functional" gingiva.

**The best of both worlds**

How far has the digital workflow progressed and how mature is virtual impression taking in practice? This was the topic of the second session with the speakers Dr. Wiebe Derksen, Dr. Tabea Flügge and the team Dr. Peter Gehrke and DT Carsten Fischer. Both the moderator of these lectures, Professor Florian Beuer, and the speakers themselves agreed that

digitization is a "game changer" and is making rapid progress.

Even if the analog steps are still necessary to close the digital workflow, all speakers motivated the delegates to deal with the new technologies. According to Wiebe Derksen, digital planning is very efficient and team-oriented due to the matching of scanning and DVT data. He loves the design process and the exchange with the dental technician. In contrast, he considers 3D-printed models not to be very precise and surface-true and therefore relies on passivation models from the laboratory





for large-span reconstructions. This was confirmed by Tabea Flügge in her statement that the precision of digital impressions decreases with increasing span and number of implants. The scanner itself and the scanning protocol have a significant influence on the accuracy of digital impressions of implants.

Dr. Peter Gehrke and Carsten Fischer believe that ready-to-use standard parts make no sense in the digital workflow. In the past, they have also dealt very intensively with the various quality criteria of CAD-CAM-manufactured reconstructions in their own studies, such as precision and surface quality, and very often rely on the DEDICAM® manufacturing services. Despite the CAD-CAM technology, which they regard as being indispensable, manual reworking and finishing by the dental technician is always necessary in addition.

### Trend to early protocols

Professor Bilal Al-Nawas opened the session "Treatment concepts" with an analysis at the time of implantation. However, for him, an ideal implant position, sufficient primary stability

and adequate augmentation measures are more important than the time of implant placement. Wherever possible, he strives for immediate or early implant placement, as his patients benefited from shorter treatment times and less extensive soft tissue augmentation. In the case of infected alveoli or the need for GBR measures, immediate implant placement should be avoided.

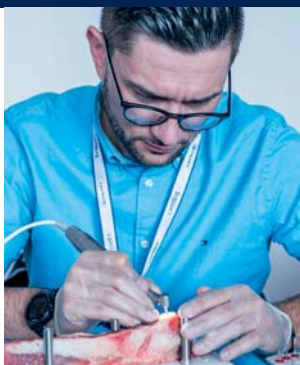
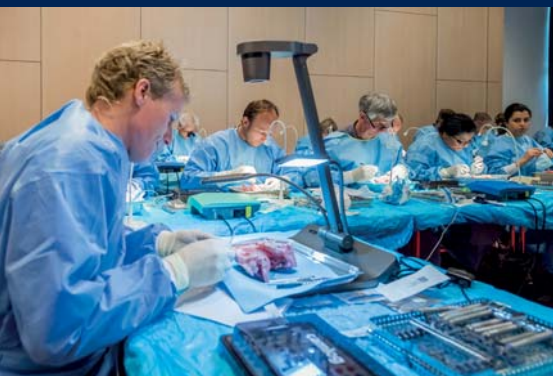The trend towards earlier loading protocols is also followed by the PROGRESSIVE-LINE implant design presented to the public in Rotterdam for the first time by Dr. Kai Zwanzig and Christian Rähle (Director of Research and Development, CAMLOG). This is very well suited for soft bone and compromised implant sites and follows a standard surgical protocol without the use of special instruments. The design of the implant body (apical conical, cranial cylindrical) and the thread (sawtooth-like) allow a wide range of indications and allow safe insertion torques in all bone classes through a multi-stage drilling protocol. The new PROGRESSIVE-LINE will be available as of IDS 2019 in a CAMLOG® version (Tube-in-Tube® connection) and subsequently in a CONELOG® version (conical connection), according to Rähle.

According to Dr. Jan Klenke, the iSy® Implant System is ideal for immediate implantation and immediate restoration concepts. Tooth extraction, implant placement, soft tissue thickening and temporary restoration using a multifunctional cap on the pre-mounted implant base can be performed very comfortably in just one session. Studies and his own experiences have proven that transmucosal healing has no negative influence on implant success. According to the "One-shift" concept, the implant is "opened" for the first time by removing the implant base for the final restoration and then appears very "clean" – an intelligent concept with advantages for biology and esthetics.

### Ceramic implants – an alternative to titanium?

PD Dr. Daniel Thoma and a research group at the University of Zurich have been working on comparative studies between titanium and zirconium dioxide implants for a long time and presented some of these studies and their results. Seen overall, osseointegration and marginal bone preservation are the same for both implant materials. With the latest generation of zirconium dioxide implants, they had observed a greater overall soft tissue volume compared to titanium implants. Furthermore, it appears that zirconium dioxide implants





are better suited to minimize bone loss and recessions in cases of dehiscence.

This resumé from the research was a great opportunity for the two subsequent speakers – Professor Vladimir Kokovic and Dr. Frank Maier – who have both already dealt intensively with the CERALOG® Implant System. In the past, Vladimir Kokovic has conducted intensive clinical research into the primary stability of CERALOG® Implants, also in order to explore the possibility of immediate loading protocols. In one of his studies he observed initial ISQ values of just over 60, a drop in Week 3 to values around 54 and an increase in Week 16 to areas around 64. He sees the possibility of immediate loading protocols in the mandibular posterior region with CERALOG®. Single-tooth reconstructions are the system's domain and the advantages are best realized in the anterior region – due to the material and its dual surface texture of 1.6 µm endosseous and 0.5 µm in the neck region for the transition zone. Vladimir Kokovic firmly believes in the future of ceramic implants and explained this by the high user-friendliness and positioning precision of the two-piece hexalobe implant. This is also preferred to the one-piece monobloc implant by Frank Maier. He considers the biological aspects of implant materials to be important (zirconium dioxide, unlike titanium, does not release ions), but at the same time

considers it appropriate to remove the stigma of alternative medicine and place ceramic implants on a broader scientific basis. For example, he does not consider ceramic drills to be a good choice, because they have poor thermal conductivity and therefore present a greater risk of heat necrosis.

Frank Maier comes from the Tübingen School and sees an indication for zirconium dioxide implants both in combination with PEKK abutments and with zirconium dioxide abutments for single teeth and smaller bridges up to a maximum of five pontics. In one female patient, he inserted a four-pontic bridge on three implants, which were restored once with PEKK abutments and once with zirconium dioxide abutments for comparison purposes. The clinician and the patient assessed both restorations as being equivalent, but the patient ultimately opted for the zirconium dioxide abutments for biological reasons.

### Restorative concepts

Due to demographic developments, the focus in the practice is increasingly on older patients. This requires concepts that take advanced age into account or, better still, "the aging process" – and therefore do not at some point pose unsolvable problems for patients with decreasing visual and manual abilities. The speakers

in this session, Dr. Luca Cordaro, Dr. Claudio Cacaci and Dr. Rémy Tanimura, agreed that it was therefore important to strategically consider which restorative concept to recommend to older people. Whereby the individual situation of the patient is the top priority. Dr. Luca Cordaro advocated several smaller bridges for total restorations, incorporating the residual dentition whenever possible.

Dr. Claudio Cacaci and co-authors already presented the Munich concept "One dental prosthesis for two life phases" about ten years ago. This is characterized by a fixed cemented restoration that can be converted into a removable telescopic restoration. The functional elements for this are 2° milled zirconium dioxide abutments on CAMLOG® Implants and electroplated abutments. Even at the time, this concept was very convincing, as well as being new. Based on 13 to 14 year old patient cases, Dr. Claudio Cacaci can today prove that this worked exactly as envisioned and could accompany people through the different stages of age. According to Claudio Cacaci, regular follow-up checks and professional dental hygiene are an indispensable part of this concept.



## Sponsored research projects

The Scientific Working Group of the OR Foundation, consisting of Professor Fernando Guerra, Professor Robert Sader, Dr. Alex Schär, Professor Thomas Taylor and Professor Wilfried Wagner, oversees the scientific research and the related use of funds.

The presentation of the results of selected research projects was also given due consideration in the main program of the symposium. The research projects dealt with the following topics: 3D accuracy of the implant position during template-guided implant insertion (Dr. Sigmar Schnutenhaus), maxillary overdentures supported on two implants (Dr. Florian Kernen), dental implants in aggressive periodontitis (Assoc. Professor Pinar Meric), microscopic investigations of peri-implant soft tissue cell adhesion on different abutment materials (Assoc. Professor Hanae Saito), effectiveness of home care and professional procedures for biofilm removal on different materials and surfaces (Dr. Gordon John).

## Oral Reconstruction Foundation Research Awards

In addition, Professor Jürgen Becker and Professor Fernando Guerra awarded the three OR Foundation Research Prizes, which were endowed with € 10,000, € 6,000 and € 4,000 respectively.

The poster exhibition also attracted great attention and included 50 peer-reviewed posters from nine countries. The Poster Award of € 2,000 each was presented in the categories Clinical Research, Preclinical Research and Case Reports. You can read more about this in the scientific report starting on page 10.


## Case presentations from practice

One of many highlights of the varied scientific program was the final session moderated by Dr. Karl-Ludwig Ackermann and Professor Thomas Taylor "Problems, complications and failures – what can we learn from them?" on particularly challenging patient cases by Professor Michael Stimmelmayer, Professor Juan

Blanco and Dr. Mario Beretta. The initial situations were presented by the respective clinicians and the treatment options were then discussed by an international group of experts. Afterwards the clinician presented the actual realized solution.

## Successful transition

The OR Foundation's global symposium was not an easy legacy. Since the CAMLOG Foundation was renamed to the Oral Reconstruction Foundation at the end of 2016, a new name had to be established for the biennial world congress, which was able to build on the great success of the international CAMLOG congresses. The OR Global Symposium in Rotterdam impressively proved that this transition has proved successful. The members of the Board of the OR Foundation – Professor Robert Sader (President), Oscar Battagay (Legal Counsel), Professor Fernando Guerra, Professor Irena Sailer, Professor Mariano Sanz, Dr. Alex Schär (Managing Director), Professor Thomas Taylor and Professor Wilfried Wagner – have succeeded in seamlessly transferring





the existing values and contents into the new organization. The close relationship of the Board to the previous Chairman Professor Jürgen Becker also contributed to this and he was expressly thanked for his services.

CAMLOG is the Founding Partner of the new, independent organization. During the press conference, Dr. René Willi, Member and Delegate of the CAMLOG Board of Directors, emphasized the close partnership between the OR Foundation and CAMLOG, particularly in the areas of research and training.

The objective of the OR Foundation to promote the oral health of patients by supporting science and education, links scientists, practitioners and the industry and was the central theme of the first OR Global Symposium throughout the partner network – a truly custom-tailored prelude in a royal environment!

And what happens next? Simply stay connected to the OR Foundation via your smartphone! You can meet the online community "INSIGHTS Dental" at <https://dental.insights.md/> on the Internet or the mobile app (see AppStore or PlayStore), which already accompanied you during the symposium. Create your individual profile – you will be informed daily about everything worth knowing in your areas of interest. Exchange ideas with peers on current topics and benefit from the latest publications from recognized experts in a rapidly developing online community. And of course you will also be provided with the latest information on the **OR Global Symposium from 30 April to 2nd May 2020 in New York.**







from left to right; Prof. Jürgen Becker, Dr. Tobias Fretwurst, Dr. Nicole Passia, PD Dr. Pinar Meric representing PD Dr. Erhan Çömlekoğlu, Prof. Fernando Guerra



## RESEARCH AWARD AND POSTER COMPETITION

The global symposium is always an excellent opportunity to not only promote science but also to encourage young scientists, devoted practitioners to present their work to a large audience. Great importance was also attached to this tradition at the Oral Reconstruction Global Symposium 2018 in Rotterdam. This year, the Research Award, the Poster Competition and the Short Poster Presentation offered excellent opportunities to achieve this goal.

### Research Award 2016/2017

Since its creation in 2008, the Research Award has been dedicated to young, talented scientists and application-oriented clinicians interested in scientific advances. Within the plethora of themes and interesting publications from several countries, the Scientific Evaluation Committee this year again had a difficult decision to take for the selection of the three best publications.

At the 5th edition of this award, the winners were honored at the Oral Reconstruction Global Symposium – the former International CAMLOG Congress. Professor Jürgen Becker, past president of the Oral Reconstruction Foundation, presided over the ceremony.

The **first prize**, endowed with € 10,000, went to **Dr. Nicole Passia** from the Clinic for Dental Prosthetics, Propaedeutics and Materials Science at the Christian Albrechts University in Kiel for her publication: "Survival and complications of single dental implants in the edentulous mandible

following immediate or delayed loading: A randomized controlled clinical trial". J Dent Res. 2018;97(2): 163-70. E-Publication: 18. October 2017 <https://www.ncbi.nlm.nih.gov/pubmed/29045800>

**Dr. Tobias Fretwurst**, from the Department of Oral and Maxillofacial Surgery at the Dental Center of the University Hospital in Freiburg, received the **second prize**, endowed with € 6,000. His publication was entitled: "The impact of force transmission on Narrow-Body dental implants made of commercially pure titanium and titanium zirconia alloy with a conical implant-abutment connection: an experimental pilot study" Int J Oral Maxillofac Implants 2016; 31: 1066-77. <https://www.ncbi.nlm.nih.gov/pubmed/27632261>

The **third prize** with a value of € 4,000 was awarded to **Assoc. Professor Erhan Çömlekoğlu** from the Department of Prosthetic Dentistry at the Faculty of Dentistry of Ege University Bornova in Izmir (Turkey). On behalf of Dr. Çömlekoğlu, who was unable to attend the ceremony,

Assoc. Professor Pinar Meric from the same university accepted the prize for the publication:

"Immediate definitive individualized abutments reduce peri-implant bone loss: a randomized controlled split-mouth study on 16 patients". Clin Oral Investig. 2018; 22(1): 475-86. E-Publication: 31. May 2017. <https://www.ncbi.nlm.nih.gov/pubmed/28567530>

### Poster Competition 2018

More than 50 posters were accepted by the jury for the poster competition 2018. Five of them were selected for a short presentation during the session on Friday afternoon. The oral presentation is an excellent opportunity to present the works done over the years to a large audience. The speakers presented the results of several clinical trials which included: three prospective trials with five-year and three year follow-ups (PD. Dr. S. Rocha, PD. Dr. M. Moergel, Dr. L. Fierravanti), a retrospective study with up to 13 years of follow-up (Dr. Y. Duan) as well as a case report (Dr. T. Page).





from left to right: Prof. Jürgen Becker, Dr. Ludovica Fierravanti, Dr. Anders Henningsen, Françoise Peters, Prof. Fernando Guerra




In addition to the selection for the oral presentations, the best case report, the best clinical study and the best preclinical research work were selected from all participating posters. The three winners each received a monetary prize with a value of € 2'000.

The Poster Jury selected the posters, which will be published in International Poster Journal of Dentistry and Oral Medicine as well as on the Oral Reconstruction Foundation website.

Members of the Poster jury:  
 Prof. Pedro Nicolau, Prof. Fernando Guerra,  
 Françoise Peters, Dr. Ben Derksen




**THE THREE WINNING POSTERS**



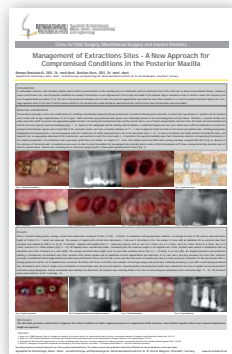**Category Clinical Research**

Dr. Ludovica Fierravanti  
 Title: The effect of one-time abutment placement on marginal bone levels and peri-implant soft tissues: 3 years results from a prospective randomized clinical trial  
 Co-authors: Ambrosio N, Molina A, Sanz I, Martin C, Blanco J, Sanz M.



**Category Pre-clinical Research**

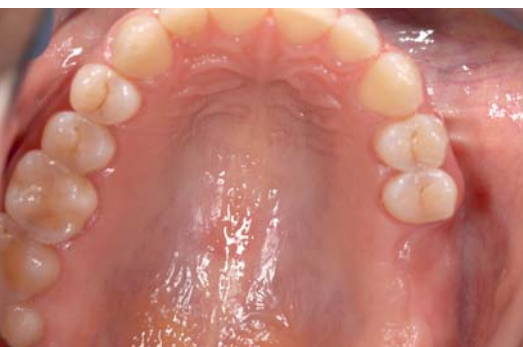Dr. Anders Henningsen  
 Title: Influence of UV-light and non-thermal plasma on rough titanium surfaces in vitro  
 Co-authors: Smeets R, Cacaci C, Heuberger R, Heinrich O, Hartjen P, Hanken H, Precht C.



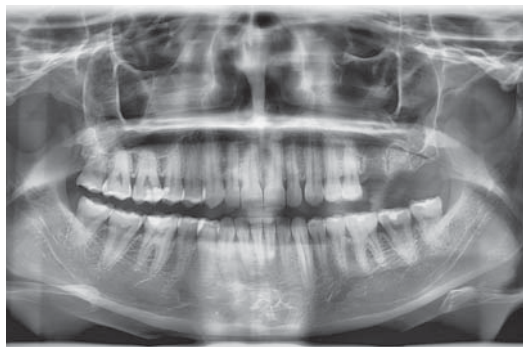
**Category Case Report**

Dr. Roman Beniashvili  
 Title: Management of extractions sites new approach for compromised conditions in the posterior maxilla  
 Co-authors: Kern B.

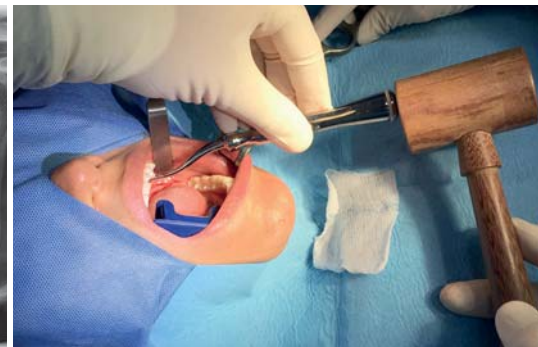



**Fig. 1:** The initial situation: a unilateral free-end situation in the left upper jaw: teeth 26-28 are missing.



**Fig. 2:** The X-ray shows the sufficiently high bone in the area of the maxillary sinus to accommodate two implants.



**Fig. 3:** To condense the soft bone over the sinus floor, the bone site was prepared using an osteotome.



## CERALOG® IMPLANTS THE SOLUTION FOR SPECIAL PATIENT NEEDS

Dr. Detlef Hildebrand, Berlin

Patient demand for metal-free implant solutions is steadily increasing. Although titanium implants are biocompatible and well tolerated [1], studies have found titanium oxide burdens in the body after implantation [2]. It is being discussed that an inflammatory reaction of varying intensity is detectable in a few patients, depending on the genetic disposition [3]. In contrast, fewer reactions have been observed with zirconium dioxide particles. A further advantage of zirconium dioxide implants is their good tissue compatibility. In the following, a patient case is presented in which two-piece CERALOG® Hexalobe implants were inserted in the maxillofacial free-end situation and systematically documented.

Ceramic implants have been on the market for many years, but the percentage share of the total dental implant market remained largely modest. One reason for this was the bad experiences in the 1980s and 1990s with many ceramic fractures – particularly with one-piece implants made of aluminium dioxide, the so-called Tübingen and Munich immediate implants – and the lack of scientifically based data at that time [4].

Intensive material research in recent years has led to the newer generation, the yttrium-tetragonal-stabilized zirconium dioxide, which defines the new industrial standard. It proves convincing, for example, in the crown and bridge technique and as an abutment material. Thus, the

material strength for implants no longer proved a challenge, the focus was now primarily on the inner surface quality of the  $ZrO_2$  material, which was identified as a possible source of error during integration, as well as a reversibly screw-retained two-piece version. Newer high-tech manufacturing processes to achieve a bone-friendly surface texture on zirconium dioxide implants, such as the injection molding process, now create significantly more confidence in this technology. [5]. If we interpret the signs of the times correctly, we are on the verge of being able to treat patients with special, in part medically justified requirements, with these new materials in terms of implants and long-term stability.

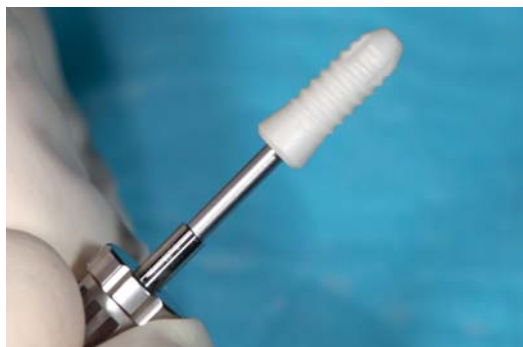### Findings and therapy planning

A 38-year-old female patient presented in our practice with a free-end situation in the second quadrant. As the residual dentition was completely intact, she wished for a fixed, metal-free restoration to replace the two missing molars. After detailed explanation of the implant treatment as well as reference to the little documented study situation on zirconium dioxide implants, we planned the restoration on the two-piece CERALOG® Hexalobe implants. The X-ray showed a sufficiently high alveolar bone for insertion of two 10 mm long implants without elevation of the sinus floor (**Figs. 1 and 2**).





**Fig. 4:** The presentation of the CERALOG® Hexalobe implants in the packaging.



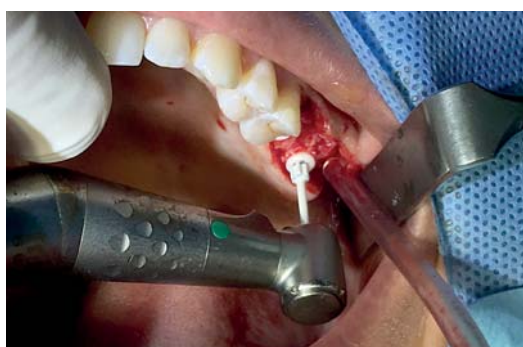**Fig. 5:** The insertion tool fits into the inner configuration of the all-ceramic CERALOG® Implant.



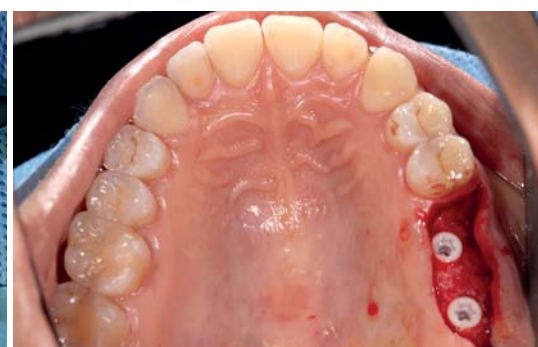**Fig. 6:** The mechanical insertion option for the implants.



**Fig. 7:** The implants were immersed in the growth-promoting PRGF liquid prior to insertion.



**Fig. 8:** When screw-retaining the zirconium dioxide implants, it is essential to avoid too high a torque.



**Fig. 9:** The correctly positioned and stably inserted CERALOG® Implants before soft tissue closure.

### Implant bed preparation with bone condensation

After a ridge incision and the preparation of a full flap, the implant position was marked with a round bur. A pilot drill ( $\varnothing$  2.0 mm) was used to set the implant axis at a depth of approx. 6 mm and to check the implant position with the direction indicator. As the bone quality in the distal maxilla was very soft, the bone site was prepared using osteotomes. Primary stability was achieved by condensation of the bone. Another advantage of osteotome preparation is the prevention of penetrating the Schneider's membrane, which could be caused by careless handling of the drills. Using the osteotome, the tunnel was widened to correspond to the four millimeter implant diameter. The implant bed was advanced to the full implant length, in this case 11.5 mm, as the implant was to be placed approximately epicrestally (**Fig. 3**).

After the complete preparation of the implant site, the sterile packed CERALOG® Hexalobe implants were removed from the packaging with the insertion tool and prepared for insertion. (**Figs. 4 and 5**).

### Epicrestal implant placement

Before inserting the CERALOG® Implants, the surface was wetted with the bone-active cells of the PRGF liquid. In our practice, the innovative PRGF® procedure, in which the patient's own growth proteins are used to accelerate healing processes and reduce the risk of discomfort and complications, is used for all implant procedures, irrespective of the material composition. (**Figs. 6 and 7**).

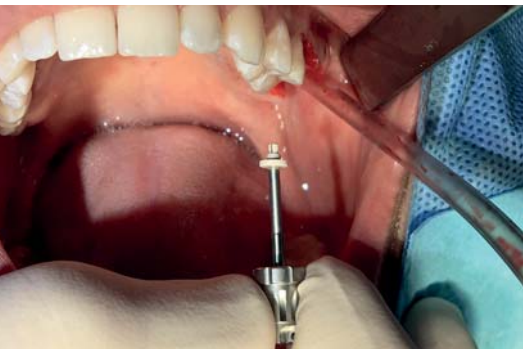
As zirconium dioxide is a poor thermal conductor, slow, pressure-free insertion must be ensured when inserting the zirconium dioxide implants. Implantation was performed with a defined torque of

max. 35 Ncm and 15 rpm. The implants were placed minimally supracrestally so that the implant shoulder was approximately 0.5 millimeters above the alveolar bone. (**Figs. 8 and 9**).

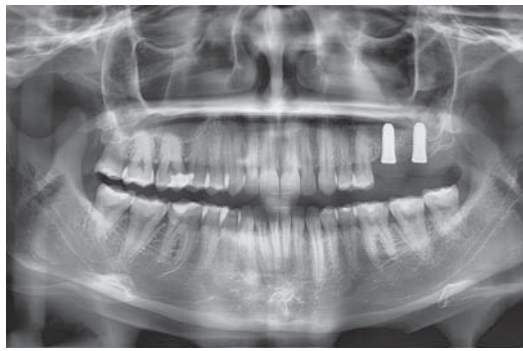The cover caps were clicked into the implant interface to protect against ingrowing bone and tissue ingrowth. The mucoperiosteal flap was repositioned tension-free and sutured saliva-tight over the cover caps and a control X-ray was taken. (**Figs. 10 and 11**).

In the invisible region of the maxilla in regions 26 and 27, we dispensed with an interim restoration to protect the implants. The healing of the two CERALOG® Implants was completely symptom-free. The patient had no atypical symptoms whatsoever. Discussions on the healing period for ceramic implants is still ongoing. Longer healing times than with titanium implants are suggested

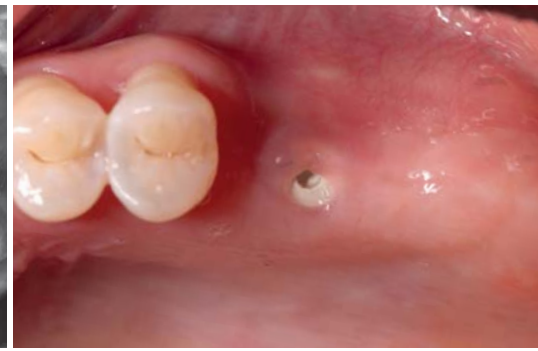



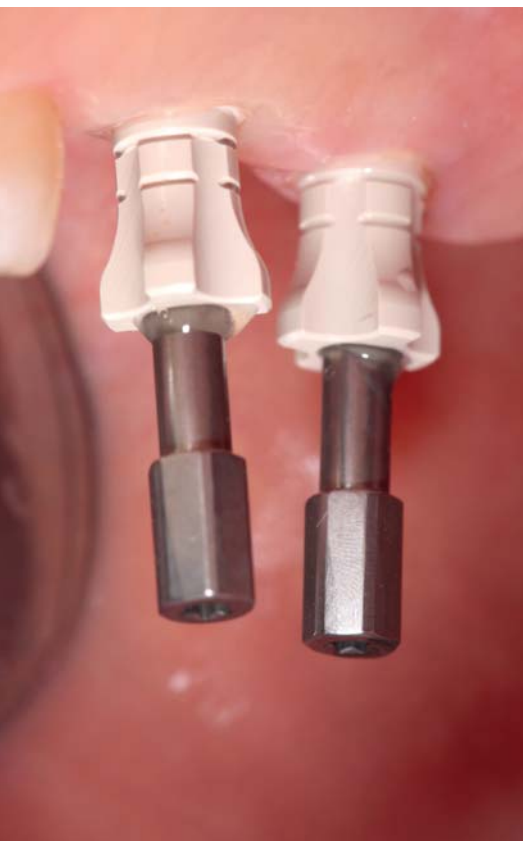**Fig. 10:** The implants were covered with the cover cap, which is part of the implant pack.



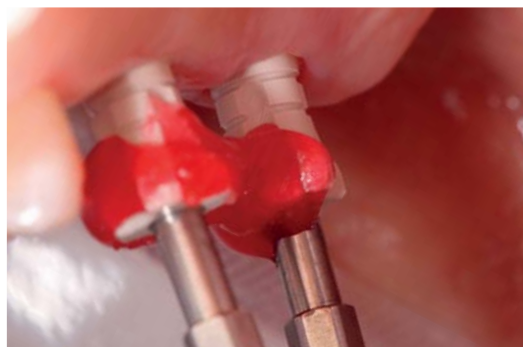
**Fig. 11:** The postoperative X-ray image shows the excellent positioning of the two CERALOG® Implants in regions 26 and 27.




**Fig. 12:** At the time of exposure, the implant was exposed in region 26.



**Fig. 16:** Posts for the open tray technique were selected for impression taking.



**Fig. 17:** For safe transfer of the implants, the impression posts were blocked intraorally with plastic.



**Fig. 18:** The long screws of the impression posts allow easy intraoral loosening.

### Minimally invasive exposure

In the present case, the implants were exposed after 14 weeks. In addition to the manual and visual control, a control X-ray was taken to check healing of the implants. At this time, the cover cap of the implant region 26 was partially exposed due to soft tissue resorption (**Figs. 12 and 13**).

The exposure was performed minimally invasive without flap technique. Access to the cover caps was created with a puncture incision. These were removed and 2.5 mm high gingiva formers were used to form the peri-implant soft tissue (**Figs. 14 and 15**).

The impression was taken only one week after exposure and healing of the mucosa. The impression posts for the open tray technique were used for this purpose. In cases where several implants are placed side by side for planned prosthetic splints, our Berlin concept always involves connecting the impression posts. Splinting with Pattern resin (GC) avoids possible

transfer errors during impression taking (**Figs. 16 and 17**).

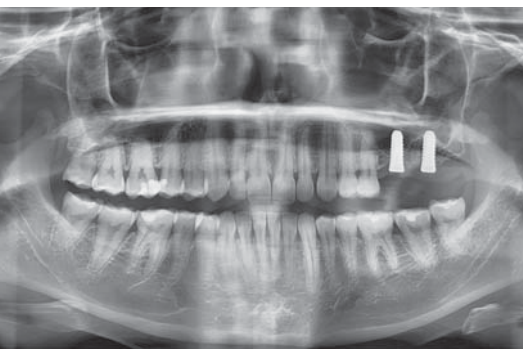A conventional impression procedure with an individual tray is then selected for the subsequent workflow. This procedure ensures a high-precision implant transfer to the dental laboratory. Although this high-precision impression technique is complex to perform, it guarantees reliable, result-oriented further processing in the laboratory with the required quality for the CAD/CAM processing techniques (**Figs. 18 and 19**).

### Prosthetic reconstruction – splinted and screw-retained

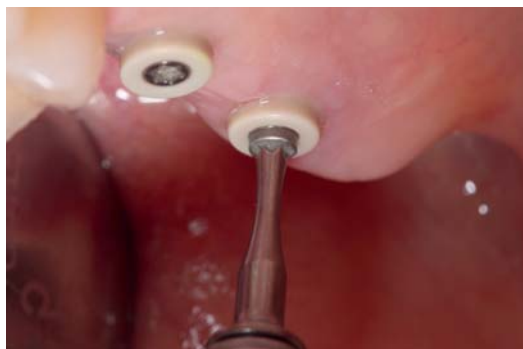During cast fabrication in the laboratory, the emphasis is placed fully on the exact transfer of the implant positions and the surrounding soft tissue. After screw-retaining the lab analogs, the material for the removable gingival mask was injected and after curing, the impression was filled with plaster. (**Fig. 20**).

Using a face bow and a bite registration, the maxillary master cast and the

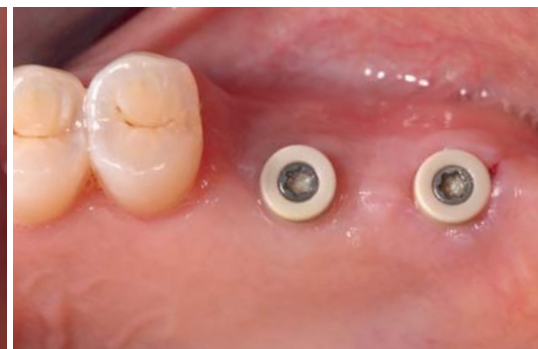



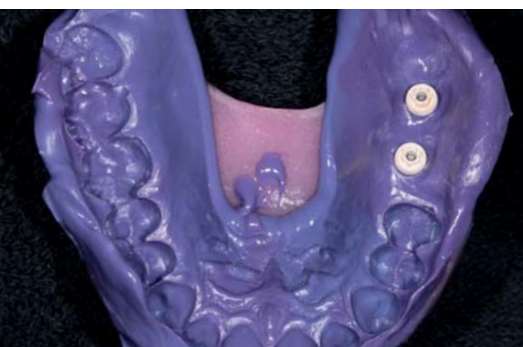**Fig. 13:** The post-healing control OPG confirms the good osseointegration of the two CERALOG® Implants.



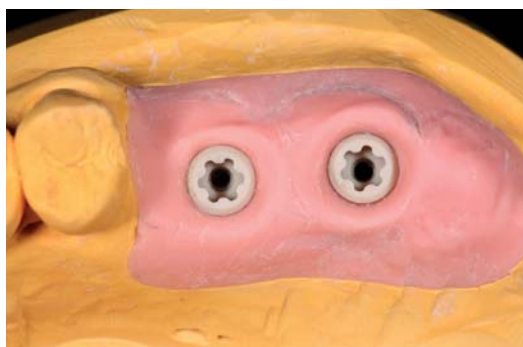**Fig. 14:** The 2.5 mm high gingiva formers were used to shape the soft tissue.



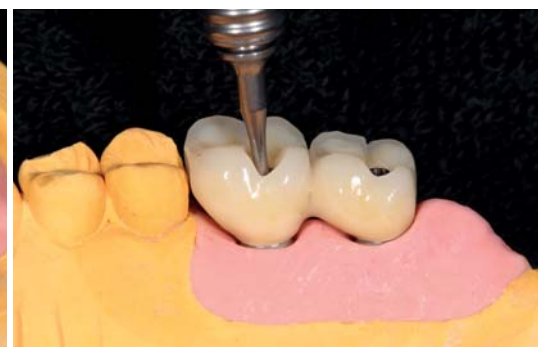**Fig. 15:** The occlusal view of the two gingiva formers directly after the exposure surgery.



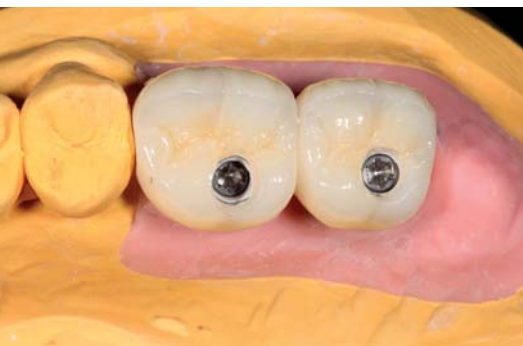**Fig. 19:** The impression of the two CERALOG® Implants with open tray technique and IMPREGUM precision impression material.



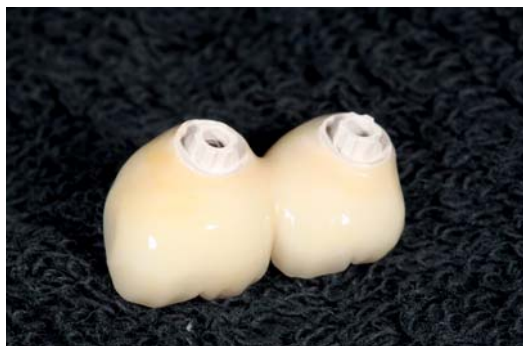**Fig. 20:** The master cast with removable gingival mask. The shape of the soft tissue is clearly visible.



**Fig. 21:** The milled, splinted crowns were bonded to the PEKK abutments.



**Fig. 22:** The precisely positioned screw access channels.



**Fig. 23:** The precise transition of the crowns to the PEKK abutments.

mandibular counter model were mounted in the articulator and the two CERALOG® PEKK abutments of the occlusion were shortened accordingly. The crowns were to be splinted and screw-retained directly. The situation was scanned and the crowns were designed digitally and fabricated from zirconium dioxide. After stain firing, the crowns were finalized. Both the crowns and the PEKK abutments were activated and then bonded to the cast. A special focus was placed on the

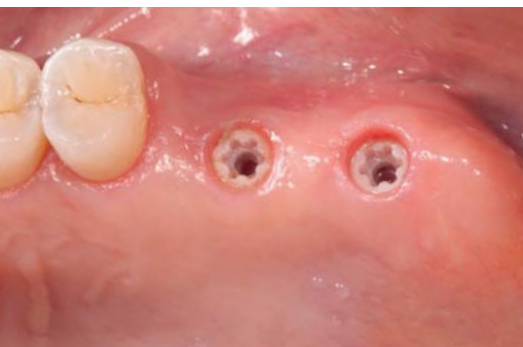good hygienic ability of the implant crowns (**Figs. 21 to 23**).

Overall, the two occlusally screw-retained crowns were fabricated without any problems. Despite the new materials and system components, this case with the CERALOG® System, which was new for us, was performed expertly and routinely by the dental technicians.

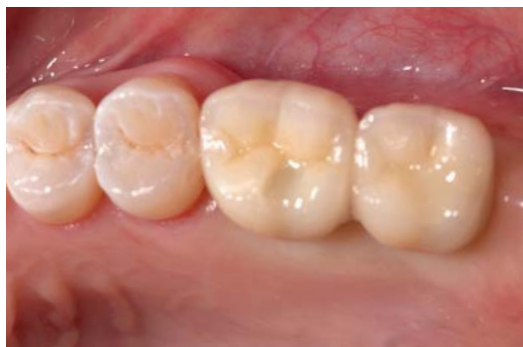Finally, the crowns were placed in the patient's mouth. A well-healed intraoral

situation was present. The crowns were inserted and screw-retained with the titanium abutment screws and a defined torque of 15 Ncm. After the final functional and esthetic check, the screw access channels were sealed with cotton pellets and the Sinfony-Flow Composite (Espe). The patient was pleased, as was the treating team, about the very successful restoration (**Figs. 24 to 27**).

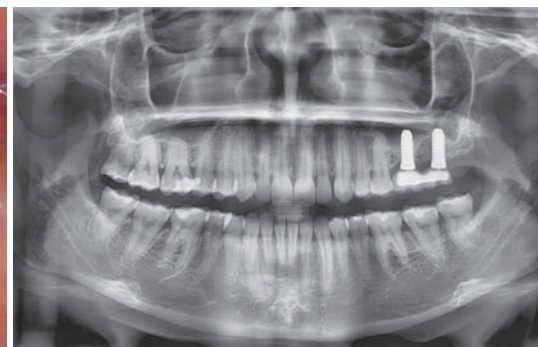




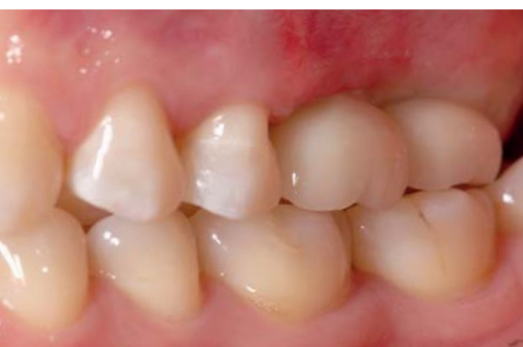**Fig. 24:** The stable soft tissue situation before insertion of the crowns.



**Fig. 25:** After integrating and checking the function and esthetics, the screw access channels were sealed.



**Fig. 26:** As PEKK is not radiopaque, reading the control image requires some time and experience.



**Fig 27:** Final inspection of the crowns inserted in regions 26 and 27.

## Conclusion

During the entire treatment period there were no problems with the application and execution as well as handling of this implant system. The system was also regarded as being well designed and user-friendly by the involved master dental technician.

The two-piece CERALOG® Hexalobe offers implantologists a scientifically well documented and clinically easy to implement alternative to classic titanium implants. The user-friendly system creates confidence in this new material selection in the implant sector. One of the advantages of ceramic implants is their good tissue compatibility with regard to osseointegration, gingival closure and low plaque accumulation. Our patients will certainly be increasingly pleased with the "white" version of our artificial new tooth roots.

My special thanks go to MDT Timo Jäkel, Dental-Concept Berlin, for his support and the successful fabrication of the superstructures.

## LITERATURE

- [1] Buser D, Sennerby L, De Bruyn H. Modern implant dentistry based on osseointegration : 50 years of progress, current trends and open questions. *Periodontol* 2000
- [2] Jacobi-Gresser. Titanüberempfindlichkeit oder Titan-unverträglichkeit? *Quintessenz* 2017;68(12):1413-20
- [3] Bartam F. Titan als möglicher Verursacher lokaler und systemischer Gesundheitsstörungen – eine aktuelle praxisorientierte Zwischenbilanz. *umwelt-medizin-gesellschaft* | 1616 | 1/2009
- [4] Pieralli S, Kohal RJ, Jung RE, Vach K, Spies BC. Clinical outcomes of zirconia dental implants: A systematic review. *J Dent Res.* 2017;96(1):38-46
- [5] Cattani-Lorente M, Scherrer SS, Durual S, Sanon C, Douillard T, Gremillard L, Chevalier J, Wiskott A. Effect of different surface treatments on the hydrothermal degradation of a 3Y-TZP ceramic for dental implants. *Dental Materials* 2014; 30:1136-46.

## AUTHOR



### Contact details

Chirurgisches Zentrum Berlin  
Dr. Detlef Hildebrand  
Westhafenstraße 1  
13353 Berlin  
[www.zahnarztpraxis-hildebrand.de](http://www.zahnarztpraxis-hildebrand.de)

### Dr. Detlef Hildebrand

After training as a dental technician, Dr. Detlef Hildebrand studied dentistry at the Albert-Ludwigs University in Freiburg until 1992 he became licensed to practice dentistry. In the Clinic and Polyclinic for Dental Prosthetics in Freiburg under the Medical Director Professor J. R. Strub he worked as an assistant physician. Dr. Hildebrand received his doctorate in 1995 and was senior physician at the Clinic and Polyclinic for Dental Prosthetics in Freiburg for two years. For eight years he established the Department of Implant Dentistry at the CHARITÉ, Campus-Virchow-Klinikum, Clinic for Maxillofacial-/plastic Surgery (Director: Professor mult. h.c. J. Bier t), and has been running his private practice in the Westhafen since 1998. One year after founding the practice, he established the Dental Concept Berlin dental laboratory. Dr. Detlef Hildebrand is a Member of the Board and Secretary General of the BDIZ EDI e. V. He conducts research on implant dentistry and prosthetics as well as navigation and robotics, on which he has written various scientific papers.

CERAMIC EXCELLENCE

CERALOG<sup>®</sup>  
SYSTEM

# INNOVATIVE



**Sophisticated two-piece construction with innovative abutment solution, ceramic-specific design and high-tech 'Ceramic Injection Molding' manufacturing process – that is CERAMIC EXCELLENCE.**

- Dual surface texture: Osseointegration and soft tissue attachment
- Two-piece design, screw-retained reversible prosthetic solutions
- Ceramic-specific design with Hexalobe connection
- Innovative PEKK abutment with stress shield reduction
- Ivory colored for highly esthetic restorations
- 100 % quality control

CERAMIC-SPECIFIC  
DESIGN WITH  
HEXALOBE  
CONNECTION



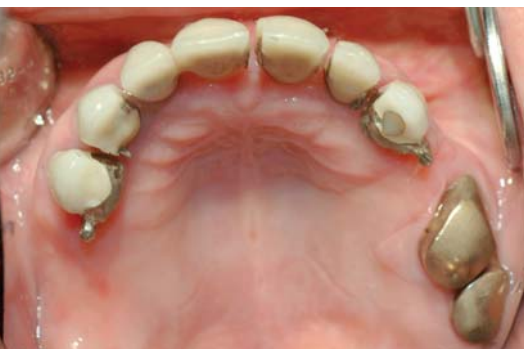Become a  
CERAMIC EXCELLENCE  
partner now  
[www.camlog.com/en/implant-systems/ceralog](http://www.camlog.com/en/implant-systems/ceralog)



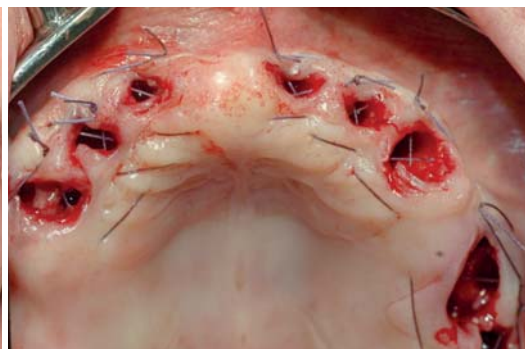a perfect fit™

camlog

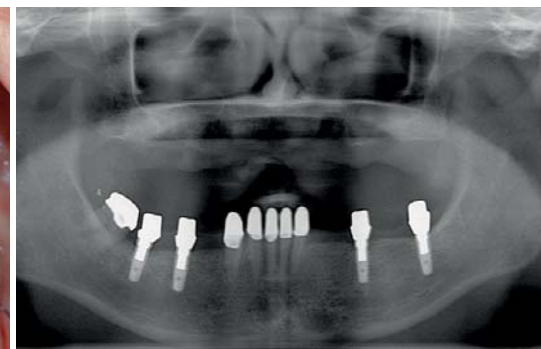




**Fig. 1:** The initial situation.



**Fig. 2:** After extraction of all remaining teeth in the upper jaw, the missing vestibular bone wall appears frontolaterally in region 14-24.



**Fig. 3:** X-ray orthopantomography (OPT) before bone formation in the maxilla: low bone height in the posterior region with deep recessus alveolares.



## RESTORATION OF AN EDENTULOUS UPPER JAW COMBINED PROCEDURE WITH FACIAL SINUS LIFT

Dr. Karina Lohr, Karlsruhe

The edentulous jaw is the most common indication for the use of augmentation procedures and occurs in 36 percent of all cases. The upper jaw dominates with 75 percent of all cases. Many patients with minimal residual dentition or edentulous jaws would like a fixed restoration. For a long-term stable implant-supported reconstruction, complex surgical measures are often necessary to create an adequate implant site. The following describes the therapy of an upper jaw after progressive periodontal disease with autologous bone block augmentation [1].

Bone defects in the upper and lower jaw due to trauma or pronounced atrophy of the jaw after tooth loss can significantly impair the function and esthetics of the affected patients. This can even lead to stigmatization or social isolation. The extent of the defect influences the surgical and prosthetic restoration options. In dentistry as well as in the field of reconstructive oral and maxillofacial surgery, adequate functional rehabilitation is required in addition to the anatomical reconstruction of hard and soft tissue. Besides the ability to speak and eat, the quality of life and social acceptance are determined by facial expressions and esthetics.

The present case of a 61-year-old female patient already shows the distinct loss of the vestibular bone wall after extraction of the remaining teeth, which had to be removed due to progressive periodontal disease and which further atrophied

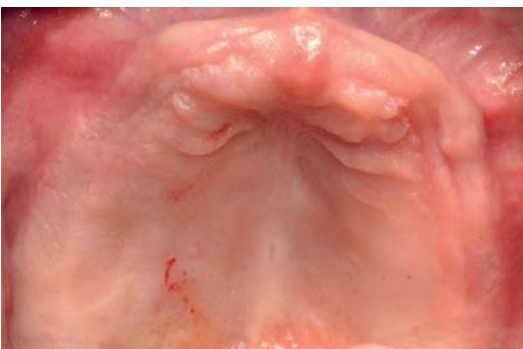as part of the healing process (**Figs. 1 and 2**).

### Combined bone augmentation

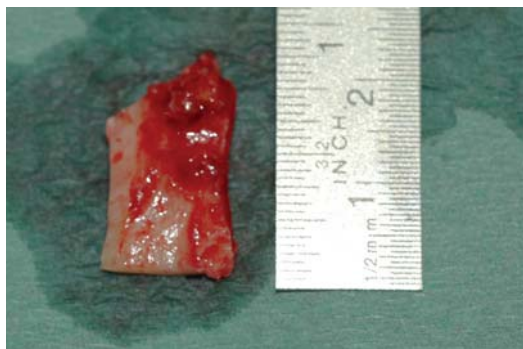
After healing, the typical centripetal atrophy of the upper jaw with extensive recessus alveolares on both sides, a narrow frontolateral alveolar ridge and flattening to the distal side is impressive both radiologically and clinically. (see **Figs. 3 and 4**). Bone augmentation is indispensable to obtain a sufficiently stable implant site. Various bone or bone replacement materials are available today for this purpose. These can be obtained interoperatively as blocks, shells, cylinders, granules, chips or shavings or supplied industrially. In our practice, we prefer autologous bone for augmentation.

After an alveolar ridge incision and forming a mucoperiosteal flap, the frontolateral region was built up horizontally with

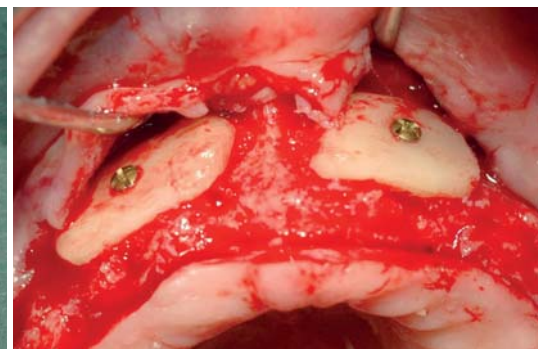
autologous grafts. These grafts have the advantage that partially vital cells survive in the cancellous bone [2] in order to support the new formation of bone. This only osteogenic graft material is still considered the gold standard in dental surgery. Two bone blocks were harvested from the retromolar region (**Fig. 5**), which were adapted as precisely as possible to the situation. Since revascularization in cancellous bone is faster than in compact bone [3;4] and the blood vessels and mesenchymal cells grow exclusively from site tissue (70%) and periosteum (30%), the graft should rest tightly [5]. The grafts were fixated with one osteosynthesis screw each (**Fig. 6**). In the distal upper jaw, the recessus alveolaris expanded and the alveolar process thinned out below the maxillary sinus and the connection to the pneumatic system of the nose, due to tooth loss. To achieve an adequate implant site, a lateral sinus lift in window and sandwich technique (**Figs. 7 and 8**)



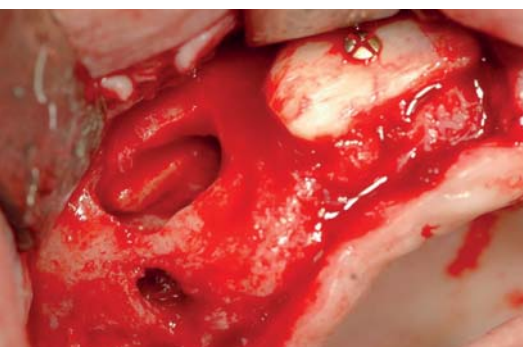
**Fig. 4:** Clinical status prior to augmentation with clear centripetal atrophy of the upper jaw.



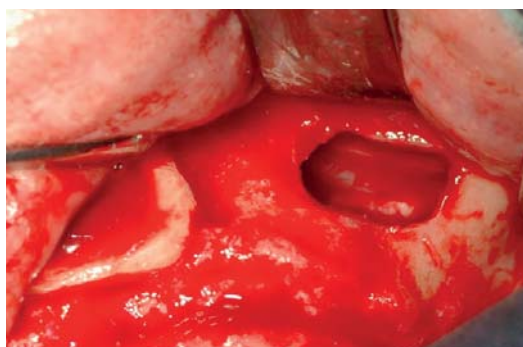
**Fig. 5:** Autologous bone chip harvested from the retromolar triangle.



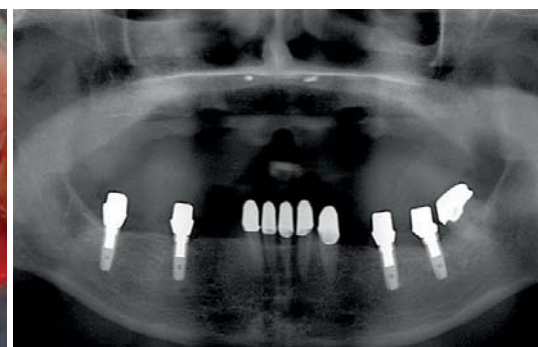
**Fig. 6:** Bone grafts fixated with mini screws in the anterior maxilla region 13-23.



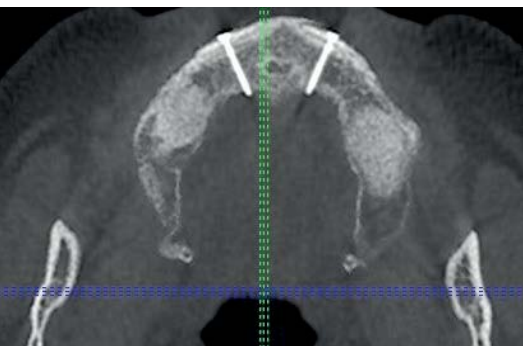
**Fig. 7:** Simultaneous lateral sinus lift, right, after folding the facial bone window.



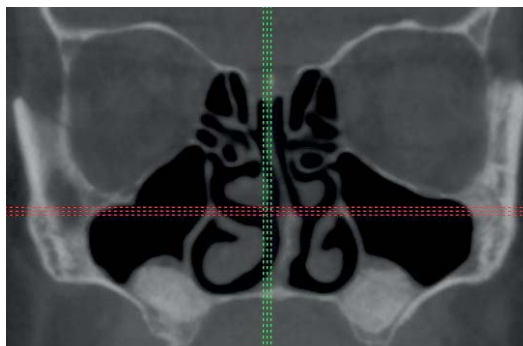
**Fig. 8:** Simultaneous lateral sinus lift, left, after folding the facial bone window.



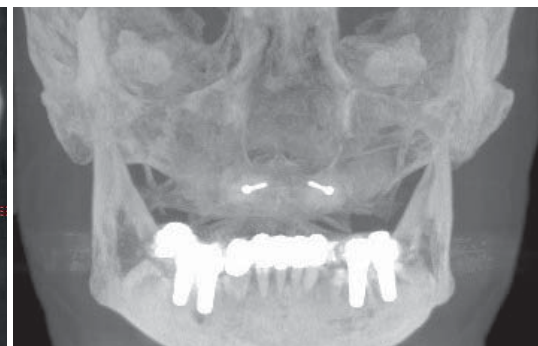**Fig. 9:** X-ray control by orthopantomography (OPT) after bone grafting: visible mini screws in the anterior maxilla, augmented recessus alveolares.



**Fig. 10:** Digital volume tomography (DVT) for pre-implantation measurement: horizontal layering, visible osteosynthesis screws and bone grafts.



**Fig. 11:** Digital volume tomography (DVT) for measurement before implantation: vertical layering, clearly visible sinus lift.



**Fig. 12:** Digital volume tomogram (DVT) for measurement before implantation: right side view, visible osteosynthesis screw.

for vertical augmentation [6;7] was performed simultaneously on both sides. A micro drill was used to create a window in the thin bone in the area of the maxillary sinus. The facial window remained on the membrane and was carefully folded from the bone base after loosening the Schneider's membrane and moved cranially. This created a free space which was then filled with a suitable augmentate (Cerasorb® by Curasan). The window was covered with a mucoperiosteal flap.

The postoperative X-ray images show the sufficient augmentation of the entire maxilla in all planes (Fig. 9) prior to planned placement of six CAMLOG® implants in region 16/14/12/22/24/26 for a telescope-supported prosthetic restoration.

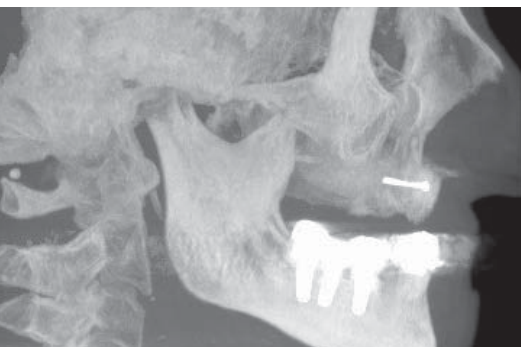
### Implantation

Horizontal and transverse radiographs in the DVT prior to implantation showed good bone availability in the planned

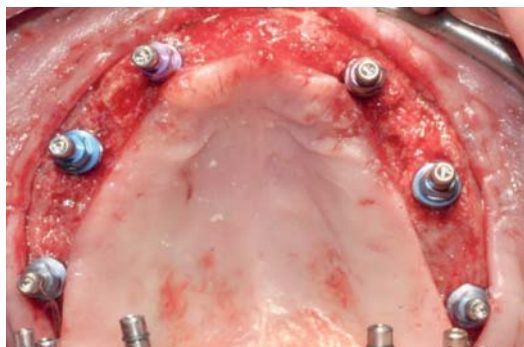implant regions. The bilateral sinus lift offered sufficient bone height for implant lengths over 14 mm to achieve a favorable implant-crown ratio (Figs. 10 and 11). Frontolateral augmentation with retromolar bone chips guaranteed a proper sagittal abutment position in the critical front segment (Fig. 12), as the frontal and side view of the preoperative DVT (Fig. 13) before implantation shows.

As planned, the six CAMLOG® Implants could be placed in the statically ideal

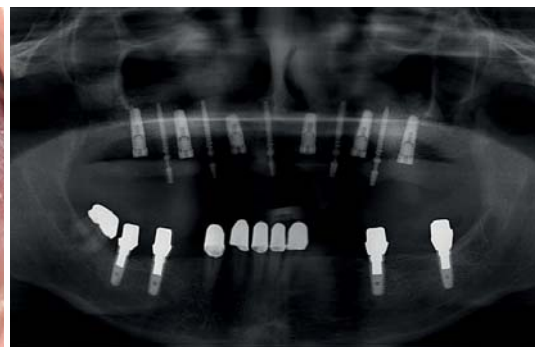




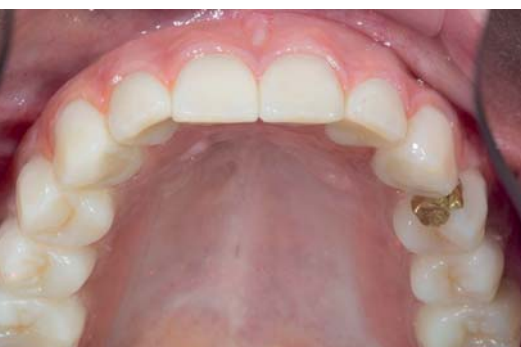**Fig. 13:** Digital volume tomography (DVT) for pre-implantation measurement: face views, visible bone grafts and mini screws.



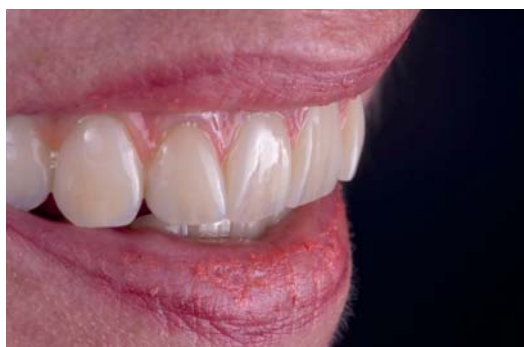**Fig. 14:** Intraoperative status after implantation in the maxilla with insertion post in situ (mirror image).



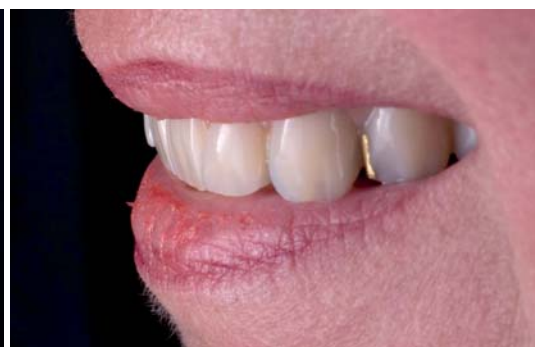**Fig. 15:** X-ray control by orthopantomogram (OPT) after implantation: five temporary implants (IPI's) in situ to support the prosthesis.



**Fig. 19:** Intraoral view of the denture in the upper jaw with gold inlay.



**Fig. 20:** Extraoral view of the prosthesis with customized tooth position.



**Fig. 21:** Extraoral view of the prosthesis with incorporated gold inlay.

position after three months (**Fig. 14**) ( $\varnothing$  5.0 mm / L 13 mm or  $\varnothing$  4.3 mm / L 11mm). Five temporary implants (IPI's) were used to support the interim prosthesis (**Fig. 15**).

The implants were exposed after approximately six months, the interim implants were removed and gingiva formers were inserted. To compensate for the vestibular gingival deficit, the palatal soft tissue was moved buccally and the ridge incision was sutured. Open gap areas healed secondary and led to a dense peri-implant cuff (**Fig. 16**).

### The definitive denture

The final prosthesis was fabricated four weeks after exposure. After registration and impression taking, the dental technician created an esthetic and functional set-up. Based on this, primary telescopes were made of zirconium oxide on the titanium bases CAD/CAM. The secondary telescopes and the framework were milled from the high-performance plastic PEEK using the CAD/CAM process. PEEK is break-resistant, has good sliding

properties and is not susceptible to plaque. (**Figs. 17 and 18**).

The ceramic abutments and customized design of the telescope-supported dental prosthesis offered the best static, functional and esthetic conditions for patient satisfaction and hygiene capability (**Fig. 19**).

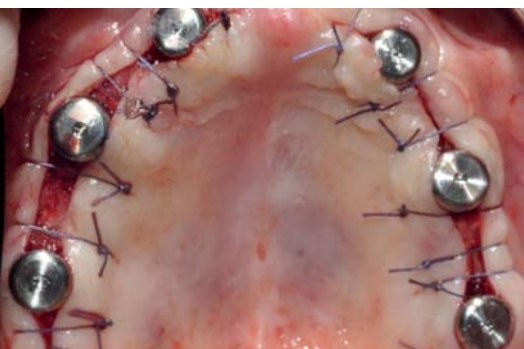
The extraoral view shows the advantages of the customized design up to the incorporation of a gold inlay in region 24 at the request of the patient, which does not have the negative appearance of conventional prostheses due to the very stable anchorage and palate-free design (**Figs. 20 and 21**).

### Discussion

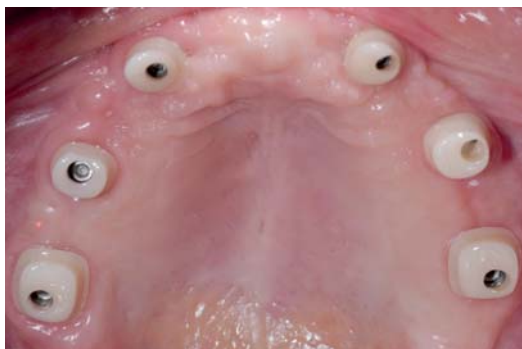In addition to the free-end situation, the edentulous upper jaw offers the most frequent indication for horizontal and vertical bone augmentation. In the frontolateral segment of 14-24, a horizontal augmentation is usually necessary to counteract the dorsal position of the alveolar ridge.

In the molar region, on the other hand, a sinus lift is necessary in order to achieve a sufficient vertical dimension due to the extension of the maxillary sinus. An absolute vertical abutment is rarely required here, at best in the case of large differences between crown and implant lengths due to bony step formation, typically in interdental gaps or free-end situations.

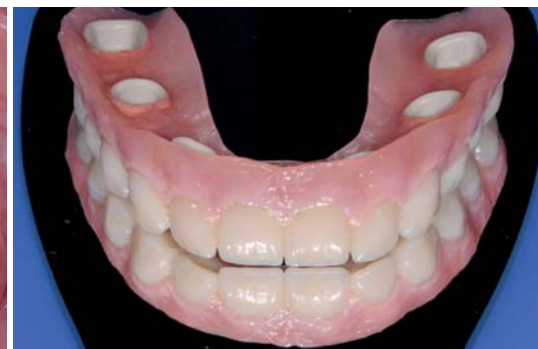This case shows this problem in an ideal way and leads to an attractive result, which takes into account the forward displacement of the anterior teeth through horizontal augmentation as well as the sufficient implant length in the molar region through a lateral sinus lift. The restoration with ceramic abutments leads to irritation-free gingival healing and a very stable prosthetic restoration. There are almost no limits to the degree of customization, as the steep tooth position and inlay insert show. Neither sinus lift nor frontolateral augmentation require alternative methods such as iliac crest / tibia removal or foil techniques as long as the graft size from retromolar is sufficient.



**Fig. 16:** Status after implant exposure in the maxilla with lateralization of the gingiva.



**Fig. 17:** Status after insertion of the ceramic telescopic anchor in the upper jaw.



**Fig. 18:** Customized removable telescopic ceramic maxillary prosthesis.

In summary it can be stated that autologous bone grafts are ideal for augmentation procedures due to their biological, immunological and biomechanical value and their forensic superiority [8]. The application is only restricted by the limited availability [9].

The mechanical (cortical) and osteogenetic (cancellous bone) properties are better than in allogeneic, xenogeneic and alloplastic procedures [10].

My special thanks go to the co-author Dr. Thomas Thein, Karlsruhe.

## LITERATURE

- [1] de Groot RJ1, Oomens MAEM2, Forouzanfar T3, Schulten EAJM3. J Oral Rehabil. Bone augmentation followed by implant surgery in the edentulous mandible: A systematic review. 018 Apr;45(4):334-343.
- [2] Axhausen W: 2. Die Individual- und Artspezifität des transplantierten Knochengewebes. Lan-genbecks Arch Klin Chir Ver Dtsch Z Chir 306: 18-25 (1964)
- [3] Gnamm C: Die biologische Qualität des Transferknochens: Gibt es Unterschiede in den verschiedenen Spenderregionen? Med Dissertation, LMU München, S. 47-52 (2006)
- [4] Holz U, Weller S, Borell-Kost S: Indikation, Technik und Ergebnisse der autogenen Knochen-transplantation. Chirurg 53: 219-224 (1982)
- [5] Brzenska I: Augmentationsplastiken mit großvolumigen kortikalen und spongiösen Tibiatrans-plantaten. Eine Darstellung ambulanter Operationsverfah-ren. Med Dissertation, Charité Uni-versitätsmedizin Berlin, S. 50-57
- [6] Hirsch JM, Ericsson I: Maxillary sinus augmentation using mandibular bone grafts and simultane-ous installation of im-plants. A surgical technique. Clin Oral Implants Res 2: 91-96 (1991)
- [7] Khoury F: Augmentation of the sinus floor with mandibular bone block and simultaneous implantation: a 6-year clinical in-vestigation. Int J Oral Maxillofac Implants 14: 557-564 (1999)
- [8] Misch CM: Comparison of intraoral donor sites for onlay grafting prior to im-plant placement. Int J Oral Maxillofac Implants 12: 767-776 (1997)
- [9] Klinge B, Alberius P, Isaksson S, Jönsson J: Osseous re-sponse to implanted natural bone mineral and synthetic hy-droxylapatite ceramic in the repair of experimental skull bone defects. J Oral Maxillofac Surg 50: 241-249 (1992)
- [10] Arx T von, Kurt B: Die enorale Knochenentnahme zur Autotransplantation. Eine klinische Vergleichsstudie der Ent-nahmestellen im Kinnbereich und in der Retromolar-Region. Schweiz Monatsschr Zahnmed 108: 446-459 (1998)

## AUTHOR



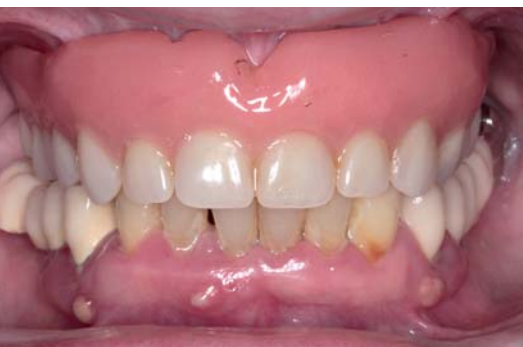### Contact details

Practice Clinic Dr. Thomas Thein and Colleagues  
Maxillofacial and plastic surgery  
Stephanplatz 1  
76133 Karlsruhe  
info@praxisklinik-postgalerie.de

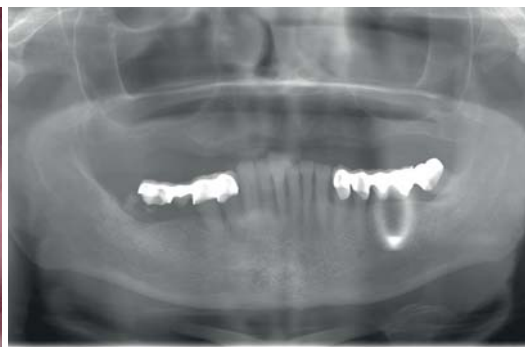### Dr. Karina Lohr

After training as a goldsmith and graduating as a master goldsmith in 2000, Dr. Karina Lohr trained as a web designer and DIP specialist at the Academy for New Media in Ludwigsburg. After graduating, she studied dentistry at the University Hospital in Heidelberg from 2003 to 2008. Since 2008 she has been working in the practice clinic for maxillofacial surgery in Karlsruhe. In 2013, Dr. Karina Lohr was recognized as a specialist in oral surgery with a focus on implant dentistry.

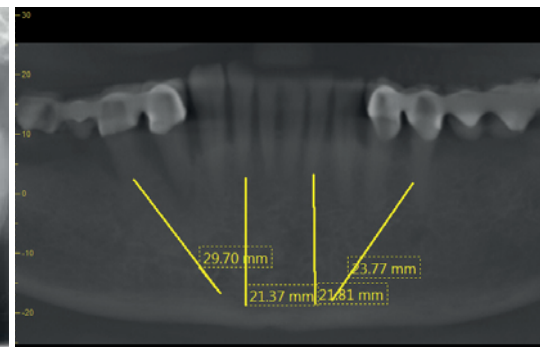




**Fig. 1:** The site of an insufficient mandibular bridge restoration.



**Fig. 2:** The radiographic representation of the initial situation.



**Fig. 3:** Digital volume tomography to evaluate bone height and thickness.



## IMMEDIATE FIXED REHABILITATION THE RESTORATION OF EDENTULOUS JAWS WITH THE AID OF A MODIFIED PRACTICE CONCEPT

Dr. Dominik Emmerich, Ravensburg

Immediate strong teeth is an increasingly frequent request of patients after multiple loss of their own teeth. In addition, there are demands for cost-efficient care in as few treatment sessions as possible. In the present case, an own concept from our practice with a special template technique for immediate restoration of the mandible after extraction of the teeth unsuitable for preservation is presented.

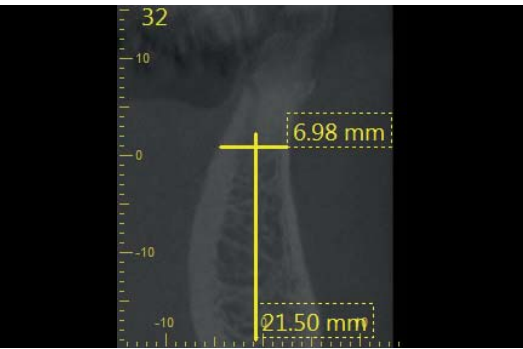
The reconstruction of edentulous jaws with implants through immediate restoration is a well-founded treatment option in geroprosthodontics [1]. Fixed, occlusally screw-retained bridges on four or more implants, a concept made popular by Professor Paolo Maló, are becoming increasingly favored by edentulous patients [2;3]. The prerequisite for immediate restoration is primary stable anchoring (30 Ncm) of at least three implants. In our practice concept we have integrated the therapy option of a fixed prosthetic reconstruction on at least four implants [4] and tried to reduce the treatment appointments to a minimum in accordance with the wishes of many patients. With the aid of a combined bite registration/impression tray, a long-term temporary restoration with immediate loading within 12 hours and/or a definitive composite bridge in the sense of early loading within 14 days [5] is possible due to the splinting of the impression posts. If a metal or all-ceramic restoration is desired, the final restoration is fabricated

after approximately three months of implant healing and healing of the soft tissue. If the primary stability on at least three implants is not 30 Ncm or other risk factors such as bruxism are present, the final prosthesis is not integrated until after the implant has healed. As the postoperative impression is taken with splinted impression posts, the master cast created can be used to fabricate both the temporary and the final denture.

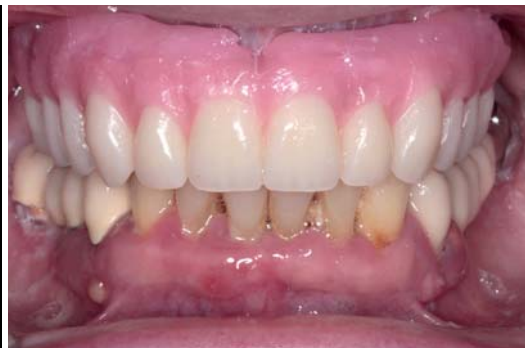### Case presentation, planning and decision on therapy

A 64-year-old female patient presented in our practice with a marginal periodontitis profunda and a prosthetically insufficiently restored set of dentures (**Fig. 1**). In a consultation regarding the therapy options for prosthetic restoration, she stated that she would only consider a fixed denture in the lower jaw. The upper jaw should first be treated with a new full denture and later also with implants. Despite being informed about the possibility of

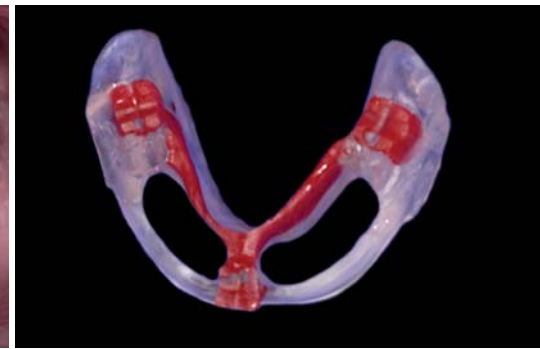
preserving most residual mandibular teeth (root canal treatment on 44, closed PA, open PA on all teeth with residual pockets > 4 mm, apical displacement flaps with osteoplasty on at least 34 and 35 and possibly regenerative PA treatment on 44 and 45), her wish was a purely implant-supported reconstruction, as she had lost confidence in her own teeth (**Fig. 2**). Being an anxious patient, she was looking for a therapy option to receive a definitive, fixed denture in as few sessions as possible. The patient stressed that she never wanted to leave the practice without teeth. To verify the possibility of immediate implant placement with immediate restoration, the patient decided to have a digital volume tomography and clarification of the three-dimensional bone offer performed during her first visit to our practice: A sufficient ridge width could be achieved by resection of the ridge. The bone height above the mental foramen was more than six millimeters (**Figs. 3 and 4**).



**Fig. 4:** The bone height above the mental foramen was more than six millimeters.



**Fig. 5:** Wax-up of the complete maxillary prosthesis to improve esthetics and function.



**Fig. 6:** The individual impression and bite registration tray created according to the snowshoe principle.

Due to the patient's wish for a definitive restoration as quickly as possible, the patient was recommended to have a fixed screw-retained implant solution on five implants. An occlusally screw-retained all-resin temporary bridge was to be inserted immediately after surgery. In the context of early loading, a definitive, occlusally screw-retained resin-veneered bridge with metal framework was to be inserted after approximately 14 days of removing the sutures.

### Preparation of the prosthetic surgical treatment (session 1 following the decision on therapy)

Initially, models in the centric condylar position (RCP) were required. For this purpose, the maxillary prosthesis was duplicated in a crystal-clear individual tray in the practice's own laboratory. After designing the margins this was used for taking a relining impression to fabricate the upper jaw master cast on which the new full maxillary prosthesis was to be fabricated. At the same time, an anterior tooth jig for RCP occlusion could be attached to the maxillary incisors of this transparent prosthesis. RCP occlusion was performed with GC-Bite Compound. Together with a mandibular alginate impression, this made it possible to assemble articulated models in RCP after the first treatment session (without wax wall fabrication and a further treatment appointment).

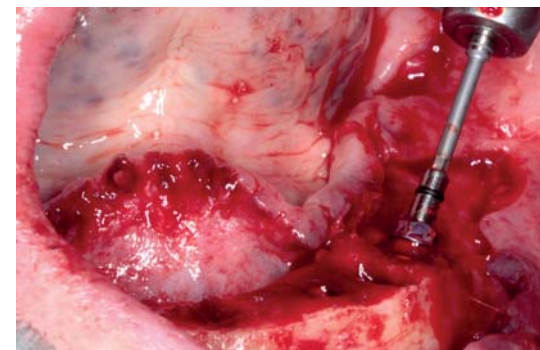
### Esthetic try-in (session 2 following the decision on therapy)

For esthetic and functional reasons, the upper jaw must first be ideally planned by means of wax-up, mock-up and/or wax setup (**Fig. 5**). For this reason, the maxillary prosthesis was placed on the maxillary master model according to functional and esthetic criteria. After wax try-in and checking static and dynamic occlusion (canine guidance), minimal esthetic corrections were made. Now the individual impression and bite registration tray for the surgical procedure could be fabricated (**Fig. 6**).

### Preimplantation measures in the laboratory

In the laboratory, the lower teeth of the situation model were removed. The lower jaw was set up versus the new maxillary wax-up. The finished maxillary prosthesis was additionally duplicated in a transparent prosthesis. Both prostheses therefore fit the same maxillary master cast. Then the individual impression/bite registration tray was fabricated. This corresponded to a duplicated mandibular prosthesis (**see Fig. 6**) with

- extended saddles (snowshoe principle) in regions 36 to 38 and 46 to 48,
- three deep colored bites in region 36, 31/41 and 46 as well as
- two chimneys in region 35 to 31 and 41 to 45 for the open impression of the implants.



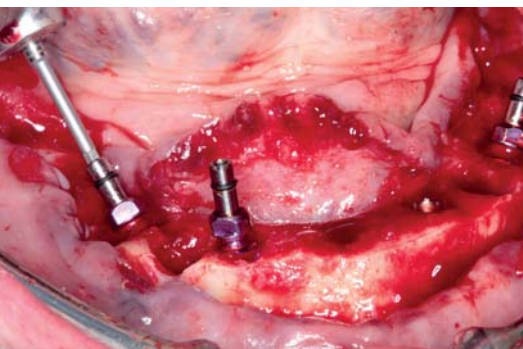
**Fig. 7:** Insertion of the distal implant in region 45/46 at an angle of 30°.

The deep colored bites were designed such, that they could be securely encrypted with the maxillary transparent prosthesis during bite registration. The snowshoe saddles in regions 38 to 36 and 46 to 48 serve only as a vertical stop for when the patient bites during simultaneous impression taking and bite registration. The COMFOUR® Titanium caps were coated with plastic in the laboratory for subsequent splinting in the mouth and the correspondingly long screws for the open impression were selected on the basis of the masticatory plane.

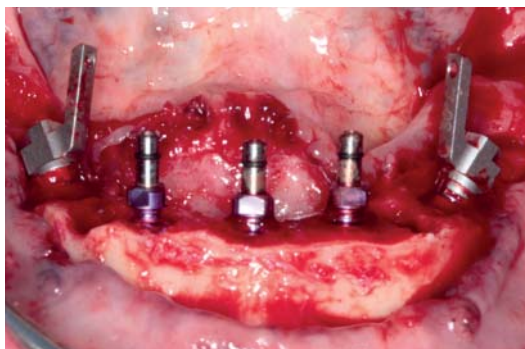
### Day of surgery (session 3 following the decision on therapy)

The surgical procedure was performed under intravenous sedation with Dormicum. First, the teeth were extracted and a full flap with distal relief incisions was prepared in regions 36 and 46. The alveolar bone was flattened to obtain a jaw bone width corresponding to the implant diameter. The enlargement of the loading polygon was achieved by the oblique (30 degrees) insertion (**Fig. 7**) of the two distal implants in regions 35 and 45 in the specified window of

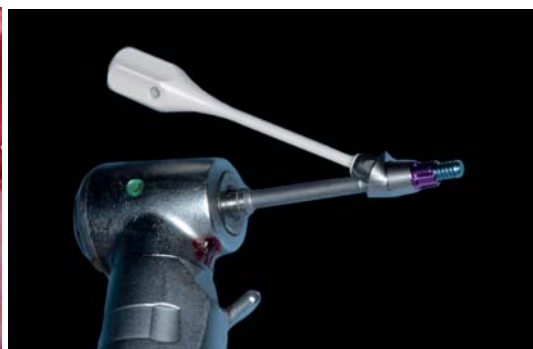



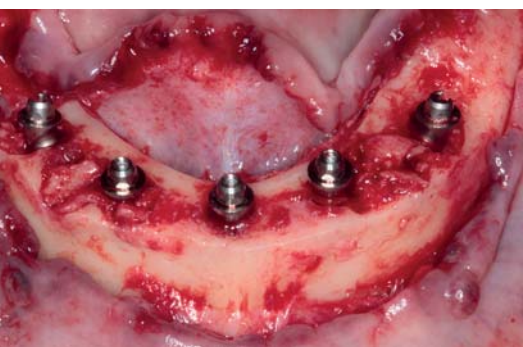
**Fig. 8:** The practice concept for immediate restoration includes an additional centrally placed implant.



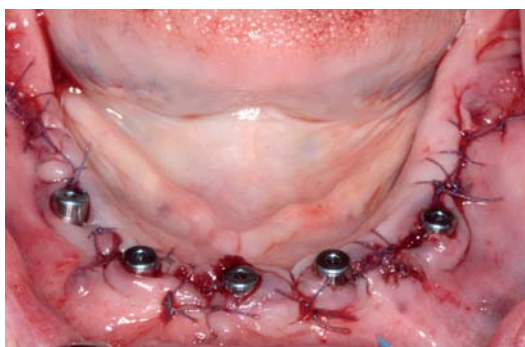**Fig. 9:** The aligning tool is used for optimal positioning of the angled COMFOUR® Abutments.



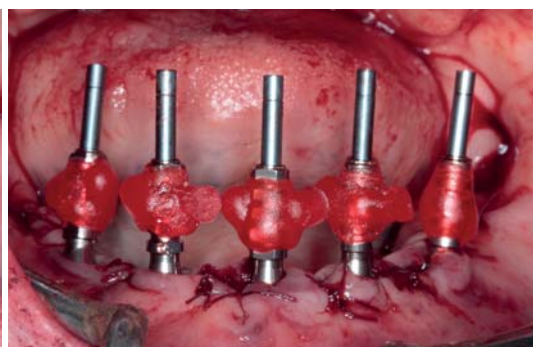
**Fig. 10:** The 30° angled CONELOG® COMFOUR® Abutment with the pre-assembled flexible handle.



**Fig. 14:** Three straight and two angled COMFOUR® Abutments were used.



**Fig. 15:** The soft tissue was sutured around the screw-retained gingiva formers.



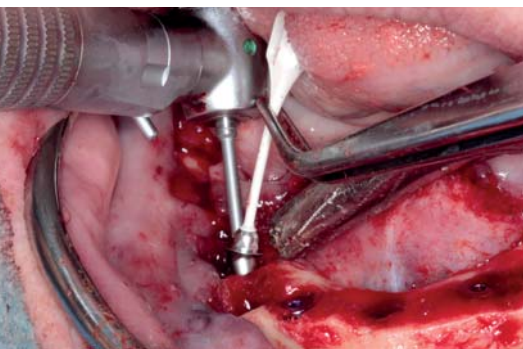
**Fig. 16:** The plastic-coated impression posts were screw-retained and the approximal contact freedom was checked.

the impression/bite registration tray. The COMFOUR® Aligning tools were used to check the direction of a groove in the CONELOG® inner connection in order to optimally position the angled COMFOUR® Abutments. The aligning tool also served the defined position of the screw access channel in the prosthesis (**Figs. 8 and 9**). Then one implant was placed centrally in region 31/41 and one implant each in regions 33 and 43. Straight COMFOUR® Abutments were screwed onto the anterior implants. All implants could be inserted with a primary stability greater than 30 Ncm. Using the flexible pre-mounted insertion aid, the 30° angled abutments were placed on the distal implants and screw-retained in the implant with the abutment screw and a defined torque of 20 (angled) and 30 Ncm (straight). (**Figs 10 to 14**). The healing caps were placed on the abutments and the mobilized mucoperiosteal flap was sutured tightly (**Fig. 15**). The healing caps were removed after completion of the suture, replaced by the plastic-coated titanium caps (impression posts) and tightened with 10 to 15 Ncm. A control X-ray image ensured the exact fit of the

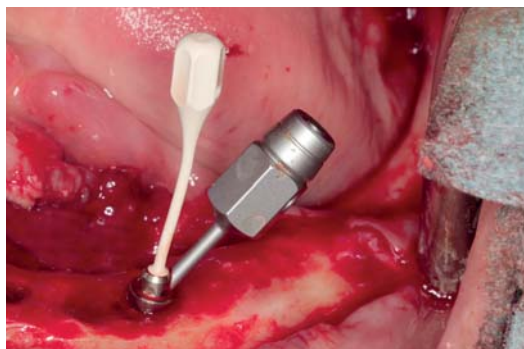
impression posts without trapping any parts of the mucosa (**Figs. 16 and 17**).

For impression taking, a rubber dam was cut out in a U-shape, disinfected and placed over the surgical field. The titanium caps were splinted with Pattern Resin to ensure a tension-free fit for the temporary and final restoration (**Fig. 18**). The duplicated, transparent maxillary prosthesis was inserted. Prior to impression taking/bite registration, the combined impression and bite registration tray of the mandible was checked. The mandibular tray had to be fixed securely to the maxillary transparent prosthesis with the colored bites and rest on the mucosa in the range of the 6 to 8 (vertical stop for bite registration) (**Fig. 19**). The opening and closing of the mouth for bite registration was practiced several times with the still partially sedated patient. Here, the clinician fixated the combined impression and bite registration tray together with the maxillary transparent prosthesis to the upper jaw with the left hand and guided the lower jaw with the impression posts in a jaw-locking movement to the vertical stops of region 38 to 36 and 46

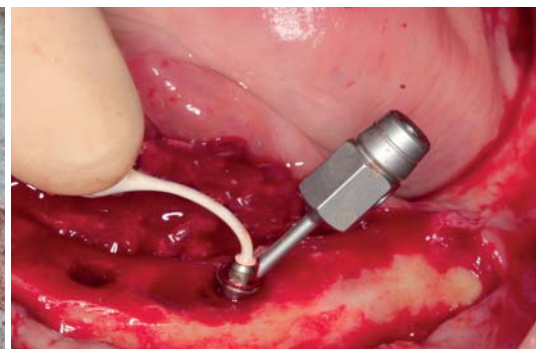
to 48 with the right hand (manual bite registration). Interference contacts of the impression posts on the maxillary transparent prosthesis could be removed liberally. The individual mandibular tray was now filled with impression material (Monopren/Kettenbach), placed on the maxillary transparent prosthesis and the patient guided into RCP with pressure-free hand bite registration. It is of utmost importance in this procedure that the lower jaw is not opened until the impression has set (**Fig. 20**). Therefore, good nasal breathing must be ensured before the procedure. After the impression material cured, the screws were cut free and unscrewed from the abutments. The impression tray was removed and checked: the splinted titanium caps were fixed in the material in a stable position and the tray in region 38 to 36 and 46 to 48 was pressed through evenly and thinly (**Fig. 21**). The COMFOUR® Healing caps were screw-retained again until the temporary restoration was inserted.



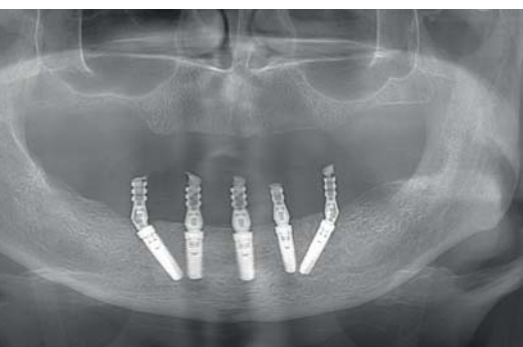
**Fig. 11:** The abutment was positioned with the aid of the handle.



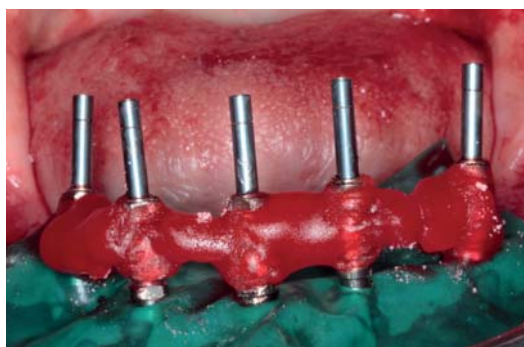
**Fig. 12:** The abutment screw was tightened with a hand screwdriver.



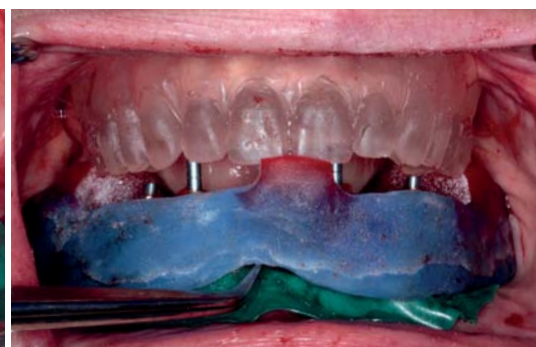
**Fig. 13:** The flexible handle was pushed to the side for better visibility.



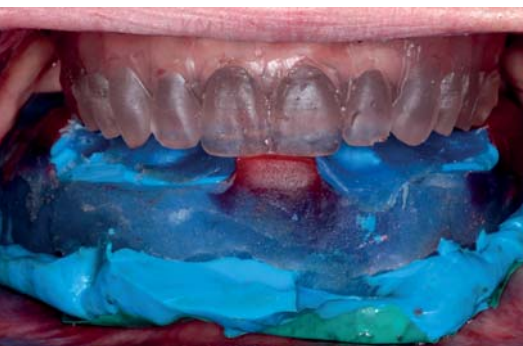**Fig. 17:** The control X-ray shows the screw-retained impression posts and the gingiva former on the central implant.



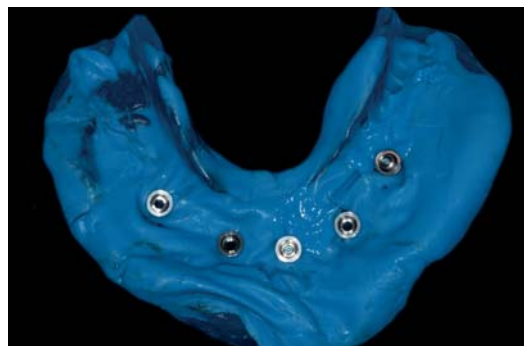
**Fig. 18:** The surgical site was covered with a rubber dam and the posts were splinted with plastic.



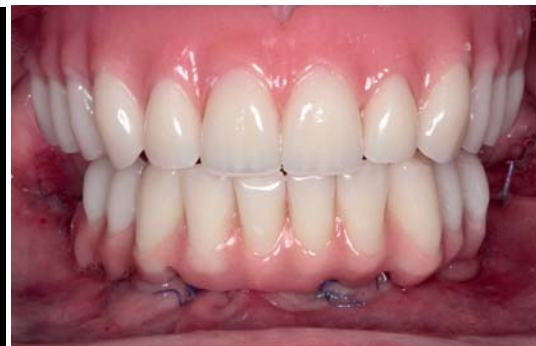**Fig. 19:** Before the impression was taken, it was checked that the long screws did not interfere with the bite into the plastic bite impression.



**Fig. 20:** The impression was taken with the combined tray. The bite relationship was confirmed by the bites.



**Fig. 21:** The mandibular impression: the "snowshoe pads" in the dorsal area are readily visible.



**Fig. 22:** 14 days after insertion, the definitive metal-plastic prosthesis was inserted and the sutures removed.

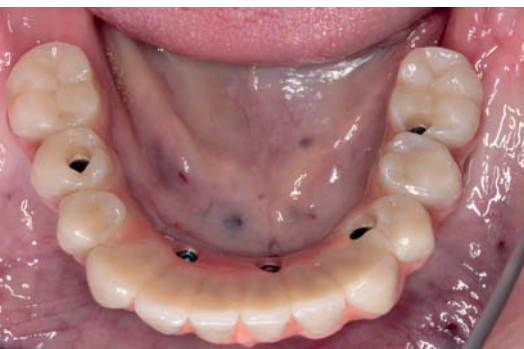### The fabrication of the temporary denture

In the laboratory, the mandibular master cast was fabricated by inserting the laboratory analogs into the titanium bases, fixing them with the prosthetic screws and filling the impression. Before the impression was taken from the cast, the technician articulated the model against the preoperatively fabricated full denture. Using a silicone index, the preoperatively

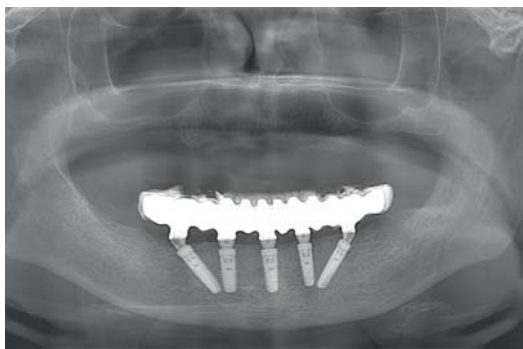determined ideal mandibular set-up was transferred from the situation or set-up model to the working model and then modeled in full. After a functional check, the all-plastic bridge over the titanium caps was fabricated using conventional techniques. During finishing, particular focus was placed on the basal design and good hygienic capability of the bridge construction ("cleaning supports").

A few hours after surgery, the temporary restoration could be incorporated (**Fig. 22**). The healing caps were removed under local anesthesia and the occlusally screw-retained temporary restoration was inserted with 15 Ncm. After the functional check and the provisional closure of the screw access channels, the patient was again informed that she should only chew carefully and eat soft foods.

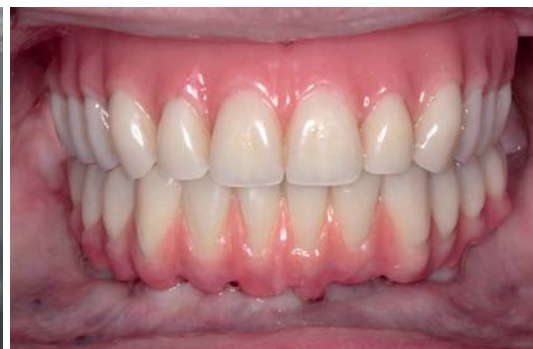



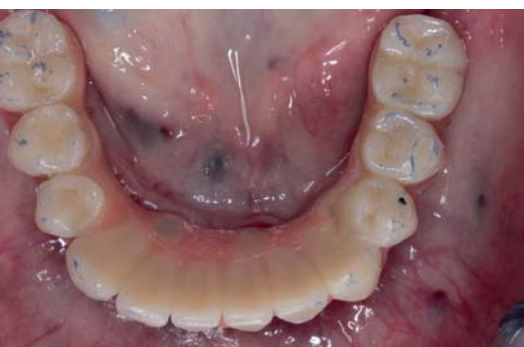**Fig. 23:** The inserted lower mandibular restoration from occlusal.



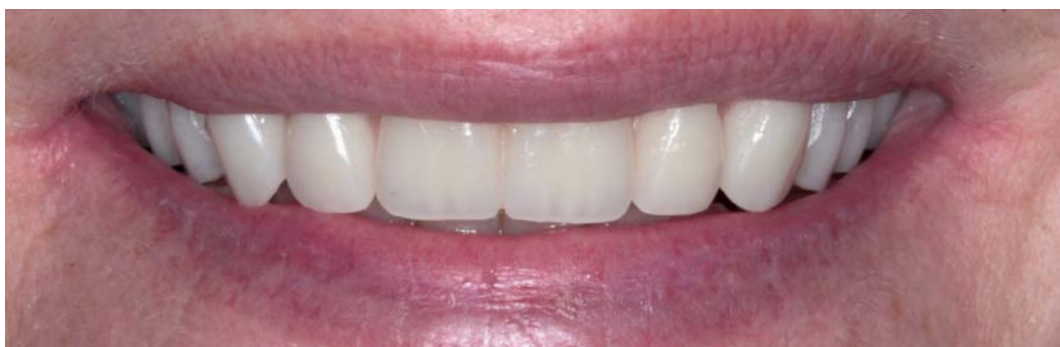**Fig. 24:** The X-ray control image with the definitively inserted restoration 14 days after surgery.



**Fig. 25:** Owing to the combined impression tray and exact bite registration, there is no need for reassembly.



**Fig. 26:** The occlusion check of the bridge after sealing the screw access channels.



**Fig. 27:** The final picture: satisfied patient, cost- and time-efficient treatment.

### Wound control and insertion of the final denture (sessions 4 and 5)

After a wound and bite check on the first postoperative day, the final metal-plastic bridge (15 Ncm) could be inserted together with the suture removal after 14 days. Due to the good bite situation on the one-day check, it was not necessary to take fine bite impressions on the metal framework before completion (**Figs. 23 to 27**).

After approximately three months, the patient received her first professional implant cleaning with removal of the twelve-pontic metal-reinforced plastic bridge. The abutments were checked and retightened to a full 30 Ncm. No bite correction through reassembly or relining of the bridge was necessary for the patient. The length of the bridge pontics and cleaning supports was chosen to allow a mucosa thickness of approx. 2-3 mm over the resected alveolar ridge. With epi- to subcrestal positioning of the implant shoulder and known abutment

height, this could be readily estimated by the dental technician. An evenly leveled alveolar ridge is advantageous for a good basal fit of the bridge (**see Figs. 14, 22 and 25**).

### Discussion

Definitively screw-retained bridges with composite veneers or acrylic teeth on four implants are less expensive and more patient-friendly than the removable cast model-reinforced reconstruction on four implants with bars or telescopes [2;3]. The All-on-X therapy concept is an excellent and cost-efficient alternative in my practice for many edentulous patients or patients with a hopeless residual dentition [6].

Appropriate implantological and prosthetic experience is a prerequisite for this type of treatment. In accordance with the Maló concept, a freehand implantation is performed in the region of the premolars and anterior teeth with full flap formation. A classic drilling template or navigation template is dispensed with.

This allows the clinician to adjust the implant position and axis within certain limits according to the intraoperative conditions, which can often change unplanned due to the immediately preceding extraction of teeth, granulation tissue and, if applicable, (apical) cysts. Intraoperatively, the surgeon has greater freedom to resort to a wider implant diameter if the primary stability is too low. This is more often the case in the upper jaw due to the lower bone quality. Therefore, the implant bed should always be under-prepared in the upper jaw and, if necessary, bone condensing should be performed, no tapping and, if applicable, no trial screwed insertion of the implants. The conical outer geometry of the CONELOG® Implants and the possibility of placing the CONELOG® Implants epicrestally up to 1 mm subcrestally facilitate the adjustment of good primary stability. An enormous advantage is the absolutely identical inner geometry and interchangeability of the abutments and titanium caps (for impression taking) of the CONELOG® Implants with 3.8 mm and 4.3 mm diameters. This allows a free choice

between these two implant diameters intraoperatively. This is a great advantage in the case of relevant intraoperative processes or necessary deviations from planning. In the rare case that a 5.0 mm implant is required for sufficient primary stability, this is kept available as a rescue implant together with a straight, a 17° and a 30° angled abutment.

If a fixed navigation template is used, a framework-free all-resin temporary restoration can be fabricated preoperatively. Whereby it should be noted that the implant cannot be screwed in deeper if primary stability is poor. This is one reason for the insertion of one or two additional implants. After the surgical procedure, the sleeves are screwed onto the abutments and polymerized intraorally in occlusion with the opposing jaw into the temporary restoration. Disadvantages of using navigation templates with preoperatively fabricated immediate temporary restorations are that the alveolar ridge cannot be leveled to achieve a correspondingly wide ridge, the implants cannot be set deeper with low primary stability and the angle of

the distal implants is limited to 30°. If all requirements for the navigation technique are met, then it is faster and easier to use.

A tension-free fit of the restoration is necessary to provide a high success rate with immediate loading. In the author's opinion, the splinting of the impression posts is therefore of great importance. Tension can also occur at the interface between the implant and abutment if the alveolar ridge distal to the angled implants is not sufficiently reduced and the abutment rests on the cortical bone. If the implants are angled more than 30°, this aspect must be taken into account.

We have been treating according to this concept in our practice for ten years, whereby in the early years only temporary all-plastic bridges were incorporated for the healing period. The absence of implant losses encouraged us to integrate definitive metal-plastic bridges after two weeks. If a metal or all-ceramic bridge is required, it is always fabricated after the implants have healed. For early restoration with a definitive bridge, relining is necessary in 2/3 of cases and reassembly

in less than 1/3 of cases after implant healing. Due to the precise impression technique, the original master casts can always be used for the reassembly or fabrication of the final denture. Owing to the high accuracy of bite registration with correct use of the described technique, with appropriate surgical and prosthetic experience, combined with the required primary stability of 30 Ncm, the final denture can be integrated as a so-called early restoration. According to the author's experience, controlling the torque with the torque wrench is completely sufficient.

## LITERATURE

[1] Ledermann, P., D.: Über 20-jährige Erfahrung mit der sofortigen funktionellen Belastung von Implantatstegen in der Regio interforaminalis. *Z Zahnärztl Implantol* 12, 123–136 (1996).

[2] Malo P, de Araujo Nobre M, Lopes A, Moss SM, Molina GJ. A longitudinal study of the survival of All-on-4 implants in the mandible with up to 10 years of follow-up. *J Am Dent Assoc* 2011;142:310–320.

[3] Maló P, Rangert B, Nobre M. „All-on-Four“ immediate-function concept with Brånemark System implants for completely edentulous mandibles: a retrospective clinical study. *Clin Implant Dent Relat Res*. 2003;5 Suppl 1:2-9

[4] Kern JS, Kern T, Wolfart S, Heussen N. A systematic review and meta-analysis of removable and fixed implant-supported prostheses in edentulous jaws: post-loading implant loss. *Clin Oral Implants Res*. 2016;27(2):174–95

[5] Weber HP, Morton D, Gallucci GO, Rocuzzo M, Cordaro L, Grutter L. Consensus statements and recommended clinical procedures regarding loading protocols. *Int J Oral Maxillofac Implants*. 2009;24 Suppl:180-3

[6] Babbush CA, Kanawati A, Kotsakis GA, Hinrichs JE. Patient-related and financial outcomes analysis of conventional full-arch rehabilitation versus the All-on-4 concept: a cohort study. *Implant Dent* 2014;23(2):218-24

## AUTHOR



### Contact details

Dr. Emmerich<sup>2</sup> and Colleagues  
 Dr. Dominik Emmerich  
 Specialist in oral surgery  
 Specialist for implant dentistry (BDIZ/EDI)  
 Specialist for dental prosthetics and biomaterials (DGPro)  
 Practice Clinic for Dentistry  
 Parkstraße 25  
 88212 Ravensburg  
 info@emmerich-emmerich.de

### Dr. Dominik Emmerich

Dr. Dominik Emmerich studied at the Albert-Ludwig-University Freiburg from 1994 and graduated in 1999. Until 2004 he worked as a scientific assistant in the Department of Dental Prosthetics under Professor Strub at the Klinikum Freiburg. In 2002, Dr. Emmerich received his doctorate on the topic of hard and soft tissue reactions on titanium implants. From 2004 to 2008 he worked in the Department of Oral and Maxillofacial Surgery at the University Hospital of Freiburg with Professor Schmelzeisen. After being appointed specialist for oral surgery and specialization in implant dentistry, he moved to the joint practice with Dr. Julia Emmerich in Ravensburg in 2008. Dr. Emmerich is a member of the New Group and the associations DGZMK, DGPro, DGI, BDO, BDIZ and EDI.





[www.camlog.com/future](http://www.camlog.com/future)



[www.camlog.com/trust](http://www.camlog.com/trust)

**100%  
camlog**



## 100% CAMLOG CAMPAIGN

WHY DOES EVERY 4TH IMPLANT IN GERMANY COME FROM CAMLOG?

One of four implants sold in Germany comes from CAMLOG. What are the reasons for this success? We believe that our customers and the CAMLOG team have one thing in particular in common: the high standard of everything we do. That is why our customers are exceptionally successful, and so are we. We try to realize this indispensable claim in all areas of life: for our family, friends, our passions and of course also for our profession. This deeply rooted attitude is the cornerstone of the trusting partnership with our customers. This creates mutual appreciation and pleasure in working together. Complementary competencies are a prerequisite – but that alone is not enough. The reason being that we want to achieve ambitious goals together. Because we are not satisfied with less than 100%. This is the core idea of the "100% CAMLOG campaign".

The sports worlds where we have translated the campaign into images and videos should be entertaining and illustrate this claim. Ice climbers can only master the ascent if they are able to assess the conditions correctly and can rely 100% on the precision of their equipment and rope team. The analogy to implant dentistry? The quality of ice is probably as difficult to assess as the quality of bone – for implant placement to be successful, a complex set of parameters must be optimally matched. The CAMLOG DNA, our perfect fit and the openness of our workflows form the basis from which one can start.

We have transferred the topics of partnership at eye level and team play into the world of formation jumping. Without perfect teamwork and trust, no formation can be formed in free fall. Sailing is an analogy to know-how, networks and

added value – because without strategy and expert support you cannot win a regatta. And would you go on a diving trip without scientific foundation and excellent quality? – Our customers pursue the same high standards in implant dentistry.

Let's be honest – assuming you were a passionate golfer and wanted to buy a new driver, would you choose an original of the highest quality? We think: yes.

**100% CAMLOG – you are in a better position with us.**



[www.camlog.com/momentum](http://www.camlog.com/momentum)



[www.camlog.com/freedom](http://www.camlog.com/freedom)



# YOU ARE IN A BETTER POSITION WITH US.



## GREETINGS FROM ROTTERDAM

The campaign was already integrated into the trade fair presentation at the OR Global Symposium in Rotterdam in the form of videos. In our on-site studio, some customers spontaneously gave their 100% CAMLOG video statement. The participants also had a lot of fun with the 100 % CAMLOG photo box.







## THE NEW MEDICAL DEVICE DIRECTIVE

2017/745 EEC

Now it is here, the new European directive for medical devices (MDD). But so far only a few companies know what efforts they have to make to implement the requirements of the new regulation and to be able to carry out CE labeling according to the new MDD.

It has been official since 25 May 2017: the new European Medical Devices Directive (MDD) has been published in the Official Journal of the EU. The Directive officially entered into force on 25 May 2017. After a transition period of three years, the Medical Device Directive is binding for all companies. In concrete terms, this means that from 26 May 2020, medical devices must comply with the requirements of the new MDD.

Small and medium-sized companies in particular will find it difficult to meet the significantly higher requirements for quality and risk management, technical documentation and the compilation of clinical data or clinical evaluation, while at the same time meeting the requirements for UDI labelling and increased reporting obligations. For example, the MDD requires periodical updates on Post-Market-Surveillance-Plans/Reports, Post-Market Clinical, Periodic-Safety-Update-Report, Summary of Safety and Clinical Performance.

The MDD requires the quality management system of the manufacturers to include comprehensive resource management, which must include the selection and control of suppliers and even their subcontractors. At the same time, authorities such as Notified Bodies (Notified Bodies are state-authorized bodies which – depending on the risk class of the medical devices – carry out tests and assessments as part of the conformity assessment to be carried out by the manufacturer and certify their correctness according to uniform assessment standards) are required to deal with suppliers to medical device manufacturers much more critically than has been customary up to now. As a result, manufacturers will have to impose stricter standards on their own suppliers and newly regulate contractual cooperation with suppliers comprehensively.

The time required to achieve CE labeling for new products will also increase from 1.5 to 3 years today to 6 to 8 years. This delay will also be reflected in the availability of innovations for patients. The costs for administration up to CE marking will increase accordingly. Presently one calculates € 0.5 to 1.0 millions for a high risk product, in the future we are looking at up to € 3 millions. Small and medium-sized enterprises will hardly be able to cope with more than one innovation

per year in this sector. In particular, the increased requirements placed on the authors and investigators of technical and clinical documents are likely to represent an enormous hurdle for many companies.

Conclusion: those who do not start implementing the requirements of the new MDD today, will ultimately find things difficult in the end. Many companies are already overtaxed. There is also a bottleneck with regard to the Notified Bodies, so that even companies that could afford this in terms of personnel and finances may encounter difficulties in implementation. The new MDD represents one of the biggest challenges of the past 20 years for manufacturers of medical devices.

CAMLOG has dealt with this topic at an early stage and initiated appropriate measures. At the sites in Wimsheim and Basle, a GAP audit by the TÜV Süd has already been conducted in order to identify weak points and new requirements and to be able to take the appropriate measures. CAMLOG/ALTATEC will be certified according to the new MDD in summer 2019.

**Just imagine working  
with CEREC® – and discovering  
an implant system that's  
a perfect match.**

iSy is the intelligent implant system: lean range, easy to handle and highly efficient. iSy has a particularly smart solution in store for CEREC® users: scan adapter and scanbody are simply snapped onto the pre-mounted implant base - no need for a screwdriver. This saves several work steps and you save time..

**Simply snap on, scan and save time - This is iSy. Convince yourself.**



Watch the  
movie now:



More information at [www.isy-implant.com/cerec](http://www.isy-implant.com/cerec)

CEREC® IS A REGISTERED TRADEMARK OF DENTSPLY SIRONA.

**This is**







## ALLTEC DENTAL IN AUSTRIA

INTERVIEW WITH ALEXANDER JIRKU AND PIERRE RAUSCHER

In Austria, CAMLOG products have been distributed by our partner Alltec Dental for many years. The company is one of the market leaders in the country. The multi-brand strategy was implemented in a similar way as in Germany. Alltec Dental GmbH has been part of the CAMLOG Group since October 2017 and can thus make greater use of the synergies. The logo editorial team spoke with Alexander Jirku, General Manager Austria and Switzerland since October 2017, and Pierre Rauscher, Sales Manager Austria.

### **Mr. Jirku, to what do you attribute the long-lasting success of Alltec Dental in Austria?**

We live our corporate values, for which every single employee in the team is responsible. These are our roots for stable growth. In addition to our high-quality medical devices as well as our farsightedness to respond to market changes, our employees are our guarantors of success and brand ambassadors. They are the ones who transfer this vitality to our customers. It is this team spirit, which we have been living since our foundation in 2001, that makes us successful. Our entire team is open and optimistic about the future. Right across the spectrum, be it analog or digital.

### **Is that why you were also involved in the "Spectrum" marketing campaign?**

We are permanently expanding our range of products and are constantly developing our service further. And the focus is always on customers and patient needs. They form the basis of our existence and for this we give 100 percent. The quality of the products and the trust are essential for a good and cooperative relationship with our customers. We have worked hard to achieve this over the last 17 years. In a market environment where suppliers' products are becoming increasingly similar, we distinguish ourselves through a large product portfolio, know-how and services, all from a single source. This is how we make our customers successful.

### **Mr. Rauscher, with DEDICAM, the CAD/CAM prosthetic solution, you are introducing novelties at a rapid pace. Where is the journey heading?**

Digitization has become an integral part of interdisciplinary dentistry, as it significantly changes work processes. The open interfaces enable our customers in the dental practice and laboratory to use their preferred systems in their daily work and to connect them in series. Customers without a CAD infrastructure can also benefit from DEDICAM, because highly qualified dental technicians design reconstructions on a model basis in the Scan & Design Service and then import them into CAM production. The implant planning service closes yet another gap

in the full digital workflow. Based on the DVT and DICOM data sent in, the guide specialists plan the implant positions in consultation with the customer. On request, the Service Center can produce printed surgical templates for guided surgery for all implant systems.

The prosthetic solutions are offered in various materials. The individual CAD/CAM full zirconium abutments for the two-piece CERALOG® Ceramic implant are in increasing demand.

### **In general terms, how high is the demand for ceramic implants in Austria?**

The market segment of ceramic implants is still very small. This use of the implants is still being discussed with great controversy in the country. However, due to the high esthetic demands and the increasing number of patients diagnosed with metal intolerances, demand will grow. CERALOG is a well-founded system. The first clinical studies with the one-piece monobloc in its current material composition started as early as 2007. The high-tech "ceramic injection molding" manufacturing process also convinces many users. The pure implant surface is the benefit for patients with intolerances. The two-piece CERALOG® Hexalobe has been in clinical use since 2013. The accumulated experience and successes give both the user and the patient security. We are more than satisfied with the development of CERALOG® Implants and their market acceptance.

### **You also market the BioHorizons biomaterials in Austria. How is this segment developing?**

In the USA, bone graft substitutes from the MinerOss® family and the Mem-Lok® membranes from BioHorizons are very well established. They are used by very renowned users and have proven themselves in the reconstruction of many bone defects in various indications. In internal and external training courses, we have constantly expanded our knowledge of the biological processes of bone regeneration. We are backed up by a CAMLOG team of specialists who support us and are available to give competent answers to any questions we may have. It is important for us that our customers in the interdisciplinary field of implant dentistry can obtain products from a single source and receive good professional advice.

### **Mr. Jirku, your customers benefit from the close cooperation with CAMLOG. Do you also offer cross-border courses?**

We offer our clients both national and international courses. They can participate in all CAMLOG events in Germany and Switzerland. The 2018 advanced training program offers a wide range of courses, lectures, specials and events for beginners, advanced users and specialists in the fields of oral implant dentistry and implant prosthetics.

The entrepreneurs' seminars for dentists, which are offered in cooperation with the

University of St. Gallen, the Swiss Institute for Small and Medium-Sized Enterprises, are something very special. The change of generations, i.e. the topic of handover and takeover, is discussed in detail in this series of seminars, as are management skills and the management of a company called Dental Practice as well as the appropriate practice concepts.

### **Where do you see yourself in the future?**

In the future, the implant industry will focus on sustainability and coordinated service concepts in particular. Together with CAMLOG, we will continue to proactively shape this path of interdisciplinary dentistry. We are embedded in a network, measure our own success, think ahead, promote innovation and are open to new ideas. Our objective is to gain further market shares for Alltec Dental/CAMLOG. In order to be able to implement the CAMLOG success model worldwide, the seamless transfer of know-how is crucial and targeted product development is indispensable. Our team will continue to work hard to prove the trust placed in us. At this point we would both like to thank the many colleagues who have helped us to be successful and who appear in the limelight far too rarely. Thank you very much. You're doing an excellent job!

### **Thank you for speaking to us.**







## AVOIDING LEADERSHIP ERRORS

### COMMUNICATING EFFECTIVELY AND MOTIVATING EMPLOYEES

In the last issues I devoted myself in detail to the topic of personality diagnostics. The better you know your own personality, the more individual, professional and easy it is to deal with employees. Only those who understand their own intrinsic motivation and values in toto can learn to understand and respond optimally to their employees. This individual communication is the key to successful leadership. Apart from this, it is nevertheless important to also avoid generally applicable management errors. I would like to highlight ten typical sources of errors in this article.

#### Error No. 1: Egalitarianism

A common mistake is wanting to treat all employees equally. In theory, this is a noble approach, but in practice it is counterproductive. Employees are not a homogenous collective, but people with different personalities. In the previous articles I had introduced effective tools, such as the Luxx Profile or the Reiss Motivation Profile, which analyze a person's personality at the deepest level. With the disclosure of the motives it becomes clear what an employee needs to work effectively or motivated, and also what you can rely on with the employee. For example, if you have an employee with a high curiosity value, he or she will probably be very interested in further training or will be happy to accompany you to congresses, while this is stressful for others. If an employee has a high value in terms of influence, status and ownership, salary increases, promotion opportunities or various benefits will be more effective than time off as compensation for overtime. Whether an employee is deployed in the right position can be recognized just as quickly. For example, persons with a low value in the area of social contacts or family have to invest considerably more time and effort for patient communication than employees with a high value. Individual assignment of tasks, clear limits and specific support are meaningful measures there.

#### TIPS:

- Use scientifically tested tools for personality diagnostics.
- Utilize the specific potentials of your employees.
- Support your employees individually.

#### Error no. 2: Blinkers

Those who operate in an ivory tower, so to speak, and are too focused on business affairs, often no longer learn what is happening at the grassroots level. Especially in a dental practice, where the distance between the protagonists could not be closer, it is important to stay in touch with the employee base. Otherwise problems or bad news will pass by undetected. Intervention is then not possible; any arising difficulties cannot be recognized. However, you need information about emerging problems to ensure the future of your practice. In addition, employees do not feel respected or valued when obvious problems or issues that concern them are overlooked. Do not expect employees to come to you voluntarily, it is your duty to obtain this information.

#### TIPS:

- Observe your employees and communicate if you notice certain verbal and non-verbal signals or if you see signs of overwork, frustration or sadness.
- Make it a habit to talk more with your employees. You can also find out what burdens your staff in serious small talk, during a shared lunch or between treatments.
- Invest in the ability to listen. You know your own opinion very well, but it is important to know that of your employees.

#### Error No. 3: Little praise, little feedback

As you have already learned from the previous articles, the personality structure is responsible for the extent to which an employee longs for recognition and, as a matter of course, also praise from the boss. People with a very high recognition value obtain their positive self-image exclusively from the feedback of others. These people are therefore extremely vulnerable. Everything is carefully registered and inwardly evaluated, which in the logical consequence is exhausting for the remaining team and the supervisor. There simply can't be enough praise here! Persons with a low expression are rather irritated by too much good feedback, since they already carry their positive self-image within them. They themselves hardly praise, appear self-confident and distant. An important question would therefore be what your and your employees' characteristics are. Regardless of the personality structure, however, a culture of praise should permeate every practice, because employees need feedback in order to be able to orientate themselves.

#### TIPS:

- Check your own attitude to praise and appreciation. Have beliefs established themselves, such as "she already knows that I value her work", "too much praise only goes to her head", "nothing said is enough praise", "that's what she is paid for after all", "she knows herself that she works well" etc.
- List the activities and skills of your employees that you value in your mind. You will be surprised at how many positive things are often overlooked.



- Avoid generalizing statements such as "you have done that well", but instead be concrete. What exactly did you like? Why was the performance particularly good? What made the difference? The employee not only feels strengthened, but also receives instructions for future behavior and knows what is important to you and what you want.
- Give constructive feedback – frequency depending on the occasion and personality of the employees.

#### **Error 4: Avoiding conflicts**

Conflicts – even with the best knowledge of one's own personality – are not necessarily avoidable. The old adage "It takes two to tango" is not only absurd, but also unfair, since it attributes a partial guilt per se to both partners. Arguing, causing unrest, being unfair or behaving dishonestly can also be done by one person alone. The question then is how to deal with the emerging conflict. It is often overshadowed by silence because it is feared that it could cost too much energy or become very unpleasant to openly

resolve the conflict or, in the worst case, that separation would be the only logical consequence. But if important facts are not discussed, discontent, uncertainty or frustration will arise. The associated loss of trust hampers good cooperation and productivity. Everything we deny because it's unpleasant inevitably creates distance. Conflicts that are not resolved tend to linger. The opposing fronts inwardly harden more and more, the atmosphere is gradually poisoned. The longer an unresolved conflict lasts, the harder or even impossible it becomes to restore a normal relationship or atmosphere.



Conflicts are never resolved by:

- Negation: "if we are honest, we do not have a problem at all..."
- Trivialization: "Well, it's not really that bad ..."
- Contradiction: "Oh, it's not that dramatic!"
- Irony: "And that annoys you?"
- Insult: "Well, if that already upsets you..."
- Not taking it seriously: "I don't know what's eating you ..."
- Overhearing: "Yes, yes, there are many things that could go better..."

#### TIPS:

- Take emerging conflicts seriously.
- Address conflicts openly.
- Invite only those involved.
- Ask them to join in a quiet, objective discussion.
- Create an undisturbed setting.
- Prepare yourself well for the meeting.

### Error 5: Conducting conflict talks poorly

It is not only crucial that conflict discussions are conducted or moderated, but in particular how they are conducted. Poor discussions worsen conflicts and escalate them. This can result in demotivation or internal resignation.

#### TIPS:

- Share the point of criticism without prejudice and be polite.
- Clearly state the mutual objective.
- Ask everyone involved to remain objective and calm.
- Give everyone involved enough time to express themselves.
- Ask employees to explain their point of view. How did the problem arise? Often, the cause is different than expected. In this case, your expectations will also change.
- Tell the employee politely and clearly what you expect from him/her.
- Ask the other participants what effect the colleague's statement has on them.
- Coaching question: "What did you do to let it get this far?"
- Do not demand a solution.
- Let the participants work out their own solutions.
- Make sure that all participants have an equal say. If necessary, stop

stronger verbal employees to let other people's voices be heard.

- Clarify whether your support is desired.
- Record the results and check that they will be implemented in the future – as agreed.

### Error No. 6: Unclear delegation

Assigning tasks and responsibility is an important part of good leadership. Often, however, misunderstandings arise because instructions are not clearly stated. If one does not know what is expected, one acts intuitively at one's own discretion, and this does not necessarily have to be correct.

#### TIPS:

- Clarify for yourself what you expect from your employee, in what way and in what period of time.
- Take your time for delegation.
- Explain tasks exactly; what is important to you and why.
- Ask the employee if there are any ambiguities.
- Summarize the key points of the task.
- For complex tasks, you can ask the employee to write a summary or checklist.

### Error 7: Control mania

Control is good and important, but it should not exceed beyond a certain level. When a task is delegated, a target agreement should always be discussed. Too much control destroys trust, snubs, demotivates and takes the fun out of taking on a task. If supervisors tend towards strong control, this is usually due to fear, insecurity, bad experience or because a feeling of losing control is inherent. In these cases, the origin is based on the personality structure and should then be questioned.

#### TIPS:

- Check your attitude to delegation.
- Check whether this is related to your past or to the employee.
- Set clear goals as well as when and how you want to be informed to ensure you get the feedback you want.

### Error No. 8: Lack of information

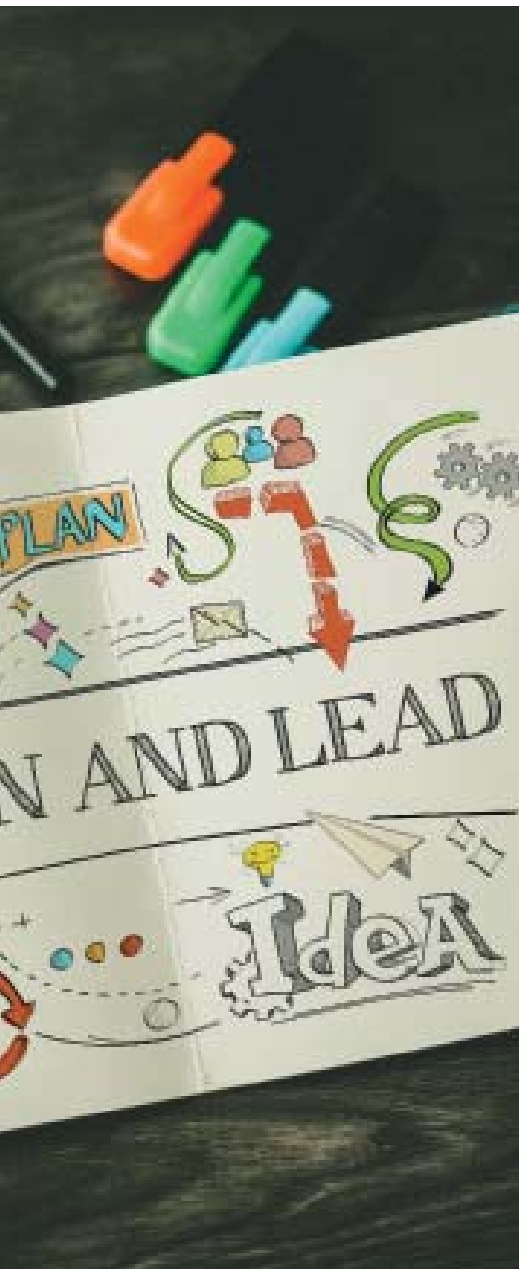Lack of time or the view that not every employee needs to know everything is often the reason why employees are not sufficiently informed. Of course, it is important to select who must be informed when and how. This requires a sensitive approach. It should be checked what is of general or special interest, because information deficits have many disadvantages and are usually accompanied by a negative state of mind. You quickly get the feeling that you are excluded or that information is deliberately concealed. Uncertainty, loss of confidence, discomfort, fear and stress are the physiological consequences. It is often ignored that a lack of information usually leads to a large time investment,



since the employees then exchange information with each other more intensively. Lack of information should therefore be avoided, as it not only has an economic impact, but also a long-term impact on motivation.

**TIPS:**

- Institutionalize employee meetings (jour fix).
- Even in small practices, a jour fix should not be conducted as required, but in a defined time frame.
- Set these dates with adequate time allocation and during working hours.
- Decide together at the jour fix, which information should flow to whom.
- Introduce a management round at a large practice to discuss important information in a small circle.



- Depending on the size of the practice, provide communication tools such as a notice board, practice manual, information sheets or an Intranet.

**Error No. 9: "Yes, but..."**

When an employee approaches his/her supervisor with a concern, there is hardly a phrase that is more demotivating than "Yes, but...". If employees want to submit ideas, point out shortcomings or point out deficits or potential for improvement and then receive a "yes, but..." in return, they will not bother a second time. The feeling of not being heard or not being taken seriously hits many employees hard. The logical consequence is that the employee withdraws and you will no longer hear about internal problems, difficulties, personal issues, bad news or optimizations. In the worst case the motivation to work decreases or may even result in inner resignation.

**TIPS:**

- Save time and space when an employee approaches you with a request.
- If you do not have time, you should nevertheless show interest and suggest a date to discuss the matter in peace.
- Even if you don't share the employee's views, it shows you how he/she thinks and feels. Appreciate this openness, because it gives you room for maneuver and shows trust.

**Error No. 10: Having no time**

As a rule, a manager devotes only 15 percent of the time budget to the employees. As a dentist, however, you are not only the boss, but also an expert or specialist, manager, team developer, motivator and even CEO, CFO, buyer, marketing manager, HR manager and much more, so that there is usually relatively little time left for the employees in dental practices. Add to this the feeling that one spends the whole day with the employees. Unfortunately, however, there is often not enough time for a qualitative exchange, which in turn makes cooperation more difficult. Frustration then quickly arises on both sides. This makes it all the more important to invest in the human resources of the practice!

**TIPS:**

- Check where you can restructure. What is ineffective? What can be delegated? Where is time being wasted?
- Prepare yourself well for appraisal reviews. Although this takes time in advance, it has a positive effect on efficiency and also signals appreciation to the employee.
- Define fixed times during which you have an open ear for your staff.

This condensed presentation already shows how many errors sometimes creep in unconsciously in everyday working life and what – often unimagined – effects this can have. Avoiding mistakes alone does not constitute good leadership; however, it provides a solid basis for a respectful and appreciative approach in everyday working life.

From a system-oriented point of view, superordinate elements are responsible for a benevolent coexistence. For this reason, I would like to devote the next issue to the topic of "unwritten laws in teams".



Andrea Stix, M.Sc., MBA  
Consultant for Communication Strategy and Practice Marketing  
Coach, NLP-Master, Specialist for personality diagnostics



# NEXT GENERATION



## HELLO FUTURE, WE'RE COMING!

As a mocker rightly pointed out, forecasts are difficult to make mainly because they concern the future... CAMLOG therefore does not even want to try looking into the fog of a crystal ball or read coffee grounds, but rather to take up the cause of well-founded optimism.

The intricate interlocking of yesterday and tomorrow can be debated for a long time, or presented in a picture like Schiller: "Time changes – and new life blooms from the ruins". CAMLOG once formulated this profound statement from old, which forms the breeding ground for the future in its passing, in connection with the company's history and a series of further training courses successfully conducted some time ago as follows: "Future needs origin". In ancient Rome, the god Janus, who had two faces to meet this challenge, was responsible for this two-way view of human existence.

### Society is changing

There is no need to lay cards to realize that the baby boomer generation is gradually withdrawing from working life and Generation Y is gradually taking over. What drives the Y-generation, what is important to them, what less important? ZEIT Campus, the online version of ZEIT, once described Generation Y very aptly in December 2016: "They grew up with Helmut Kohl as permanent chancellor; on their way on holiday, their parents battled

with roadmaps on their lap in the front of the car; they waited for days until their photos were developed, were banned from sandboxes in Chernobyl, recorded songs from the radio with cassette recorders; they knew their friends' telephone numbers by heart, watched Jurassic Park and Forrest Gump in the cinema – and The Silence of the Lambs secretly on video."

### Generation Y

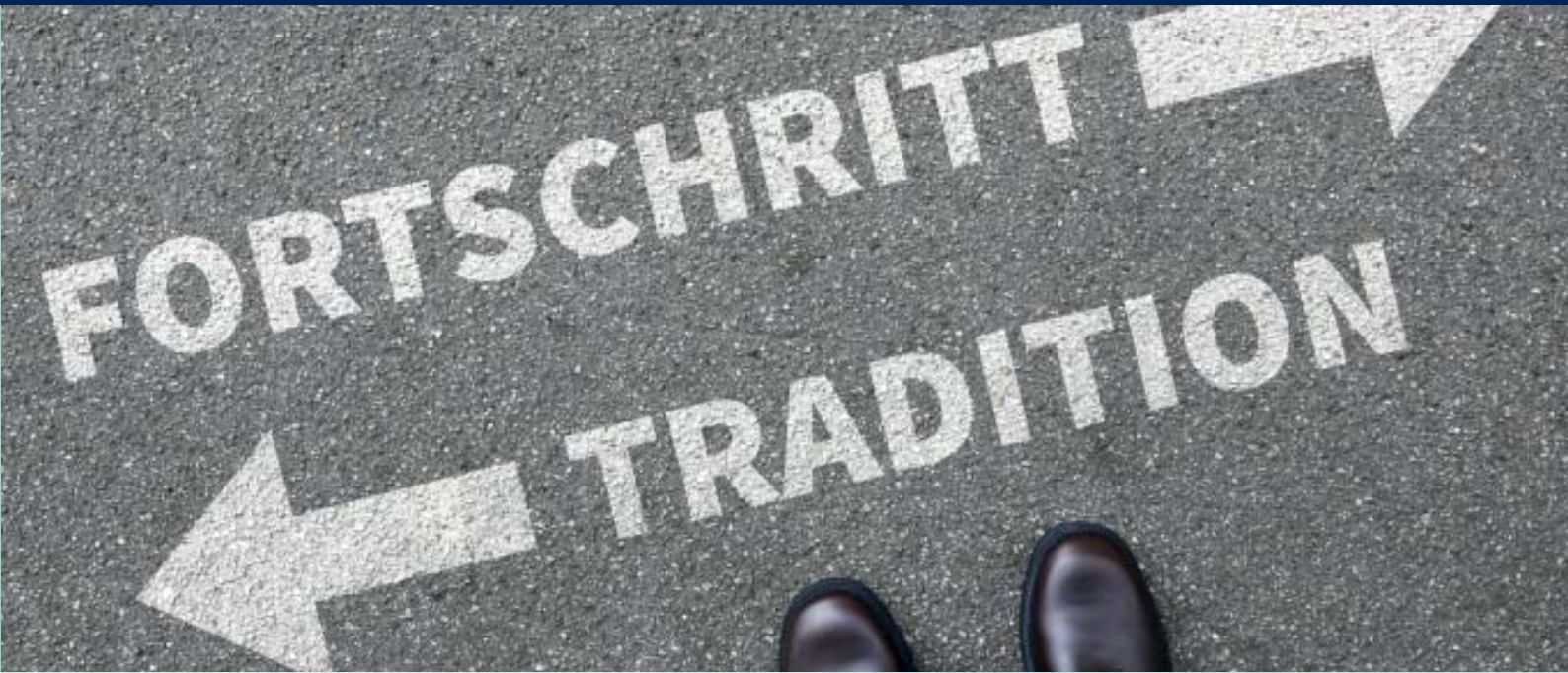In contrast to the baby boomers, who in part related to the '68, the Y Generation no longer dreams of revolutionary fantasies or opting out, but instead, stands with both feet on the ground and, for example, ponders on how stress can be reduced, writes DIE ZEIT. Or they try to implement their specific ideas of equality in their daily work. That they occasionally fall short of their own expectations – no question about it; there are setbacks and relapses into old role models – is a part of this. But the wishes of the majority of these ten million people are clear. The more of them who climb the professional ladder, the stronger their influence will become. And the more they can do to

narrow the gap between ideals and reality. Even pragmatists not only want to be just satisfied, but also happy; which lets them shake hands with the 68ers.

### The example of implant dentistry

Many years ago there were some daredevil dentists who had a dashing idea: Their adventurous plan was to replace missing teeth with bone plugs – would you believe it! This therapy, which at first was met with deep suspicion, has now become as futuristic as smartphones and the Internet. Against this background, dental implant dentistry seems to us to be an excellent example of a generation change in which proven methods have been adopted, pragmatically combined with visionary ideas and brought to sustainable success.

While generations of dentists held the drill in their hands and tried to stop tooth decay and, as tireless lone fighters, placed amalgam filling after amalgam filling, today's practices are increasingly developing into networked service bases in a digital workflow whose cybernetic loops generate increased patient benefits.



Does that (still) sound futuristic to you? Even if it did – the fact that communication today takes place via social networks and that you, as the person responsible for the practice, as well as your team, your therapy offers and successes and your industry partners are "rated and liked" on the web, is not a dream of the future, but reality! These technologies are unstoppable – and open up enormous potential if they are made available for customized practice marketing!

### **You'll never walk alone**

Whatever the future may bring, CAMLOG will be at your side, because the fundamental conviction of partnership has remained unchanged despite all the changes.



Jan Peters  
Writer Kaiseraugst/Switzerland