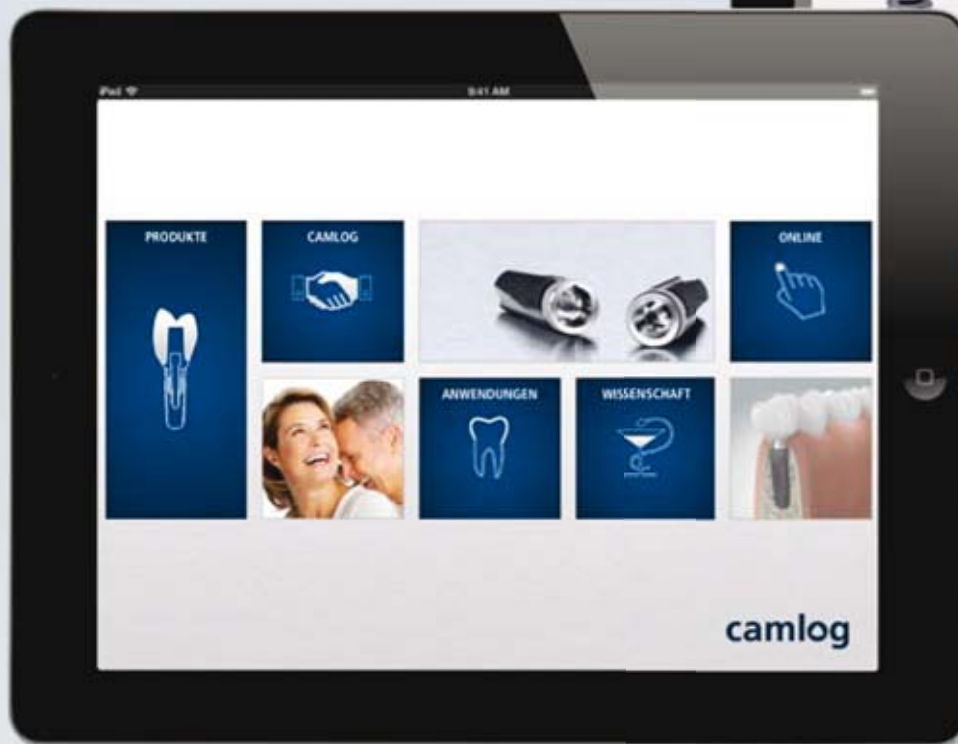


Special Edition

# logo

ISSUE 4 | 2012  
CAMLOG Partner Magazine



**THE NEW CAMLOG APP FOR THE  
LATEST INFORMATION**



## **TAP BY TAP ALWAYS WELL-INFORMED**

Mobile end devices have long since found their way into the dental practice and for good reason. They inspire through technology and design and provide effective support in many work situations on demand. But there is more to it than just the end device: The right app makes all the difference! CAMLOG has developed an app that has it all; information about products, application and science make patient education, treatment planning and many processes in the organization a pleasure.

According to recent studies, the Apple iPad is particularly popular among doctors. About one third are already using one and the trend is only increasing. Its almost unlimited mobility makes the tablet unbeatable compared to a laptop or monitor permanently installed on the treatment unit. The smart tablet accompanies the doctor from treatment room to treatment room and makes a much more personal experience possible for the patient than its predecessor.

And the desire for a stable system may be the motivation for some practice owners. So for us, the decision for an iOS app was easy. The elegant design of the tablets fits perfectly with the design of the CAMLOG app designed according to the principle "form follows function". This makes the app flexible and customizable in anticipation of future requirements.

Clean lines and clearly-arranged navigation make getting around the app simple.

Intuitive user interface, integration of typical Apple gestures and functions, as well as a good "flow" were also important parameters in developing the app like the capability of providing all relevant information in one application.



## The advantage lies in the hands

The result is clear to see and experience. The look & feel of the app make it an unmistakable CAMLOG tool – and wanting more. If you've ever gotten a hold of it, you may never want to put it down. Every tap provides the right content to best support dentists in their work.

The main focus is on the products and all information about their practical application. Tapping on the Product section provides access to information about the CAMLOG® and CONELOG® implant lines. The blue-gray double icon provides a clear view of all aspects important in making a decision for a suitable implant system and zeros in on the point: two implant systems – one surgical solution! The detailed view explains the product features and key benefits for the user in a straightforward, concise manner. The respective catalog with complete product details is in the immediate vicinity.



**CAMLOG Prosthetics**  
The complete prosthetic portfolio for a multitude of indications ...

**Tube-in-Tube™-connection**  
The very heart: The reliable, patented connection ...

**CAMLOG Implantate**  
CAMLOG implants – leading for years, proven more than a million times ...

**CONELOG Prosthetics**  
The proven portfolio with integrated platform switching ...

**Conical connection**  
The first-class, impressive conical connection ...

**CONELOG implants**  
CONELOG implants – the alternative with conical connection ...

**SURFACE**  
Proven by long-term success: The Promote® surface ...

**OUTER GEOMETRY**  
Two systems, one outer geometry, one set of instruments ...

**SURGERY**  
Consistently thought-out set of instruments: Easy handling ...

**CAMLOG® Tube-in-Tube™ Verbindung**

Die Herzstück des CAMLOG® Implantatensystems ist die international geübteste Tube-in-Tube™ Implantat-Abstimm-Verbindung. Das besondere geometrische Prinzip mit der die Tüben-Tüben- und die Plattform der Verbindung verbindet in einer hohen Positionierungsgenauigkeit bei optimaler Kraft- und Moment-Verbindung zwischen den einzelnen Komponenten.

**Einige Vorteile auf einen Blick**

- Das universelle, herstellereigene, einzigartige Interface
- Maximale prothetische Vielseitigkeit
- Herstellung aus dem besten Material und bei höchsten Standards
- Keine Lücken und sichere Abstützung
- Herstellung aus dem hochwertigsten Material
- Herstellung aus dem hochwertigsten Material

**Die Promote® Oberfläche**

Die gezielte, körnig-poröse Promote®-Oberfläche ermöglicht dem neuartigen Stand der Wissenschaft für ein bestmögliches Ergebnis eine rasche Osseointegration. Wissenschaftliche Resultate aus Zellkulturen, Tier- und klinischen Studien dokumentieren dies eindeutig.

**Einige Vorteile auf einen Blick**

- Einzigartig, langzeitproven, Oberfläche für optimale Osseointegration
- Erhöhter mechanischer Widerstand
- Erhöhter mechanischer Widerstand
- Erhöhter mechanischer Widerstand

**Aussengeometrie**

CAMLOG® und CONELOG® CONELOG® Implantate teilen in ihrer Gesamtheit kinematische Schnittstellen. Die Kinematik des Implantatensystems von 7°, 10° und 15° ermöglicht es, einsetzbar zu sein und das Instrumentenverzeichnis zu erweitern. Die bei der Einbringung der Implantate in Kombination mit dem selbstschließenden Gewinde kann eine hohe Präzision erreicht werden.

**Einige Vorteile auf einen Blick**

- Einzigartig, langzeitproven, Oberfläche für optimale Osseointegration
- Erhöhter mechanischer Widerstand
- Erhöhter mechanischer Widerstand
- Erhöhter mechanischer Widerstand

**Chirurgie**

CAMLOG® und CONELOG® Implantate teilen in ihrer Gesamtheit kinematische Schnittstellen. Die Kinematik des Implantatensystems von 7°, 10° und 15° ermöglicht es, einsetzbar zu sein und das Instrumentenverzeichnis zu erweitern. Die bei der Einbringung der Implantate in Kombination mit dem selbstschließenden Gewinde kann eine hohe Präzision erreicht werden.

**Einige Vorteile auf einen Blick**

- Einzigartig, langzeitproven, Oberfläche für optimale Osseointegration
- Erhöhter mechanischer Widerstand
- Erhöhter mechanischer Widerstand
- Erhöhter mechanischer Widerstand

**Die konische CONELOG® Verbindung**

CONELOG® Implantate sind mit einem 7,5° Winkel zur vertikalen Achse. Die kinematische Verbindung und den bei bestimmten CAMLOG® Systemen zur optimalen Abstützung dienende, das konische Einsetzen des Abstrahers ist über die Necken nach dem Einsetzen zu realisieren.

**Einige Vorteile auf einen Blick**

- Einzigartig, langzeitproven, Oberfläche für optimale Osseointegration
- Erhöhter mechanischer Widerstand
- Erhöhter mechanischer Widerstand
- Erhöhter mechanischer Widerstand

### Consistently user-oriented

That is CAMLOG's credo in developing products and services. Of course, it was also our maxim for the app. The intention of the tool is to ensure that you always have the right and current information at hand. Gone are the days when you rummaged around endlessly in shelves and cabinets or your own document folder for the work instructions or instructions for use that more often than not turned out to be hopelessly outdated if you found them at all. The app not only makes this all so much faster and more convenient, but also significantly more eco- and resource-friendly in the age of the "paperless office". By downloading the app from the App Store, you automatically have all current digital and print media at

hand. The intuitive menu makes finding the required information fast and easy. Catalogs, work instructions and case reports are organized thematically for each implant system in Surgery and Prosthetics sections, giving the user a clear overview despite the wealth of information provided. Interesting studies and summaries complement the expertise through condensed knowledge from practice. Of course, the E-Learning section has to be included. CAMLOG also just recently began offering highly informative webinars with renowned speakers. You can find presentations and tutorials in the "Video" section that show how CAMLOG products are used in application directly. The app is also well-suited for self-directed, location- and time-independent continuing education, which is enjoying increased demand.

Many other practical features such as favorites selection, search functions and direct links to interesting websites give the tool versatility. From the Settings menu, all documents can be downloaded in a single process, making them available online and offline. The benefits of mobility are thus maximized. A particular highlight is the "My CAMLOG Area" where you'll find something very special; easily integrate your own documents by synchronization from your Dropbox folder. You then have access to what you need – always and everywhere.

### Well-informed directly from the source

Get CAMLOG news with all its services directly from the source. In the CAMLOG section, the news ticker keeps you up-to-date, and in the course program, you find exciting suggestions for seminars and events to keep yourself and your team abreast of treatment and practice management. All kinds of interesting information about the company is also available.

And as CAMLOG is constantly trying to improve, so will the CAMLOG app be continuously further developed.



Dropbox QR code:



#### What is "Dropbox"?

"Dropbox" is an online service that lets you save files in a central location that you want to access from anywhere. It can be very practical, for example, to save photos from your own smartphone in a folder that you can access on your PC at home. You can also save documents in a Dropbox folder and share access to anyone you want. No more unwieldy e-mail attachments, USB sticks or CDs – you can give anyone access to your files by simply sharing the respective folder. Dropbox offers 2 GB of storage free and additional storage is available for a fee. Details are available at:

[www.dropbox.com](http://www.dropbox.com)

# IMPLANTS IN PATIENTS UNDERGOING BISPHOSPHONATE THERAPY



A. Spanou, K. Nelson, P. Voss /// Department of Dentistry, Oral and Maxillofacial Surgery  
Hospital for Oral-Maxillofacial and Plastic Surgery, Hugstetter Str. 55, 79106 Freiburg, Germany

Bisphosphonates (BP) have been used increasingly since the 1980s in patients with osteoporosis, multiple myeloma, breast or prostate cancer.

The active mechanisms of bisphosphonates on the various cells in the body are not yet fully understood. However, it is known that bisphosphonates inhibit the activity and differentiation of osteoclasts leading to programmed cell death. An antiangiogenic effect of bisphosphonates is also being discussed. The complex effect of this group of drugs results in an overall reduction in "bone remodeling". The biological half-life of bisphosphonates varies between a few months and years and shows individual fluctuations (7, 8, 16, 43).

With an overall low side effect profile, bisphosphonate-associated osteonecrosis (BP-ONJ) is of particular importance. The incidence of BP-ONJ is estimated at 1% to 19% for patients under i.v. BP therapy and at 0.1–0.2% for patients taking oral medication (22, 44, 45). The risk of BP-ONJ increases as the bisphosphonate dose increases over the course of treatment, as the age of the patient increases (over 65 years of age), the existence of chronic periodontitis, for cigarette smokers or concomitant corticosteroid therapy and for patients suffering from diabetes mellitus (37, 41).

PubMed (<http://www.ncbi.nlm.nih.gov/pubmed>) conducted a search of the literature using the following keywords: bisphosphonates & dental implants, jaw

necrosis and bone. 44 publications were identified dealing with dental implants in patients taking BP medication. These publications are found in the list of literature (1–44). All publications have been analyzed and are summarized in Table 1.

Most of the studies named have a low level of evidence of 4 or 5 [Table 2]. Randomized clinical trials (RCT) are missing completely. The sample sizes, length of the study and study parameters are usually inadequate to identify the possible emergence of BP-ONJ or to assess long-term effects.

Of critical importance in preventing BP-ONJ are the surgical procedure and the preoperative conditions in oral surgery, which include:

Table 1:

Author, year	Study design	No. of patients (BP/Control)	No. of implants	BP preparation, form of application, dose	Duration BP therapy	Observation period (months)	Significant findings			
							Implant loss	BP-ONJ	Implant Success rate of BP group (%)	Implant Success rate Control (%)
Jeffcoat 2006 [1]	Prospective Study Level of evidence 4	25/25	102/108	Alendronate Risedronate Oral	3 years	36	0	0	100	99.2
Fugazzotto 2007 [18]	Prospective Study Level of evidence 4	61	169	Alendronate (70 mg/week) Risedronate (35 mg/week) Oral	Ø 3.3 years	12 – 24	0	1	100	-
Bell 2008 [12]	Prospective Study Level of evidence 4	42 /NA	100/737	Alendronate Risedronate Ibandronate Oral	6 months – 11 years	Ø 36	5/NA	0	95	96,5
Grant 2008 [14]	Retrospective Analysis, case series, Level of evidence 2	115/343	468 1450	Alendronate Risedronate Ibandronate Oral	38 months	48	2/14	0	99,6	99
Kasai 2009 [5]	Prospective Study Level of evidence 4	11/40	35/161	Alendronate Oral	> 3 years	Ø 84	5/7	0	85,7	95,7
Bedogni 2007 [9] Wang 2007 [8] Prih 2009 [21] Torres 2009 [23] Shin 2010 [3] Brooks 2007 [10] Starck 1995 [11] Marx 2007 [a]	Case Study Level of evidence 5		2 – 10	Oral	6 months – 10 years	12 – 48	0 – 5	0 – 6	0 – 100	-
Shirota 2009 [24] Ferrari 2008 [4] Marx 2007 [a]	Case Study Level of evidence 5		2 – 6	Intravenous	2 – 5 years	6/12	0 – 2	0 – 6	0 – 100	-

1. Perioperative antibiotic prophylaxis, 2. Atraumatic surgical procedure with economical periosteal denudation, 3. Smoothing sharp edges of bone, 4. The primary plastic cover (46). Unfortunately, a description of the surgical procedure is lacking in nearly all implant bisphosphonate studies, i.e. the procedure was described in only one study (18) and two studies mention that implant insertion was carried out under perioperative antibiotics (5, 18).

Recommendations by AAOMS (39) and DGZMK (45) for patients under bisphosphonate therapy:

#### AAOMS (2009):

I.v. BP therapy for cancer patients is an absolute contraindication for implant insertion. For patients who have undergone less than three years of oral BP therapy and exhibit no other risk factors, implant insertion is possible. For patients under oral BP therapy with a duration of therapy less than 3 years and adjuvant corticosteroid therapy, the BP

medication should be stopped 3 months prior to surgery and resumed 3 months after the operative intervention (so-called "drug holiday"). The same applies to patients treated with BP tablets for more than three years regardless of any possible corticosteroid administration. In general, patients should be closely monitored.

#### DGZMK (45):

For implantation under BP therapy, the risk profile of each patient (underlying disease, type, duration, medication dosage, cofactors) must be determined. In addition, no implants should be inserted if there are sufficient prosthetic restoration alternatives for patients at increased risk. Furthermore, an interruption in BP therapy is not evidence based as yet. Implantation with St.p. BP-ONJ is considered a very high risk and implant insertion is not advisable here. For existing BP therapy, intensive follow-up (oral hygiene and plaque control) as part of frequent monitoring makes sense.

#### Abstract:

The guidelines for dental implant treatment of patients under BP therapy are built on expert opinions and are not evidence-based. Intravenous BP therapy for cancer indication is currently viewed as an absolute contraindication for dental implants. Although oral BP therapy does not represent an absolute contraindication, patients should be informed that they are at increased risk for BP-ONJ and consequently implant loss or the occurrence of peri-implantitis. The effects of bisphosphonate therapy on bone physiology and thus, the osseointegration of dental implants and their long-term success is currently still insufficiently documented and will keep us busy scientifically over the coming years. The review article by Grötz et al. (45) and the guidelines available online (46) are recommended for further details.

Table 2: Evidence class recommendations of the AHRQ (Agency for Healthcare Research and Quality)

Ia	Evidence obtained from at least one meta-analysis on the basis of high methodological quality randomized controlled trials.
Ib	Evidence obtained from at least one sufficiently large, high methodological quality randomized controlled trial.
IIa	Evidence obtained from at least one well-designed (high quality) controlled trial without randomization.
IIb	Evidence obtained from at least one well-designed quasi-experimental trial.
III	Evidence obtained from well-designed (high methodological quality), non-experimental descriptive trials such as comparison studies, correlation studies or case-control studies.
IV	Evidence obtained from reports from expert committees or expert opinion or clinical experience (opinions and beliefs) of recognized authorities; descriptive studies.
V	Case series or one or more expert opinions.

## Literature

- 1 Jeffcoat, M.K.** Safety of oral bisphosphonates: controlled studies on alveolar bone. *The International Journal of Oral & Maxillofacial Implants.* **2006**; 21: 349-53.
- 2 Degidi, M., Piattelli, A.** Immediately loaded bar-connected implants with an anodized surface inserted in the anterior mandible in a patient treated with bisphosphonates for osteoporosis: a case report with a 12-month follow-up. *Clinical Implant Dentistry and Related Research.* **2003**; 5(4):269-72.
- 3 Shin et al.** Implant failure associated with oral bisphosphonate-related osteonecrosis of the jaw. *Journal of Periodontal & Implant Science.* **2010**; 40: 90-95.
- 4 Ferrari et al.** Fibula free flap with endosseous Implants for reconstructing a resected mandible in bisphosphonate osteonecrosis. *J Oral Maxillofac Surg.* **2008**; 66: 999-1003.
- 5 Kasai et al.** The prognosis for dental implants placed in patients taking oral bisphosphonates. *J Calif Dent Assoc.* **2009**; 37:39.
- 6 Mavrokki et al.** Nature and frequency of bisphosphonate-associated osteonecrosis of the jaws in Australia. *J Oral Maxillofac Surg.* **2007**; 65: 415-423.
- 7 Aspenberg, P.** Bisphosphonates and implants. *Acta Orthopaedica.* **2009**; 80(1): 119-123.
- 8 Wang et al.** Effect of long-term oral bisphosphonates on implant wound healing: Literature review and a case report. *Journal of Periodontology.* **2007**; 78: 584-594.
- 9 Bedogni et al.** Oral bisphosphonate-associated osteonecrosis of the jaw after implant surgery: A case report and a literature review. *J Oral Maxillofac Surg.* **2010**; 68: 1662-1666.
- 10 Brooks et al.** Osteonecrosis of the jaws associated with the use of risendronate: report of 2 new cases. *Oral Surg Oral Med Oral Radiol Endod.* **2007**; 103: 780-6.
- 11 Starck et al.** Failure of osseointegrated dental implants after bisphosphonate therapy for osteoporosis: A case report. *Int J Oral Maxillofac Implants.* **1995**; 10: 74-8.
- 12 Bell, B. M., Bell, R. E.** Oral Bisphosphonates and dental Implants: A retrospective study. *J Oral and Maxillofac Surg.* **2008**; 66: 1022-1024.
- 13 Rezka et al.** Nitrogen-containing bisphosphonate mechanism of action. *Mini Rev Med Chem.* **2004**; 4:711-19.
- 14 Grant et al.** Outcomes of placing dental Implants in patients taking oral bisphosphonates: A review of 115 cases. *J Oral and Maxillofac Surg.* **2008**; 66: 223-230.
- 15 Albrektsson et al.** The long-term efficacy of currently used dental implants: A review and proposed criteria of success. *Int J Oral Maxillofac Implants.* **1986**; 1:11-25.
- 16 Lazarovici et al.** Bisphosphonate related osteonecrosis of the jaw associated with dental implants. *J Oral and Maxillofac Surg.* **2010**; 68: 790-796.
- 17 Scully et al.** Dental endosseous implants in patients on bisphosphonate therapy. *Implant Dent.* **2006**; 15: 212-18.
- 18 Fugazzoto et al.** Implant placement with or without simultaneous tooth extraction in patients taking oral bisphosphonates: Postoperative healing, early follow-up, and the incidence of complications in two private practices *J Periodontol.* **2007**; 78: 1664-1669.
- 19 Ruggiero et al.** Osteonecrosis of the jaws associated with the use of bisphosphonates: a review of 63 cases. *J Oral Maxillofac Surg.* **2004**; 62: 527-534.
- 20 Marx, R.E.** Pamidronate (Aredia) and zoledronate (Zometa) induced avascular necrosis of the jaws: a growing epidemic. *J Oral Maxillofac Surg.* **2003**; 61: 115-7.
- 21 Pirih et al.** Case report of implant placement in a patient with Paget's disease on bisphosphonate therapy. *J Mich Dent Assoc.* **2009**; 91: 38-43.
- 22 Dimopoulos MA et al.** Osteonecrosis of the jaw in patients with multiple myeloma treated with bisphosphonates: evidence of increased risk after treatment with zoledronic acid. *Haematologica.* **2006**; 91(7):968-71.
- 23 Torres et al.** Dental Implants in a patient with Paget disease under bisphosphonate treatment: a case report. *Oral Surg Oral Med Oral Pathol Oral Radiol Endod.* **2009**; 107: 387-392.
- 24 Shirota et al.** Bisphosphonate-related osteonecrosis of the jaw around dental implants in the maxilla: report of a case. *Clin Oral Implants Res.* **2009**; 20: 1402-1408.
- 25 Marx, R.E. [a]** Oral and intravenous bisphosphonate-induced osteonecrosis of the jaws: History, etiology, prevention and treatment. *1th ed. Canada: Quintessence Publishing Co, Inc;* **2007**.
- 26 Flichy-Fernández et al.** Bisphosphonates and dental implants: Current problems. *Med Oral Patol Oral Cir Bucal.* **2009**; Jul 1;14 (7): E355-60.
- 27 Marx et al. [b]** Oral bisphosphonate-induced osteonecrosis: Risk factors, prediction of risk using serum CTX testing, prevention, and treatment. *J Oral Maxillofac Surg.* **2007**; 65: 2397-410.
- 28 Montoya-Carralero et al.** Dental implants in patients treated with oral bisphosphonates. A bibliographic review. *Med Oral Patol Oral Cir Bucal.* **2010**; Jan 1;15 (1): e65-9.
- 29 Mínguez-Serra et al.** Oral implants in patients receiving bisphosphonates: A review and update. *Med Oral Patol Oral Cir Bucal.* **2008**; Dec 1;13 (12): E755-60.
- 30 Koka et al.** Survival of dental implants in post-menopausal bisphosphonate users. *Journal of Prosthodontic Research.* **2010**; 54:108-111.
- 31 Otto et al.** Osteoporosis and bisphosphonates-related osteonecrosis of the jaw: Not just a sporadic coincidence- a multi centre study. *Journal of Cranio-Maxillo-Facial Surgery.* **2011**; 39: 272-277.
- 32 Hwang et al.** Medical contraindications to implant therapy: Part II: Relative Contraindications. *Implant Dent.* **2007**; Mar;16(1):13-23.
- 33 Hwang et al.** Medical Contraindications to Implant Therapy: part I: absolute Contraindications. *Implant Dent.* **2006**; Dec;15(4):353-60.
- 34 Liddelov et al.** Patient-related factors for implant therapy. A critique of pertinent literature. *Australian Dental Journal.* **2011**; 56: 417-426.
- 35 American Dental Association Council on Scientific Affairs.** Dental management of patients receiving oral bisphosphonate therapy: Expert panel recommendations. *J Am Dent Assoc.* **2006**; 137: 1144-1150.
- 36 Martin et al.** Characteristics of implant failures in patients with a history of oral bisphosphonate therapy. *J Oral Maxillofac Surg.* **2010**; 68: 508-514.
- 37 Grötz et al.** Zahnärztliche Betreuung von Patienten unter/nach BP Medikation. Gemeinsame wissenschaftliche Stellungnahme der DGZMK und der DGMKG. **2006**. [http://www.dgzmk.de/uploads/tx\\_szdgzmkdocuments/Zahnaerztliche\\_Betreuung\\_von\\_Patienten\\_unternach\\_Bisphosphonat-Medikation.pdf](http://www.dgzmk.de/uploads/tx_szdgzmkdocuments/Zahnaerztliche_Betreuung_von_Patienten_unternach_Bisphosphonat-Medikation.pdf)
- 38 Javed et al.** Osseointegration of dental implants in patients undergoing bisphosphonate treatment: A literature review. *J Periodontol.* **2010**; 81: 479-484.
- 39 American Association of oral and maxillofacial surgeons position paper on bisphosphonate-related osteonecrosis of the jaws. J Oral Maxillofac Surg.** **2009**; 67: 2-12. Suppl 1.
- 40 Zahrowski, J.J.** Comment on the American association of oral and maxillofacial surgeons statement on bisphosphonates. *J Oral Maxillofac Surg.* **2007**; 65(7):1440-1.
- 41 Ruggiero et al.** American association of oral and maxillofacial surgeons position paper on bisphosphonate-related osteonecrosis of the jaws-2009 update. *J Oral Maxillofac Surg.* **2009**; 67: 2-12.
- 42 Madrid et al.** What impact do systemically administrated bisphosphonates have on oral implant therapy? A systematic review. *Clin. Oral Impl. Res.* **2009**; 20: 87-95.
- 43 Cartos et al.** Implications of bisphosphonate use in dentistry. *Analecta Periodontologica* **2009**; 20: (9)1-15.
- 44 Bamias A, Kastritis E, Bamia C, et al.** Osteonecrosis of the jaw in cancer after treatment with bisphosphonates: incidence and risk factors. *J Clin Oncol.* **2005**; 23:8580-7.
- 45 Grötz K.A., Piesold J.-U., Al-Nawas B.** Bisphosphonat-assoziierte Kiefernekrose (BP-ONJ) und andere Medikamenten-assoziierte Kiefernekrosen. AWMF Online (**04/2012**). [www.awmf.org/leitlinien/detail/ll/007-091.html](http://www.awmf.org/leitlinien/detail/ll/007-091.html).
- 46 Grötz K.A.** Bei welchen Bisphosphonat-Patienten darf ich eigentlich implantieren? Ein systematisches Review. *Zeitschrift für Zahnärztliche Implantologie* **2010**; 26 (2): 153-61.

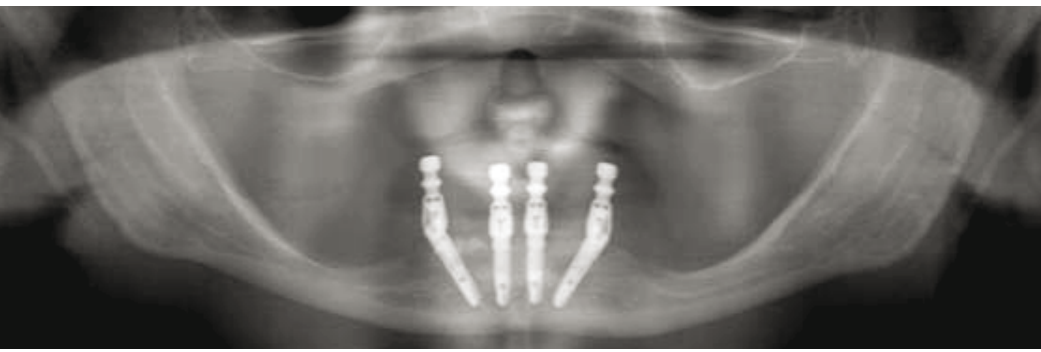


Fig. 44: Orthopantomogram after four months of implant healing

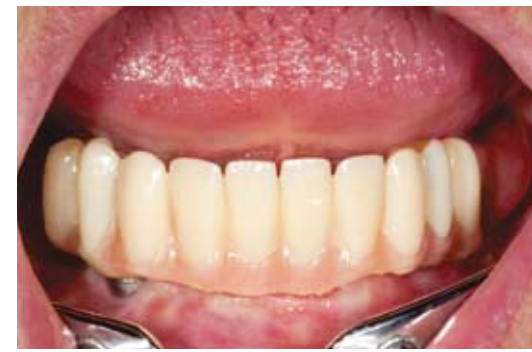

Fig. 45: Initial clinical situation after four months of implant healing with immediate long-term temporary restoration



## THE ESTHETIC AND FUNCTIONAL FINAL RESTORATION OF IMPLANTS SET ACCORDING TO THE MALÓ-PROCEDURE AND IMMEDIATELY RESTORED

Dr Ferenc Steidl, dentist Diana Mascher, Sömmerda, Bad Frankenhausen and MDT Sebastian Schuldes, M.Sc., Eisenach

In logo No. 3, the “immediate restoration in the edentulous mandible according to the Maló procedure using the CAMLOG® Guide System and Vario SR abutments” was shown. The final implant-supported restoration with a removable superstructure should distinguish itself by a tight seating with corresponding chewing function and by fulfillment of phonetic and esthetic requirements.

Bar-supported restorations have proven themselves in implant prosthetics for decades. Precious metals were often used in the past due to their favorable processing characteristics. These are characterized by good biocompatibility, but exhibit a high affinity for plaque. This characteristic should be viewed as particularly problematic for bars, which are more difficult to clean compared to double crowns. While searching for a suitable material, we chose zirconia. A bar made of zirconia is tooth-colored, high-strength, absolutely biocompatible and has a low affinity to plaque.

### Four months of healing and wearing time of the long-term temporary restoration

Figures 44 to 46 show the initial radiographic and clinical situation after four months of implant healing with immediate long-term temporary restoration. It was important to maintain the arch relationship through occlusal

contacts in each support zone for stabilization of the temporomandibular joints. Functional and esthetic aspects were thus ensured during the healing time.

### Fabrication of the bar and intraoral bonding

Fabrication of the cast after a closed impression on abutment level took into account a gingival mask made of silicone (Fig. 47). Tooth positioning that served as the basis for the CAD design when fabricating the immediate restoration was adjusted to the new cast situation (Fig. 48). The bar wax-up was created according to the requirements of the tooth positioning with distal PRECIVERTIX® attachments (Ceka) (Figs. 49 and 50).

To fulfill the requirement for an absolutely tension-free fit of the bar on the implant, the bar should be bonded intraorally. The Vario SR bases for bar were used

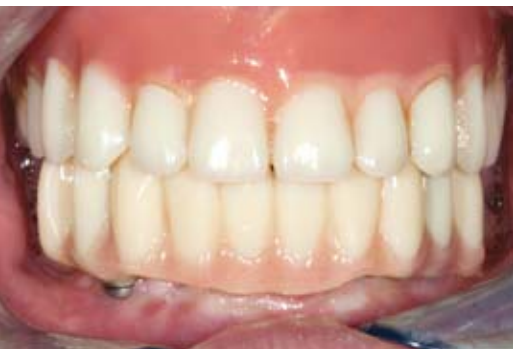as the bonding base and customized accordingly.

Fabrication of the bar is CAM-assisted. The wax-up was digitalized by laser scan and then the milling strategy calculated (Figs. 51 to 53). Figure 54 shows the cast with the Vario SR bases for bar modified for the bonding base and the bar prepared for intraoral bonding.

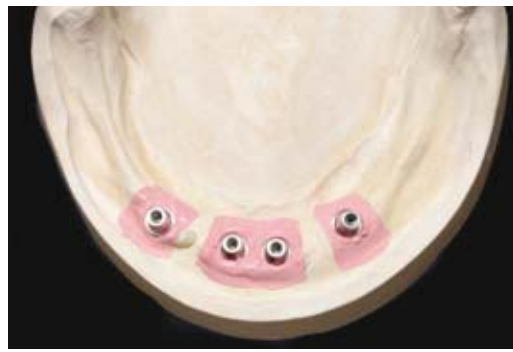The mucosa showed no signs of inflammation. Insertion and removal of the occlusally screw-retained long-term temporary restoration was comfortably handled by the Vario SR abutment during the 4-month wearing time. Regular cleaning and hygiene was well controlled (Figs. 55 and 56). The attached gingiva on the mandibular alveolar process was maintained and showed some resilience, which facilitates subsequent oral hygiene (Fig. 57).

An insertion tool was used to insert the customized Vario SR bases for bar. A gap-free margin fit of the Vario SR

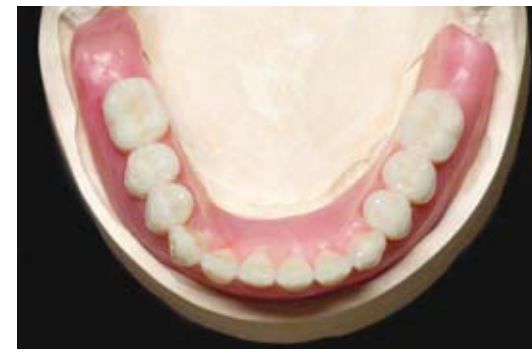



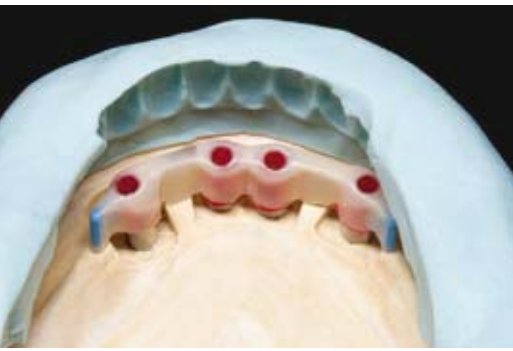**Fig. 46:** Maintenance of the arch relationship through occlusal contacts in each support zone for stabilization of the temporomandibular joints



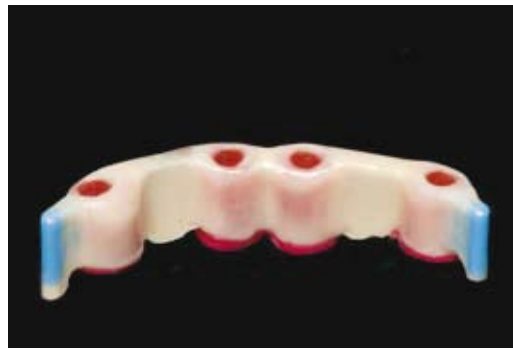
**Fig. 47:** Cast situation with Vario SR analogs after closed impression on the abutment level



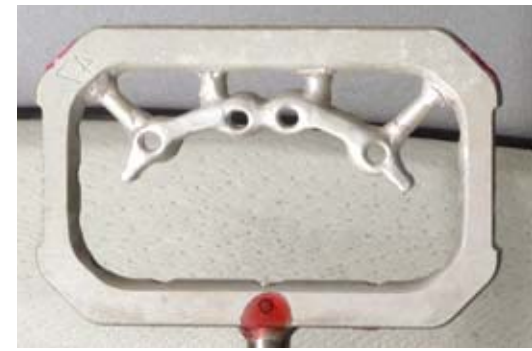**Fig. 48:** Tooth positioning for accurate analysis of the space conditions



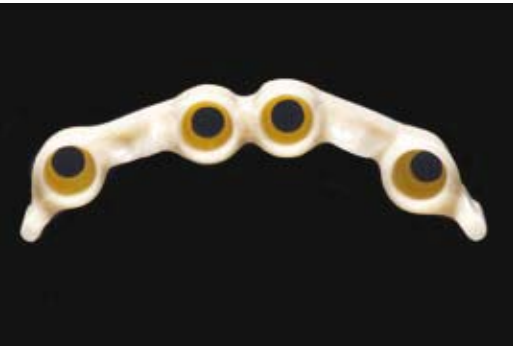**Fig. 49:** Control of the bar wax-up using a silicone index



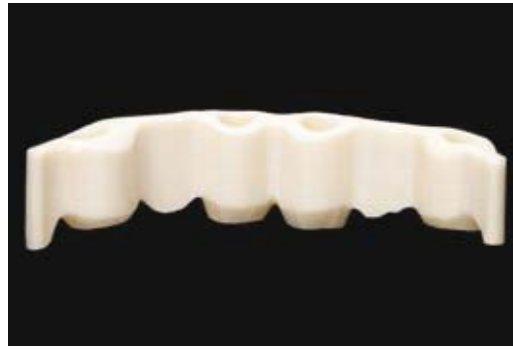**Fig. 50:** Finished bar wax-up with distal PRECI-VERTEX® attachments (Ceka)



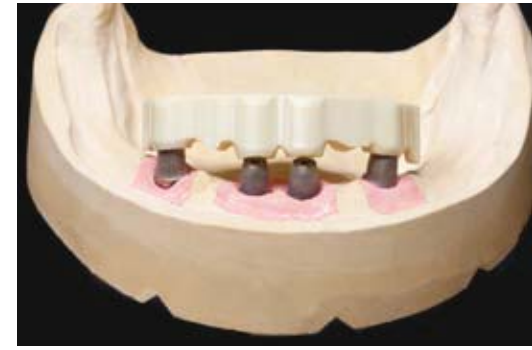**Fig. 51:** The wax-up is laser-scanned and the milling strategy then worked out



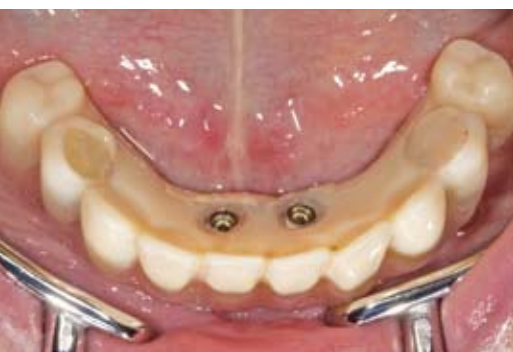**Fig. 52:** The zirconia bar unprocessed



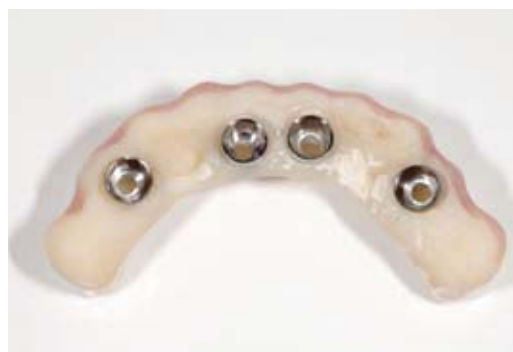**Fig. 53:** The zirconia bar unprocessed



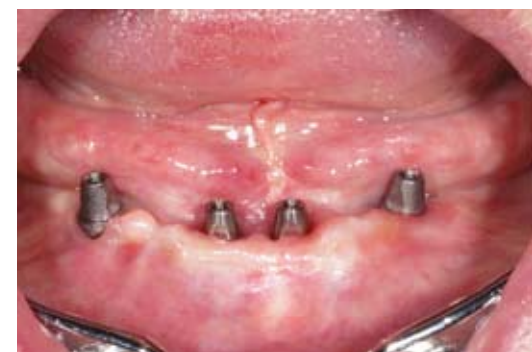**Fig. 54:** Cast with the Vario SR bases for bar modified as a bonding basis and the bar prepared for intraoral bonding



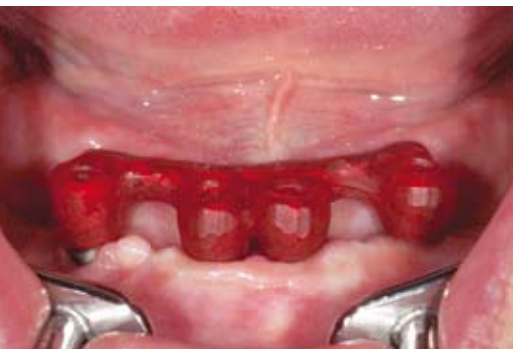**Fig. 55:** Removal of the immediate restoration



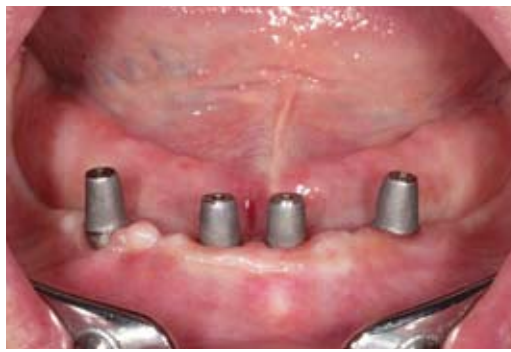**Fig. 56:** The temporary bridge after four months of wearing time from the basal view



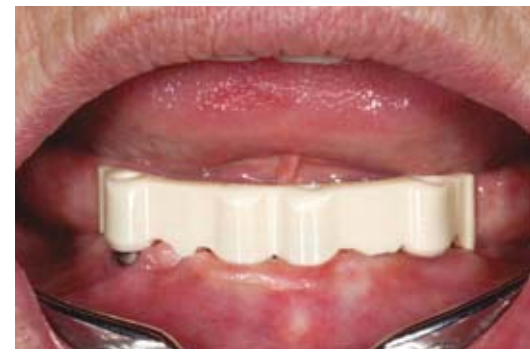**Fig. 57:** Oral situation with Vario SR abutments and attached gingiva maintained



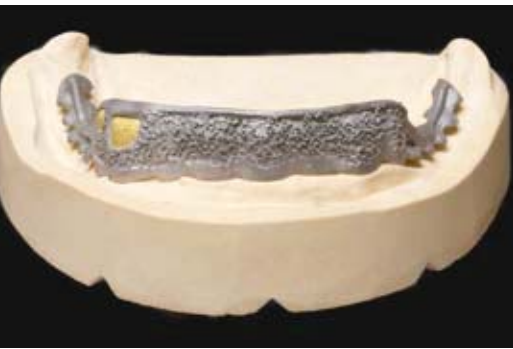
**Fig. 58:** Insertion of the customized Vario SR bases for bar with insertion tool



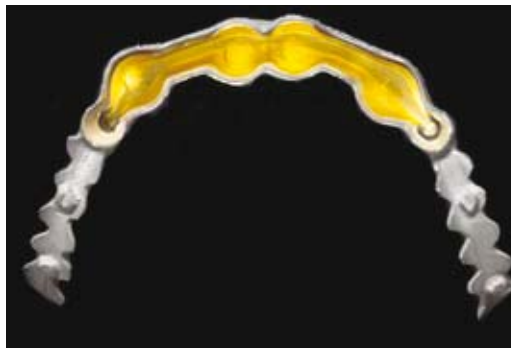
**Fig. 59:** The customized Vario SR bases for bar in situ



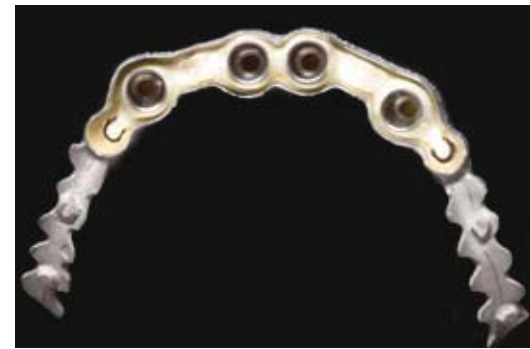**Fig. 60:** Intraoral bonding of the bar to ensure the absence of stress



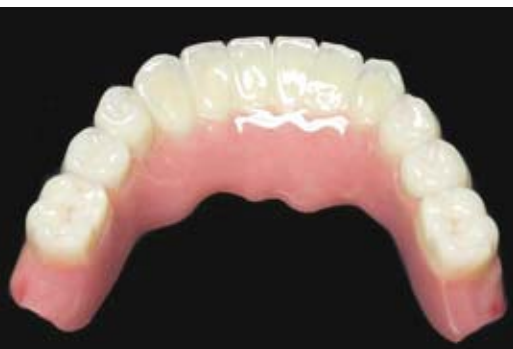**Fig. 64:** Tertiary framework made of a cobalt-molybdenum-chromium alloy fabricated using traditional casting technology



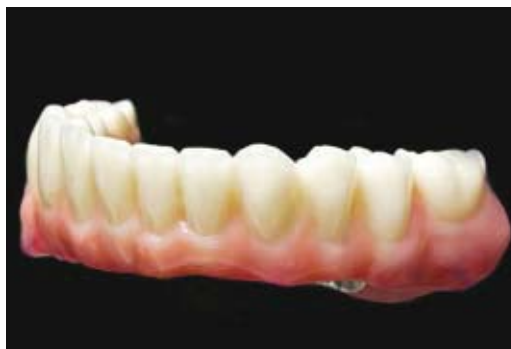**Fig. 65:** Bar matrix made of 99.9% pure gold



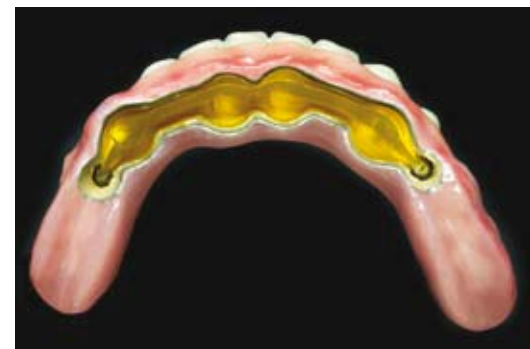
**Fig. 66:** Highly precise fit of the primary, secondary and tertiary structure



**Fig. 70**



**Fig. 71**



**Fig. 72**

bases for bar on the Vario SR abutments without pressure-sensitive change to the attached gingiva reduces the probability of peri-implant inflammation (**Figs. 58 and 59**).

Panavia F2.0 (Kuraray) is used for intraoral bonding of the bar. As adequately described in the literature, this procedure guarantees the absence of stress of the superstructure on the implants and contributes significantly to the long-term success of the bar construction (**Fig. 60**).

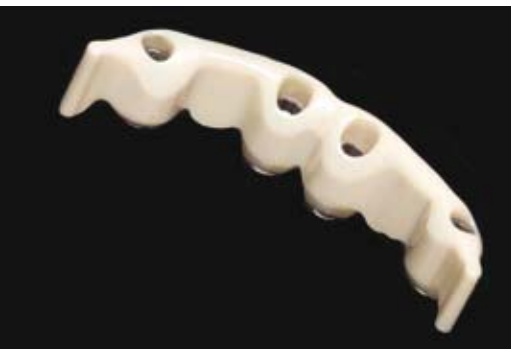An essential requirement for wear-free operation of the bar system is an absolutely smooth surface. The bonded zirconia bar is finalized using a turbine with water cooling and diamond-coated abrasives (**Figs. 61 to 63**).

#### **Fabrication of the tertiary structure**

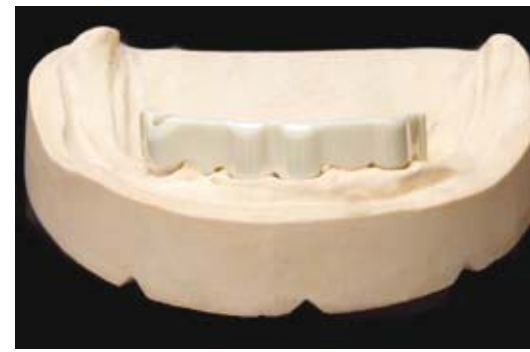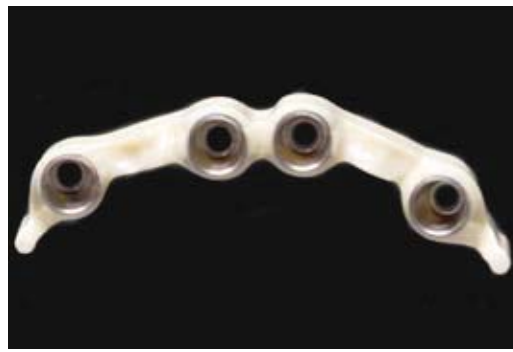The tertiary framework was fabricated using traditional casting technology from a cobalt-molybdenum-chromium alloy (**Fig. 63**). The bar matrix was finished in the electroforming process out of 99.9% pure gold (**Figs. 64 to 66**). Instead of the

usual friction with bars made of a metal alloy, adhesive and cohesive forces come to bear with ceramic bars with a matrix of galvanic gold. The salivary film between the zirconia bar and the matrix of 99.9% pure gold ensures high cohesion together with the two PRECI-VERTIX® attachments distally attached to the bar and conveys to the patient the feeling of a fixed prosthesis. We see the following benefits in a zirconia galvanic bar:

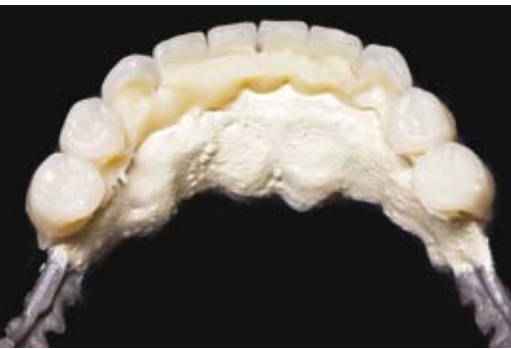- Passive fit
- Consistently high level of retention
- Wear-free



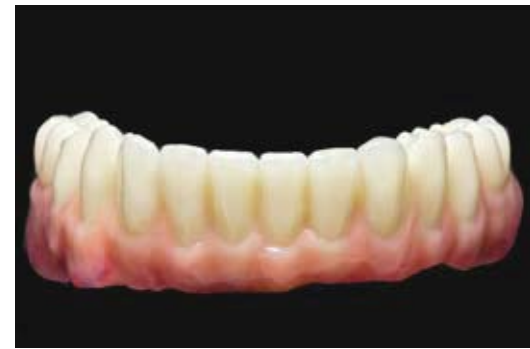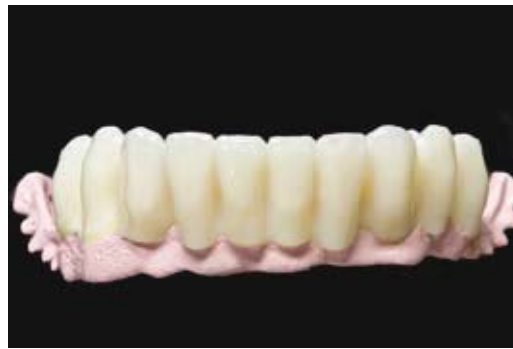**Figs. 61 and 62:** Bonded zirconia bar in the finished polished condition



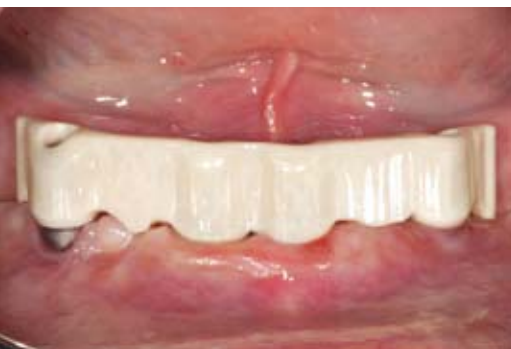**Fig. 63:** Cast situation with finished bar



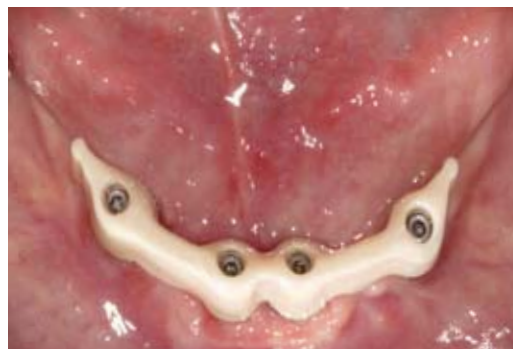**Figs. 67 and 68:** Veneering of the tertiary structure with high-performance polymer veneers



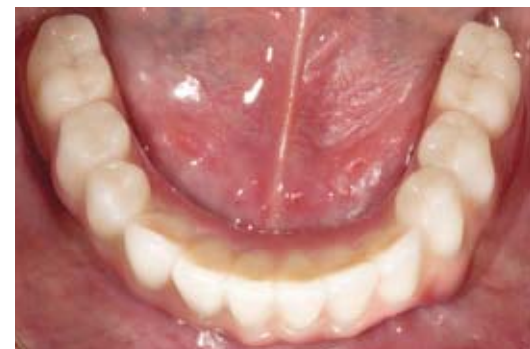**Fig. 69 to 72:** The completed final superstructure with polychrome gingiva design



**Fig. 73:** Zirconia bar in the mouth of the patient



**Fig. 74:** Extra-axial transmissions of force minimized by the polygonal support of the superstructure



**Fig. 75:** Graceful design of the bar prosthetic base

- Excellent biocompatibility
- No corrosion
- No cold welding
- More cost-effective compared to individually milled gold bars
- Tooth-colored appearance

With high-performance polymers, in this case visio.lign (Bredent), functionally high-quality and esthetically pleasing restorations can be created in an efficient manner. Due to properties of this state-of-the-art materials group that reduce masticatory pressure, the functional conditions of the craniomandibular

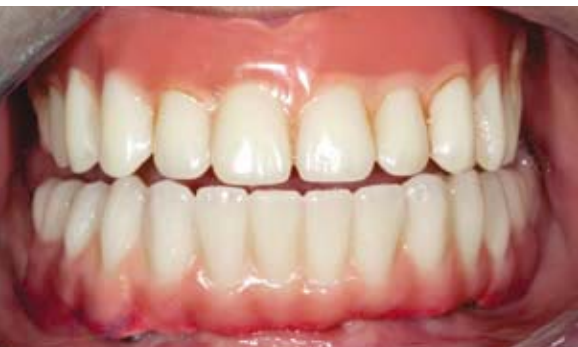system are accommodated (**Figs. 67 and 68**).

Essential for the overall esthetics of this implant restoration was the multicolor design of the gingival sections. The pink-colored plastic with composite was individualized (**Figs. 69 to 72**).

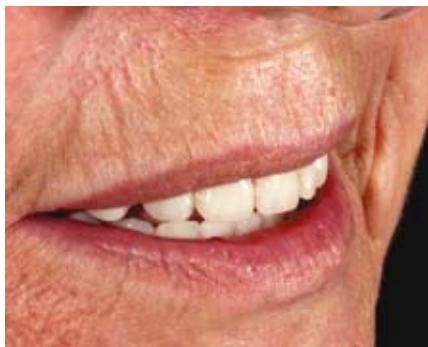Polygonal support of the superstructure is achieved by the quadrangular positioning of the implants. Extra-axial transmissions of force are minimized and the mandibular dental arch is stabilized circularly (**Figs. 73 and 74**). The bar can

be removed when needed, thus providing easy access in the event that inspections and hygiene measures are necessary.

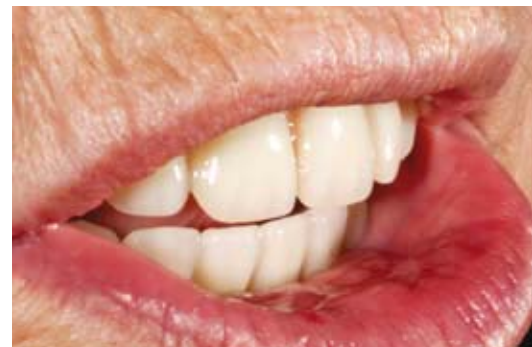A graceful design of the bar prosthetic base ensures a large range of motion for the tongue, as well as the vestibular and lingual ribbons (**Figs. 75 and 76**). Taking into account esthetic and functional parameters (laugh line, midline, occlusal plane, cuspid line), there is a natural-looking treatment outcome with harmonious lip profile (**Figs. 77 and 78**).



**Fig. 76:** Large range of motion for the tongue, as well as the vestibular and lingual ribbons



**Fig. 77:** A natural-looking treatment outcome



**Fig. 78:** Consideration of esthetic and functional parameters

## Conclusion

The removable bar-supported restoration offers the patient high wear comfort because of the secure anchorage. Due to its low affinity to plaque, the zirconia meets the high demands for oral hygiene and from the author's perspective, is a good choice for the final restoration of implants set according to the Paulo Maló procedure.

## FURTHER READING

- [1] Ackermann KL, Kirsch A, Nagel R, Neuendorff G. Mit Backward Planning zielsicher therapieren. Teil 1: Implantat-prothetische Behandlungsbeispiele teamwork J Cont Dent Educ 2008: 466–484.
- [2] Agliardi E, Panigatti S, Clericó M, Villa C, Maló P. Immediate rehabilitation of the edentulous jaws with full fixed prostheses supported by four implants: interim results of a single cohort prospective study. Clin. Oral Impl. Res. 21, 2010; 459–465.
- [3] Franchini I, Daverio L, Castellaneta R, Rossi MC, Testori T, Tosini T. Immediate and delayed "All-on-Six" rehabilitation of the atrophic maxilla with tilted implants. EDI 2009;5:62–70.

- [4] Malo P, de Araújo Nobre M, Lopes A, Moss SM, Molin GJ. A longitudinal study of the survival of All-on-4 implants in the mandible with up to 10 years of follow-up. J Am Dent Assoc 2011;142(3):310–20.

- [5] Kirsch A, Nagel R, Neuendorff G, Fiderschek J, Ackermann KL. Backward Planning und dreidimensionale Diagnostik, Teil 2: Schablonengeführte Implantation nach CT-basierter 3D-Planung mit sofortiger Eingliederung des präfabrizierten Zahnersatzes – ein erweitertes Backward Planning-Konzept. teamwork J Cont Dent Educ 2008: 734–754.

- [6] Randelzhofer P, Cacaci C: Verschraubte Lösung – implantatgetragene Restauration im zahnlosen Oberkiefer. teamwork J Cont Dent Educ 2011: 294–300.

## AUTHORS



Photo: Dirk Wächter

### Dr Ferenc Steidl:

1991 to 1996, study program in dentistry at FSU Jena. Subsequent specialist training in oral surgery in Bietigheim/Bissingen, Germany and at Diakonie Hospital, Schwäbisch-Hall, Germany; has been practicing implant dentistry since 1997. 2001, Specialist in Oral Surgery at LZK Baden-Württemberg, Germany. Member of DGZMK, BDO, DGI, AG Oral Surgery, DGP, MVZI. 2008, Fellow of the European Board of Oral Surgery (European certification). Joint dental practice for maxillofacial surgery in Sömmerda und Bad Frankenhausen, Germany.



Photo: Dirk Wächter

### Dentist Diana Mascher:

1999 to 2003, dental technician training. 2003 to 2008, study program in dentistry at FSU Jena. January 2009, license to practice dentistry. Salaried dentist in the joint dental practice for maxillofacial surgery of Dr Steidl.

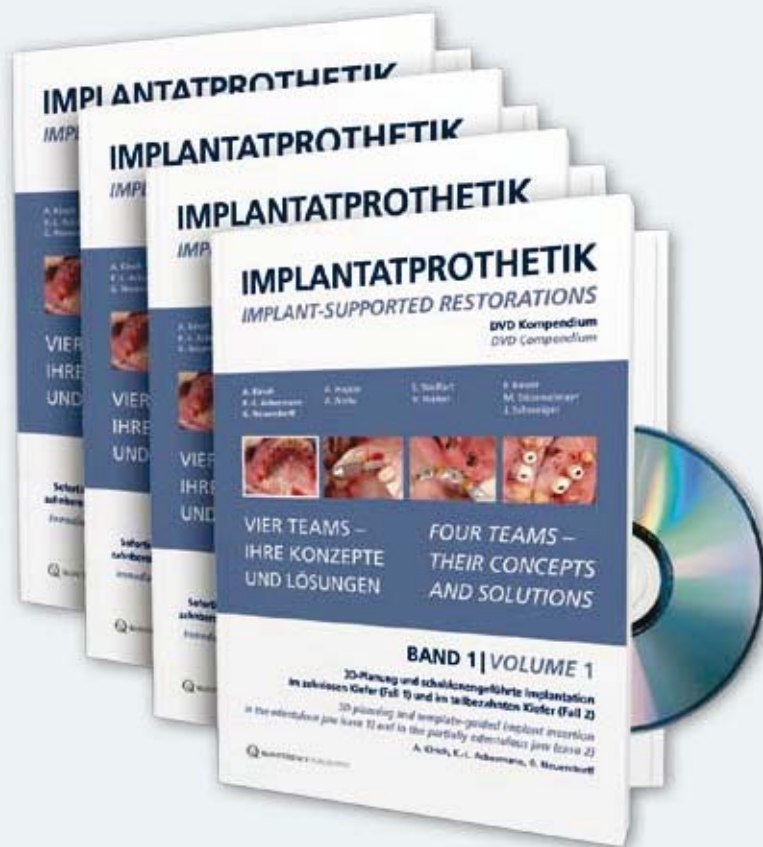Practice of Dr Ferenc Steidl  
DRK Krankenhaus  
An der Wipper 2  
06567 Bad Frankenhausen, Germany  
Tel.: +41 (0) 3634 317387  
[info@praxis-steidl.de](mailto:info@praxis-steidl.de)  
[www.dr-steidl.de](http://www.dr-steidl.de)



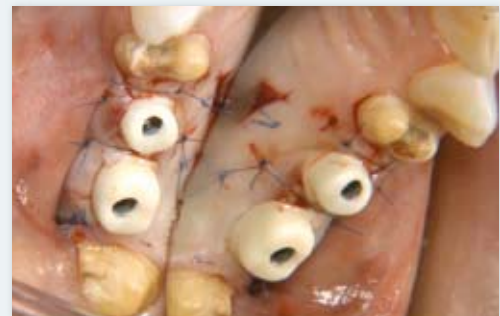### MDT Sebastian Schuldes, M.Sc.:

1991 to 1995, dental technician training; 1998 to 1999, qualification for master dental technician. 1999 to 2000, continuing education for business administration in trade. 2006 to 2008, study program leading to a Master of Science, M.Sc.. 2007, inception of S-implantat® (service provider of 3D implant planning). 2009, DGZI curriculum, 3D planning of implant dentistry and prosthetics. 2011, construction of the zaxocad-Dental Solutions® milling center.

Dental-Labor Schuldes GmbH  
Johann-Sebastian-Bach-Straße 2  
99817 Eisenach, Germany  
Tel.: +41 (0) 3691 203950  
[info@zahn-neu.de](mailto:info@zahn-neu.de)  
[www.zahn-neu.de](http://www.zahn-neu.de)



<sup>1</sup> Experience this publication as a video! It comes from the video compendium "Implantatprothetik VIER TEAMS – IHRE KONZEPTE UND LÖSUNGEN" (Implant-supported Restorations FOUR TEAMS – THEIR CONCEPTS AND SOLUTIONS) published this year by Quintessenz Verlag in four volumes. Volume 4 by F. Beuer, M. Stimmelmayer and J. Schweiger focuses on innovative treatment concepts for fixed prostheses on implants using CAD/CAM technology. The video compendium is available from CAMLOG as a DVD or Blu-Ray disc.



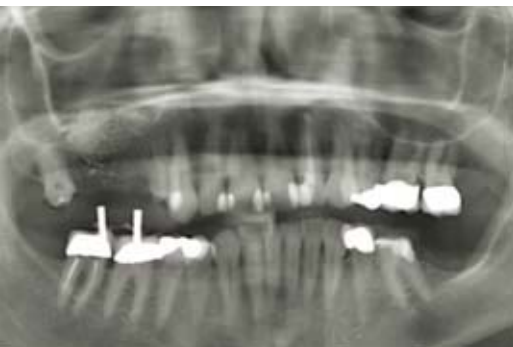## INNOVATIVE TREATMENT CONCEPTS FOR FIXED PROSTHESIS USING CAD/CAM TECHNOLOGY<sup>1</sup>

PD Dr Florian Beuer, Munich, Dr Michael Stimmelmayer, Cham, Josef Schweiger, Munich

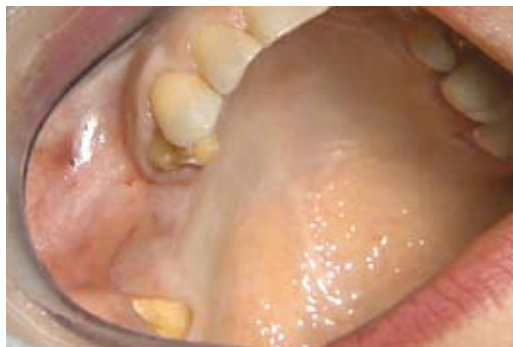

For reasons of time, many patients want treatment in as few sittings as possible. For this purpose, implant positions can be registered, for example, right after implantation. When exposing the implant site, the final abutment is then attached.

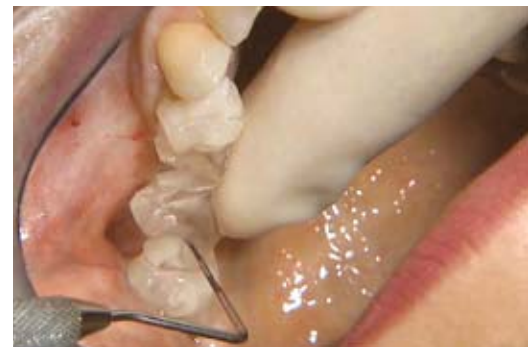This has the additional advantage that the connective tissue attachment does not have to be detached again. The tissue can mature without disruption with potentially beneficial effects on the peri-implant situation [1]. This proven protocol has recently been further developed using CAD/CAM technology [2]. The final abutments can be fabricated from the biocompatible zirconia [3]. The preparation boundaries can also be specified in the software for the temporary restoration relatively accurate at the level of the gingival margin.



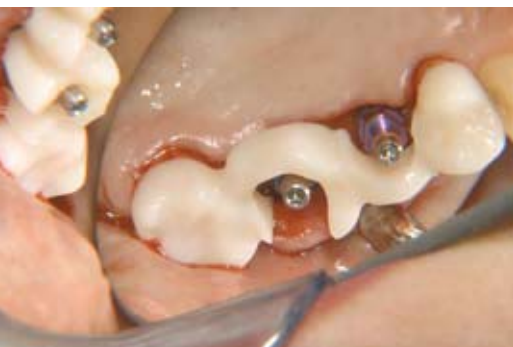**Fig. 1:** Preoperative panoramic imaging: In the first quadrant, a lateral augmentation and external sinus lift were carried out to prepare the implant site.



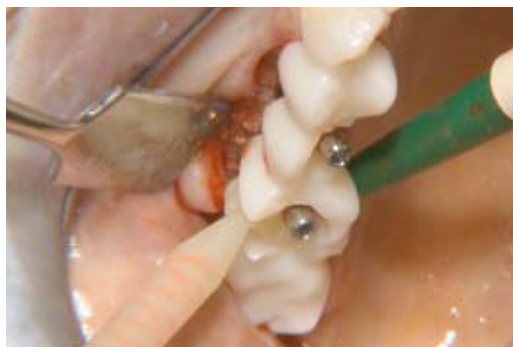**Fig. 2:** Clinical situation before implantation: The teeth on either side of the gap were ground at a previous sitting.



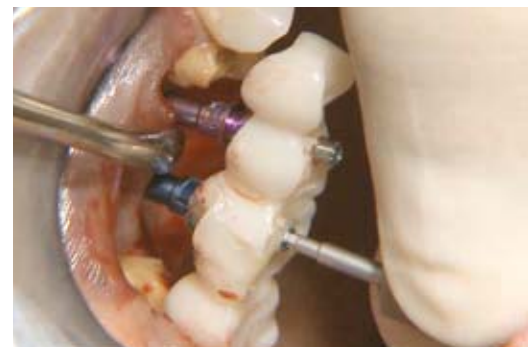**Fig. 3:** A drilling template made of transparent plastic and a periodontal probe are used to mark the required implant positions.



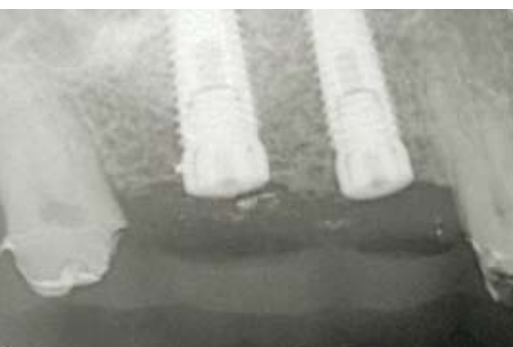**Fig. 7:** The insertion post and inserted registration template are used to again check implant positions.



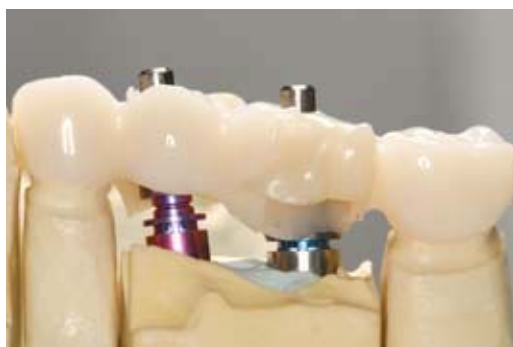**Fig. 8:** To transfer the positions of the implants to the laboratory, a composite is used to bond the template to the insertion posts.



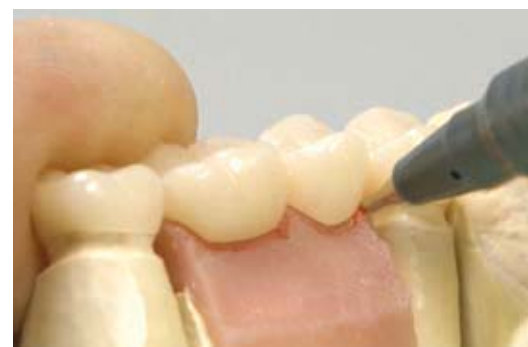**Fig. 9:** The screws of the insertion posts are now loosened and the registration block carefully removed from the mouth.



**Fig. 13:** The radiographic check shows the favorable positioning of the implants in the sagittal plane.



**Fig. 14:** The dental technician screws the lab analogs onto the impression posts and locks their positions with plaster. The gap between lab analog and insertion post is determined by the system.



**Fig. 15:** A gingival mask is fabricated over the implants in the area of the alveolar ridge. Using a copy of the long-term temporary restoration, the emergence profile of the planned implant crowns is then transferred to the gingival mask.

### Initial situation and preparation in the laboratory

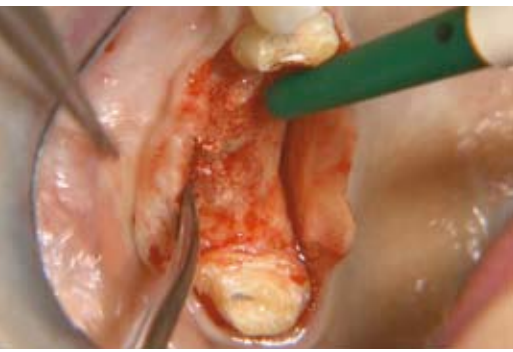
A 50-year-old patient was treated with implants after loss of teeth 15 and 16. The planned implants and bordering teeth 14 and 17 should be fitted with single crowns. As the bone supply around the implant site is inadequate, a lateral augmentation is first performed with guided bone regeneration in combination with an external sinus lift. Panoramic imaging shows the condition after bony healing of the augmentation and preparation of the natural abutment

teeth (**Fig. 1**). **Figure 2** shows the clinical situation before implantation.

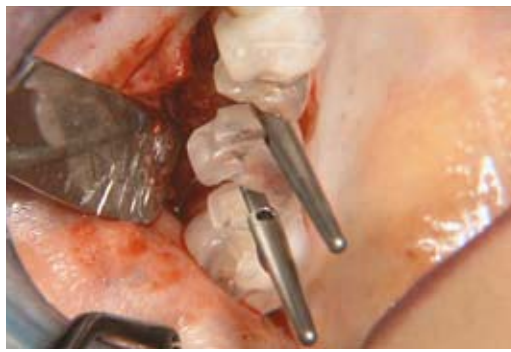In preparation for the implantation sitting, the dental technician creates a drilling template out of transparent plastic based on the long-term temporary restoration (PMMA) (see **Fig. 3**). In addition, a registration template is milled out of PMMA molding blanks (Telio CAD, Ivoclar Vivadent) in the CAD/CAM procedure from the same dataset to transfer implant positions (see **Fig. 7** and **8**).

### Implantation

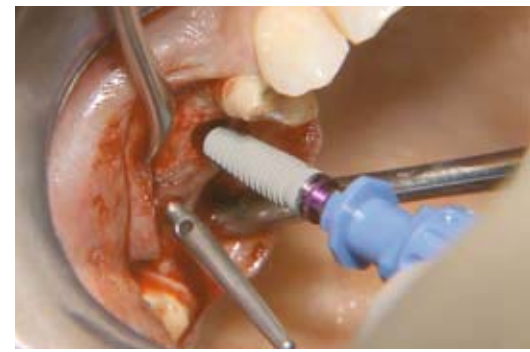The surgeon uses the drilling template and a periodontal probe to first mark implant positions on the anesthetized alveolar ridge mucosa (**Fig. 3**). He then exposes the implantation site using a crestal incision displaced palatally that continues into the sulci of the mesial and distal teeth (**Fig. 4**). The flaps are dissected palatally and buccally as full flaps until visualization of the alveolar ridge width. The buccal flap is continued into the vestibule as a split flap (combined full split flap). The flap can be better stretched and repositioned for a tension-free suture.



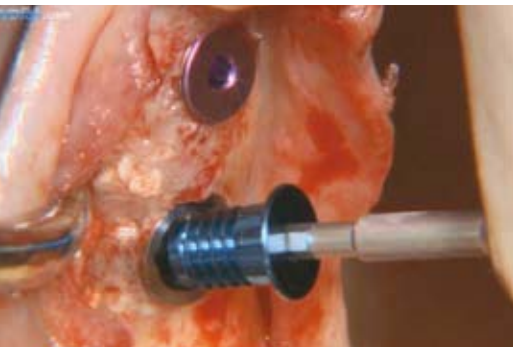
**Fig. 4:** The surgeon made crestal-palatal and intrasulcular incisions, prepared a combined full split flap buccally and mobilized the flap buccally and palatally.



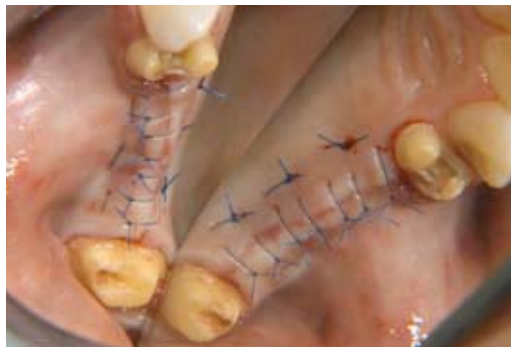**Fig. 5:** Paralleling pins and the drilling template are used to check the exact position and axial alignment of the future implants.



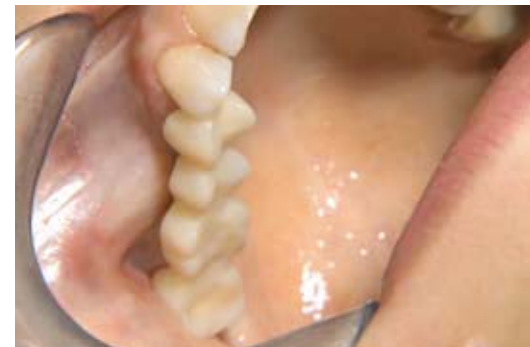**Fig. 6:** After complete preparation of the implant bed, the first CAMLOG® SCREW-LINE implant is inserted.



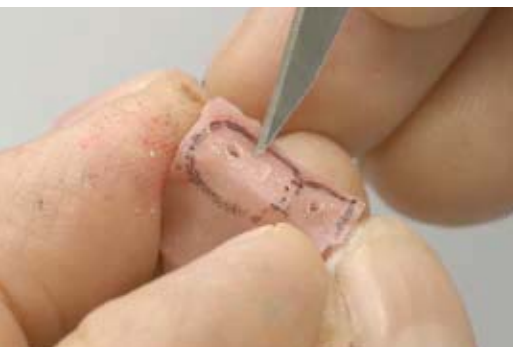**Fig. 10:** The cover screws are inserted. With the distal implant, the buccal orientation of a groove is recognizable.



**Fig. 11:** The margins of the wound are approximated with horizontal backstitch sutures and sutured with single button sutures without tension (image mirrored in the palatal portion).



**Fig. 12:** The long-term PMMA bridge was shortened in the area of the interlink underside before it is mounted.



**Fig. 16:** The technician transfers the implant positions onto the oral side of the gingival mask by perforating it from basal with a hard-metal milling cutter. Then, the emergence profile can be cut out with a scalpel and smoothed with a staggered tooth mill.

Marking holes are made through the drilling template using the 2 mm pilot drill and expanded after removing the template using the surgical round drill. A periodontal probe is used to check the correct distances between implant positions. After completing the pilot holes, the correct alignment of the implants is checked with the drilling template and paralleling pins inserted (**Fig. 5**). After complete preparation of the implant sites, the surgeon inserts two 13 mm CAMLOG® SCREW-LINE implants, the anterior implant with a diameter of

4.3 mm and the distal implant with a diameter of 5.0 mm (**Figs. 6 and 7**).

### Registration of the implant positions and suture

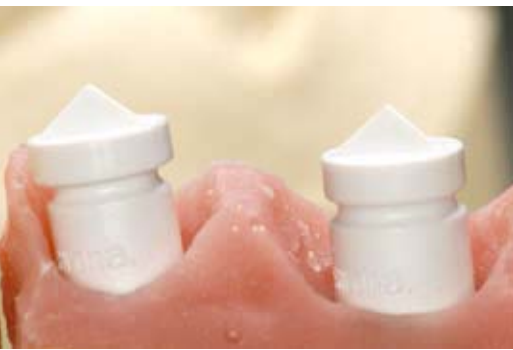Position and alignment of the implants are checked once more with impression posts and registration template made of PMMA (**Fig. 7**). To transfer the exact positions of the implants to the laboratory, a composite is used to bond the template to the insertion posts (**Fig. 8**). After loosening the screws, the block is removed from the mouth (**Fig. 9**). The interiors of the implants are flushed with sterile saline and the cover screws fixed (**Fig. 10**).

The margins of the wound are now approximated with three horizontal backstitch sutures. Monofilament suture material (size 5.0) is used. Single button sutures (size 6.0) follow (**Fig. 11**). The basally ground temporary bridge can now be cemented again (**Fig. 12**). The single button sutures are removed after eight days and the backstitch sutures after 14 days. **Figure 13** shows the results of the implantation in the X-ray image.


### Fabrication of the final abutments and temporary crowns

The intraorally fixed implant position is transferred via the support on the prepared stumps to the preoperative cast in the laboratory. The dental technician screws the lab analogs onto the impression posts and embeds them in plaster (**Fig. 14**). Using a split silicone index, the dental technician creates a gingival mask over the implants in the area of the alveolar ridge. Using a copy of the anatomically designed PMMA long-term temporary restoration, he then transfers the emergence profile of the planned implant crowns to the gingival mask (**Fig. 15**). The implant positions are projected onto the outside of the gingival mask with a round bur from the basal view. The emergence profile can now be cut out using a scalpel and smoothed out using a cross-cut bur (**Fig. 16**).


After the emergence profiles are completed, appropriate scanbodies for CAMLOG® (Sirona) are screwed onto the lab analogs in preparation for scanning (**Fig. 17**). The scanning process is carried out in the strip light



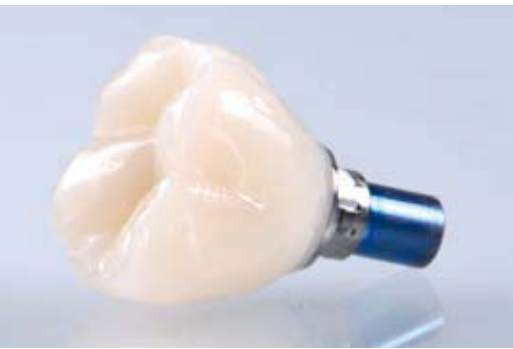**Fig. 17:** Finished emergence profiles in the gingival mask with scanbodies already screwed in for scanning.



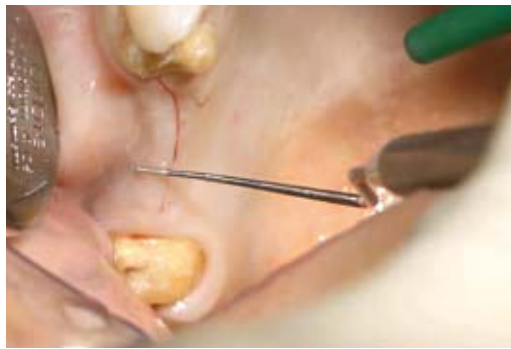**Fig. 18:** A strip light scanner is used to transfer implant positions defined by the scanbodies to the CAD software.



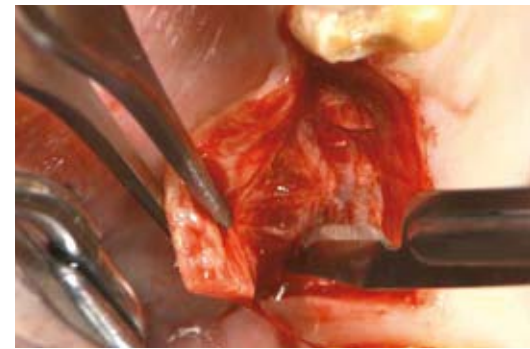
**Fig. 19:** The software then works out the anatomy of the crown biogenetically from the residual teeth. The abutment can then be designed by reducing the crown in a manner that it supports the cusps and in the correct thickness.



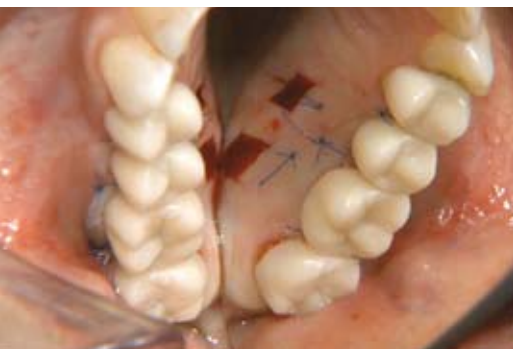**Fig. 23:** The temporary PMMA crown on the abutment for the implant at position 16. The natural "biogenic" anatomy of the crown is easy to see.



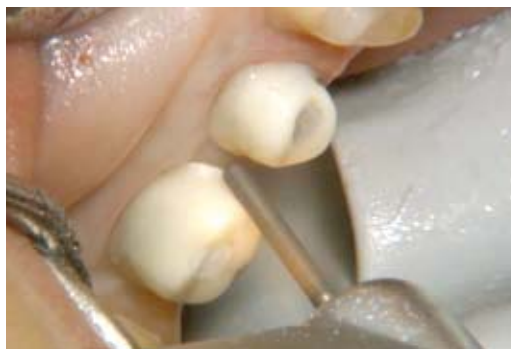**Fig. 24:** Five months after implantation: To expose the implant bed, a slightly curved crestal incision is made at a min. distance of 4 mm from the mucogingival junction and then extended mesially in the buccal sulcus of tooth 14.



**Fig. 25:** A vertical relief cut follows posteriorly distal to the implant at position 16. To prevent tension on the marginal gingiva, the ligament and muscle attachments are carefully removed (technique according to Dr Axel Kirsch).



**Fig. 29:** The long-term temporary crowns are cemented: The removal site from which the grafts were taken can be seen in the mirrored image palatally. The apically displaced mucogingival junction is visible buccally.



**Fig. 30:** The temporary crowns are removed again three months later. The soft tissues have healed in the meantime and the virtually defined preparation margin must be adapted to the new situation using a diamond finishing bur.



**Fig. 31:** Filaments are placed around the teeth and abutments as in the conventional prosthetic. An impression is taken using 2-phase silicone in the double-mix procedure. The result is a very good base for the new master cast.

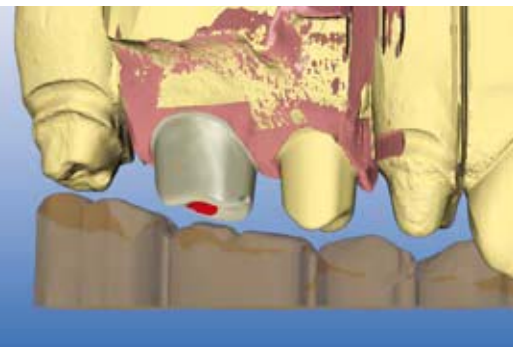
scanner (**Fig. 18**), with which the implant positions are transferred to the planning software in three dimensions. In subsequent software-based steps, the crowns and abutments are designed where the appropriate dimensions and layer thicknesses are optimally matched biomechanically and esthetically (**Fig. 19**). The occlusal relationship can also be simulated in the software via a digitalized silicone index or represented by scanning the cast of the opposing jaw (**Fig. 20**).

The final abutments are ground and sintered from zirconia blanks (inCoris ZI Meso, Sirona) and bonded to CAMLOG® titanium bases CAD/CAM according to manufacturer's instructions (**Figs. 21 and 22**). **Figure 23** shows an example of a temporary PMMA crown (Telio CAD) on the distal abutment. The crowns have a very natural anatomical form due to the biogenic design and have a highly polished, biologically favorable surface.

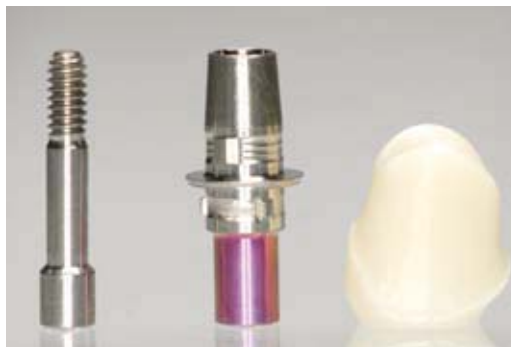### Exposure, abutment attachment and impression taking

Five months after implantation, the implants are successfully osseointegrated. The mucogingival junction has shifted toward the alveolar ridge as a consequence of the surgical intervention and must be corrected by means of a vestibuloplasty in the context of the exposure. The surgeon prepares corresponding flaps buccally and palatally for access to the alveolar ridge (**Figs. 24 and 25**). The flaps must not be

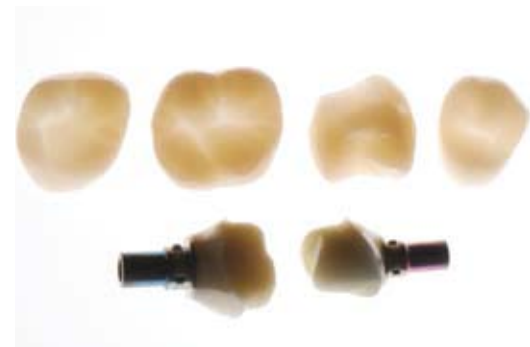



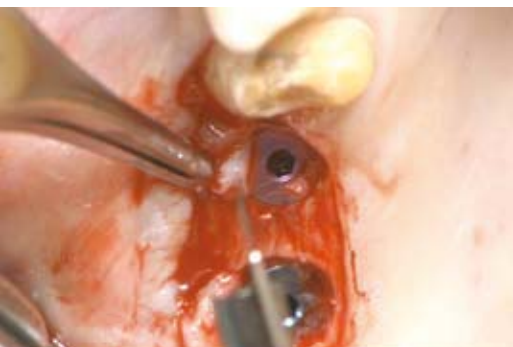**Fig. 20:** The opposing dentition is calculated from the digitized wax bite. The abutments show an adequate interocclusal space. For periodontal-prophylactic reasons, the future crown margins lie at the level of the gingiva.



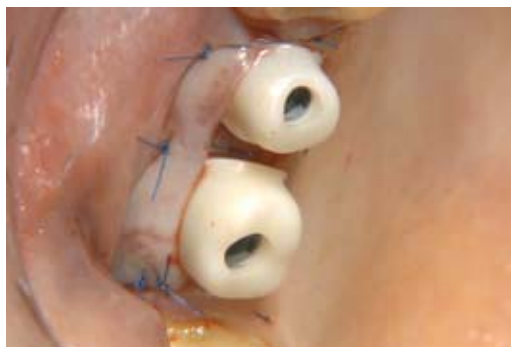**Fig. 21:** The finished zirconia abutment for the implant at position 15 before bonding, CAMLOG® titanium base CAD/CAM 4.3 mm and the individually milled abutment.



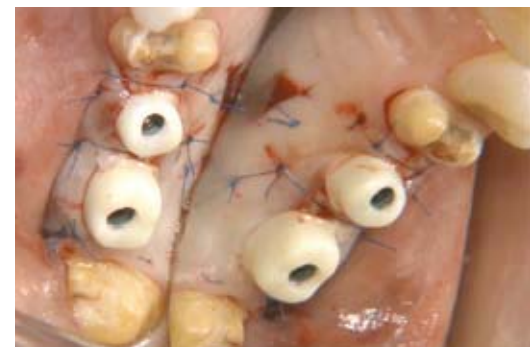**Fig. 22:** Bonded and polished zirconia abutments (bottom), highly translucent temporary PMMA crowns (Telio CAD) (top).



**Fig. 26:** In the next step, the implants are exposed using a roll flap with buccal pedicle. The buccal connective tissue can thicken and thus stabilize with the tissue over the cover screws.



**Fig. 27:** Suturing: The buccal split flap is fixed using backstitch sutures and then adapted using single button sutures. There is a soft tissue deficit mesial and distal to abutment 15, which is measured with a periodontal probe.



**Fig. 28:** Two epithelialized free connective tissue grafts are taken equilaterally from the hard palate and fixed in the defect areas. The equigingival position of the cervical "preparation margin" can be seen palatally (image mirrored palatally).

perforated especially in the area of buccal implant shoulders. He then exposes the implants using roll flaps (**Fig. 26**). After removing the cover screws, the interiors of the implants are flushed with sterile saline and the final abutments screwed in at a torque of 20 Ncm.

The flaps can now be fixed around the abutments using backstitch and single button sutures (**Fig. 27**). The lack of soft tissue between the abutments is replaced by free mucosal grafts from the palate and sewn into place (**Fig. 28**). The temporary PMMA crowns are tried in and the function and approximal contact points checked. Before cementation, cotton pellets are inserted in the screw channels, so that the screws can be loosened again before the final restoration if necessary. Only then are the screw channels sealed with light-cured composite and the crowns cemented temporarily (**Fig. 29**).

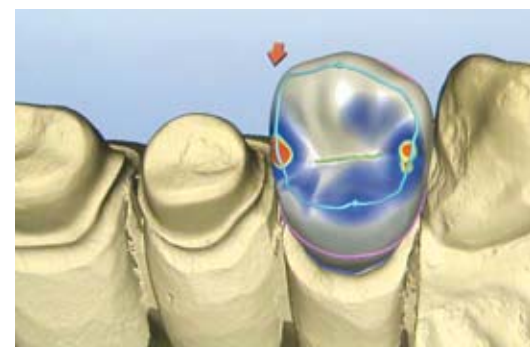
An impression is taken three months later after substantial healing of the soft tissue. The preparation boundaries are adapted to the new soft tissue situation with a rotating fine diamond bur. This differs

slightly from that in the software due to healing (**Fig. 30**). **Figure 31** shows the results of the double-mix impression.

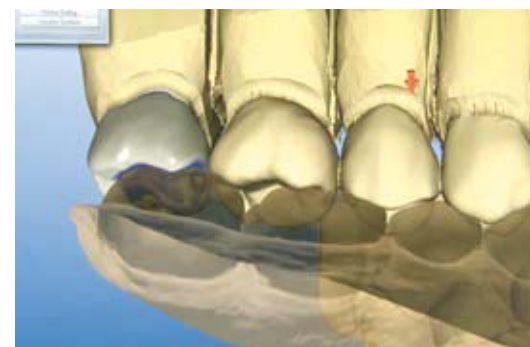### Fabrication and insertion of the final crowns

Based on the impression, the dental technician creates a new master cast, which is scanned by the strip light scanner. He checks step by step the preparation boundaries of the natural stumps and abutments and defines them on the screen. The biogenerically designed crowns are then called up and using the wax-up tool, optimized in the software anatomically and functionally (**Fig. 32**). The previously scanned cast of the opposing jaw can be used again to check the correct interocclusal distance and the occlusion (**Fig. 33**).

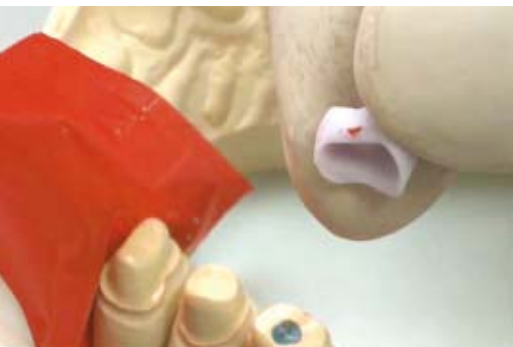It only takes about ten minutes to shape a lithium disilicate crown in the milling unit. Crowns made of this material do not shrink significantly after sintering and can therefore be inserted fire-polished if desired. Sintering and final firing can be carried out in one firing process. In the



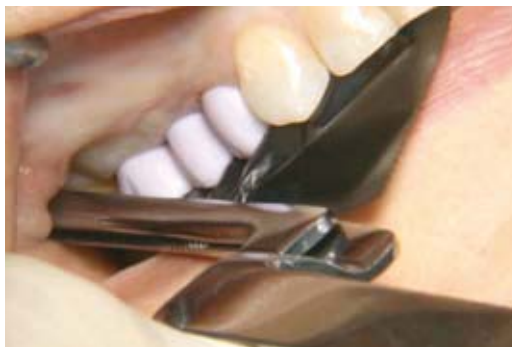**Fig. 32:** The master cast is digitalized in the laboratory and the final crowns designed on the screen.



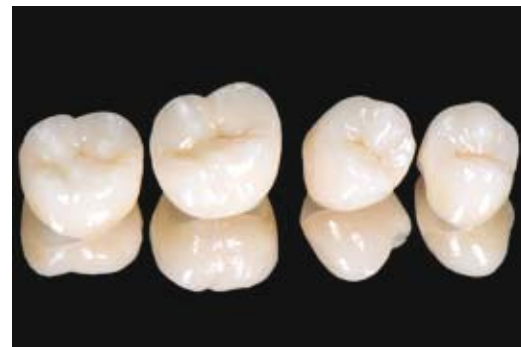**Fig. 33:** The occlusal relationship is also easy to check virtually.



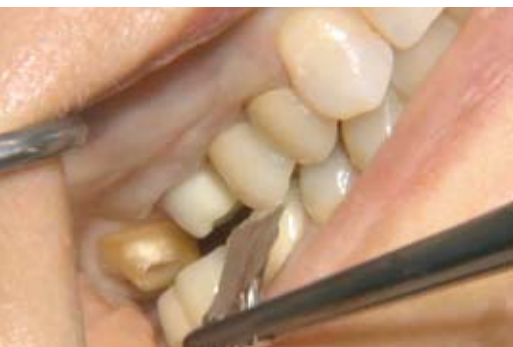**Fig. 34:** After milling the final lithium disilicate crowns, the approximal (image) and functional contacts are checked in the laboratory. This is possible because the material is not subject to any clinically relevant shrinkage as a result of sintering.



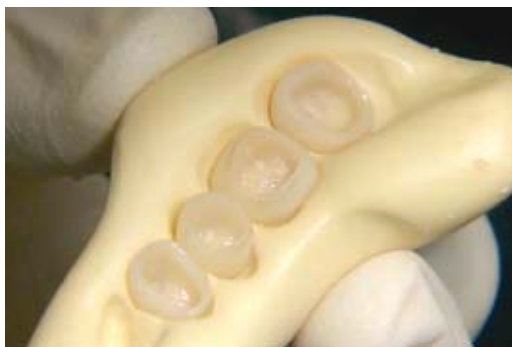**Fig. 35:** For safety reasons, the fired lithium disilicate crowns are also tried in the patient's mouth before finishing and function checked. It is easier to further mill the material at this point than after sintering.



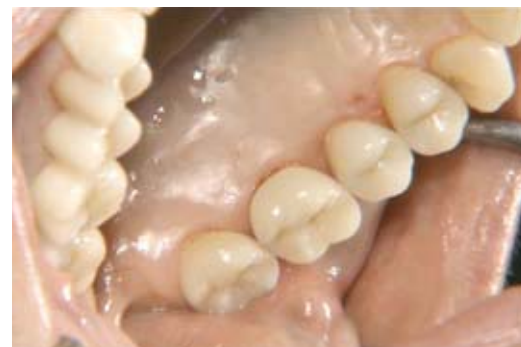**Fig. 36:** The painted and sintered final lithium disilicate crowns after finishing in the laboratory. The restorations were designed in a manner that supports the cusps and in the correct thickness.



**Fig. 37:** Check of the occlusion with shim stock foil. After any possible corrections, the surface of the crowns must again be carefully smoothed and polished.



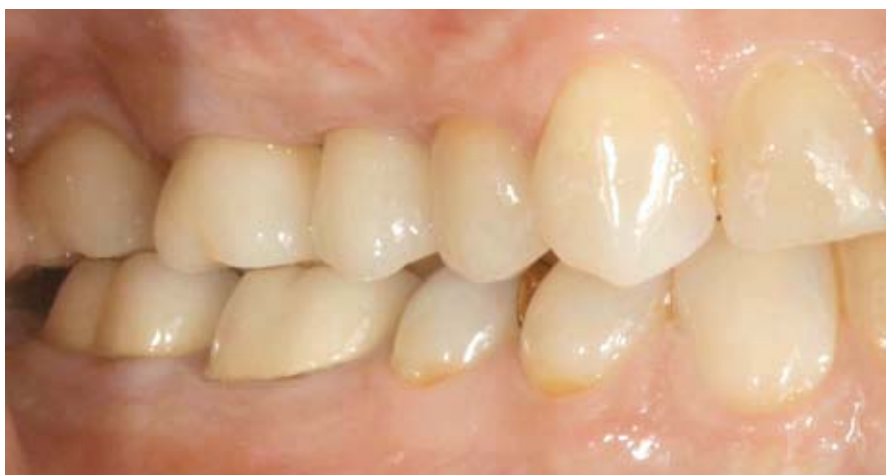**Fig. 38:** After trying in the finished crowns, an index made of kneading silicone can be prepared. This is used to protect the crowns while preparing for cementation and to keep them in the right order.



**Fig. 39:** After fitting the final crowns using a dual-curing composite, the gingiva is slightly traumatized. The removal sites of the free mucosal grafts are already well-healed.

example of our patient, the sintered crowns are first checked on the cast before the final firing (**Fig. 34**) and then in the mouth (**Fig. 35**) for the correct approximal and functional contacts. Only then is the final design carried out in the laboratory (**Fig. 36**).

Before final insertion of the crowns, the approximal (**Fig. 37**) and functional contacts are checked again on the patient. Corrected ceramic surfaces must be carefully smoothed and polished to prevent plaque adhesion and biomechanical weakening. The crowns are then fixed adhesively (**Figs. 38 and 39**). **Figure 40** shows the esthetically and functionally successful results.



**Fig. 40:** Lithium disilicate next to hydroxylapatite: The crowns on teeth 17 and 14 and implants 15 and 16 blend in very nicely.

## FURTHER READING

- [1] Abrahamsson I, Berglundh T, Lindhe J. The mucosal barrier following abutment dis/reconnection. An experimental study in dogs. *J Clin Periodontol* 1997;24:568-572.
- [2] Beuer F, Schweiger J. Einzelzahnkrone gemäß München-er Implantatkonzept. *Der Freie Zahnarzt* 2012:78-84.
- [3] Welander M, Abrahamsson I, Berglundh T. The mucosal barrier at implant abutments of different materials. *Clin Oral Implants Res* 2008;19:635-641.
- [4] Schweiger J, Beuer F, Stimmelmayer M, Edelhoff D. Wege zum Implantatabutment. *dental dialogue* 2010;11:76-90.

[5] Wilson TG. The positive relationship between excess cement and peri-implant disease: a prospective clinical endoscopic study. *J Periodontol* 2009;80:1388-1392.

[6] Scarano A, Piattelli M, Caputi S, Favero GA, Piattelli A. Bacterial adhesion on commercially pure titanium and zirconium oxide disks: an in vivo human study. *J Periodontol* 2004;75:292-296.

[7] Stimmelmayer M, Stangl M, Edelhoff D, Beuer F. Clinical prospective study of a modified technique to extend the keratinized gingiva around implants in combination with ridge augmentation: one-year results. *The International journal of oral & maxillofacial implants* 2011;26:1094-1101.

## Discussion

The method shown is an example of state-of-the-art, team-oriented implant prosthetics with highly developed hardware. All individual steps are methodologically, technically and chronologically coordinated. Only then is this time-saving and biologically consistent treatment possible. The esthetic result is positive even where the bar is not as high as in the front in the posterior region. Therefore, the authors specifically recommend this procedure for the posterior region [2]. The procedure can be carried out with or without augmentation, where a 2-stage procedure is recommended for the former.

The starting point for this example was the desire of the patient to be treated in as few sittings as possible. The dental team took this into account by registering the three-dimensional implant positions immediately after insertion. This allowed the team to insert the final abutment immediately. Further sittings to replace healing caps and to transfer the round profile of the healing caps to an anatomically correct emergence profile

were saved according to the patient's wishes.

Securing the final abutments at the time of exposure also has potential biological advantages. The once established connective tissue attachment does not have to be destroyed again, which bodes well for the prognosis of the peri-implant situation according to preclinical studies [1]. However, this hypothesis has not yet been confirmed in clinical studies. As a result of the CAD/CAM methodology used, it was also possible to best design the abutments with respect to the emergence profile and the position of the subsequent crown margin ("preparation margin") [4]. The risk of any remaining cement damaging peri-implant tissue is thereby reduced [5]. Should the position of the crown margin still change after the soft tissue has healed, additional finishing can easily correct the change.

Another plus is the use of zirconia as the abutment material in the example shown. This material has proven very favorable with respect to bacterial attachment and inflammatory behavior

of the peri-implant tissue [3,6]. This also applies in comparison to titanium. Even the temporary restorations and final crowns have a positive effect on soft-tissue healing and long-term peri-implant health due to their natural design and their material properties.

Not least, a careful surgical technique contributes to a highly esthetic and long-term stable result. The vestibuloplasty carried out in this example is a routine intervention used to achieve better hygienic potential of the implant-supported restorations [7]. Finally, the economic aspect should be noted as the time savings and absence of healing caps or individualized temporary abutments help reduce costs [2]. Notwithstanding the above, the Munich implant concept shows that proven dental know-how goes very well with state-of-the-art technology.

## AUTHORS



### PD Dr Florian Beuer:

Study of dentistry at Ludwig Maximilian University of Munich. 2002, conferral of doctorate. After two years in private practice, switched in 2002 to the Dental Prosthetics Polyclinic (Director: Prof Dr Dr h.c. Wolfgang Gernet). 2007/2008, visiting scholar at the Pacific Dental Institute, Portland/Oregon, USA with Prof John A. Sorensen. 2009, postdoctoral lecturing qualification. Work and research priorities: metal-free restorations, implant prosthetics, CAD/CAM, digital workflow, practice-based research, medical educational research. PD Florian Beuer is a management board member of the German Association of Esthetic Dentistry (DGÄZ) and the Working Group for Ceramics (AG Keramik).



### Dr Michael Stimmelmayer:

After the state examination in dentistry at the University of Regensburg, switched to Ludwig Maximilian University of Munich as a research associate. 1992, conferral of doctorate. 1997, specialist designation as oral surgeon and senior physician at the Department of Prosthodontics. 2000, own practice in Cham with an emphasis on implant dentistry and specialization in periodontology.



### Josef Schweiger:

Completed training for dental technicians after final secondary-school examinations. After ten years of dental technician work in different laboratories, laboratory manager since 1999 at the Dental Prosthetics Polyclinic in Munich. There dental management of several studies on all-ceramic systems; has published numerous technical papers on the subject of CAD/CAM and advanced ceramics in dental applications. Josef Schweiger is a board member of the German Society for Computational Dentistry (DGCZ).



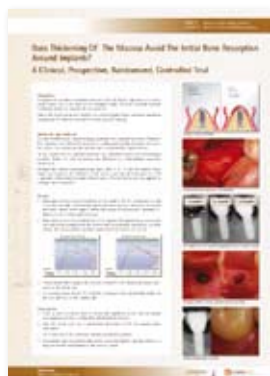## POSTER EXHIBITION AT THE INTERNATIONAL CAMLOG CONGRESS 2012 NOW ONLINE

Would you like to see the ICC-2012 poster exhibition again? Now you can conveniently online without any stress.

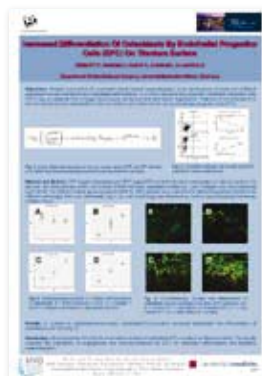
Take a break:

<http://www.camlogfoundation.org/awards/poster-competition-2012/index.html>.

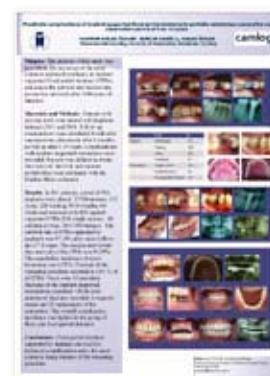And while visiting the CAMLOG Foundation homepage, do not forget to also read the entry conditions for the CAMLOG Foundation Research Award 2012/2013.



**1st prize:**  
Hehn A, Schlee M.



**2nd prize:**  
Ziebart T, Boddin A, Pabst A,  
Klein MO, Al-Nawas B.



**3rd prize:**  
Kulak-Özkan Y, Akoglu B,  
Özkan Y.



## IN GOOD COMPANY — AS A MEMBER OR AUTHOR OF CAMLOGCONNECT, THE ONLINE COMMUNITY FOR CAMLOG USERS

CamlogConnect is picking up speed and now numbers more than 1750 members. The interactive Internet platform for CAMLOG users went live just one year ago! Worldwide, more and more dentists, surgeons and implantologists take advantage of the free offering of the online community for self-directed continuing education and to expand their professional network.

As international as the visitors who visit the Internet platform daily, so is the ever-growing authorship. Experienced professionals and newcomers impressively document and describe their treatment successes. The international authors include Dr Tony Regenato, a young dedicated specialist from Chicago, who does not have his own practice, but is called upon by dentists in cases of particularly demanding indications. Many talented European capacities of implant dentistry are represented on CamlogConnect, too. Dr Tabuenca of Spain, who directs several practices, has posted interesting

articles. Of course, we enjoy following many more successful treatment cases of Dr Illaria Francini (Italy) and Dr Guido Petrin (Germany) on CamlogConnect. We are pleased to welcome new author Dr Kimmo Karstoft from Denmark, who in his debut impressively shows how he replaced two cuspids in an edentulous mandible with CAMLOG implants. If you want to present your own treatment cases using CAMLOG implants and prosthetic components, please contact Dr Peter Hunt, the CamlogConnect editor in chief at [www.camlogconnect.com](http://www.camlogconnect.com). Peter Hunt will take care of the technical preparation and

translation of your image material. Take advantage of this excellent opportunity to showcase your own work and to connect with leading colleagues – or to simply be inspired by ideas and examples for your own daily work.  
*Learn, share & enjoy.*

CAMLOG looks forward to your publications.



## TEAM@WORK.2020 – ON FUTURE TECHNOLOGIES AND THE PRINCIPLE OF HUMANITY



A forward-looking and open-minded attitude towards modern technology and a high sense of tradition and traditional values are not mutually exclusive.

A clear example of this is Switzerland where the Swiss Dental Technology Congress 2012 was held in September of this year with key involvement and at the initiative of CAMLOG.

“Team@work2020” was the event motto, making clear that the congress was about cooperation between dentists, partners, colleagues, employees, etc. in addition to future technologies. “Teams” come in different sizes – common to all is that functioning cooperation is of paramount importance for the overall results of the work.

Dr Alex Schär, Member of Executive Board at CAMLOG Biotechnologies AG, Basel, welcomed about 200 dental technicians from throughout Switzerland. Beat Kunz, who played an important role at the first Swiss Dental Technology Congress, opened the lecture program with the topic: “2010: Congress conventional-virtual – 2012: What has changed?”. Changes can be noted in the dentist (competition among themselves, marketing), patients (more decisive,

more mobile) and dental technicians (CAD/CAM, skills development). After the first speaker, Beat Kunz in his role as moderator thanked the patrons of the congress and the exhibiting firms for their participation and support.

### Dental technology: Status quo

Occupational policy is also a topic in Switzerland. The “Branchenbild Zahntechnik” (Dental technician industry profile) was very precisely and vividly portrayed by Christian Hodler, the Secretary General of VZLS (Federation of Swiss Dental Laboratories). His foray into the industry was analytical, clear and he was able to provide approaches to further development of dental technician entrepreneurship in Switzerland.

The presentation by PD Dr Florian Beuer und Josef Schweiger was professionally stimulating. “The digital team workflow in daily practice,” suggests much. Both speakers work at Ludwig Maximilian University of Munich and use no less than 14(!) CAD/CAM systems in their everyday work. Individual CAD/CAM-fabricated abutments have many advantages over prefabricated and cast-on abutments. The variant preferred by the Munich residents is a two-part bonded abutment consisting of a titanium base and a zirconia abutment. The “academic discussion” around the adhesive joint is of no importance for the practice. In the second part of their presentation, they delved further into the “Munich Implant Concept” and “digital veneering” (sintered composite technology, so-called CAD-on technique).



### The new generation of dental technicians

Dipl.-Ing. Michael Tholey ("Colors, Firing, Chipping") and Dipl.-Ing. Bogna Stawarczyk ("Everything a Question of Material") delved deep into the world of materials science and were able to provide several practical tips for handling zirconia, veneering ceramics, PMMA and CAD/CAM plastic.

"What I show you today is handcraft, true handcraft," said Andreas Nolte opening his presentation. This did the dental technician soul good and expressed his belief to the point. Esthetics can not be reproduced by pressing a button, but requires intensive expert work on and with the patient, empathy, thorough analysis and planning and a trained eye. The Münster resident calls this "Low Tech" although he often uses a computer-assisted process in the dental implementation. But they are not an end in themselves, rather a means to an end. His brand is beautiful ceramics realized in functional restorations whether in the form of non-prep veneers, which

he calls "enamels" or with implant reconstructions, for which he can provide clear recommendations in which cases they should be screwed in, cemented or used as a combination of both. His credo: "You can wear anything with beautiful teeth," he illustrated in many case examples.

### The digital r-evolution

The dental impression is a nerve-racking affair for doctor and patient. "Scan or impression" was thus the question for PD Dr Irena Sailer and MDT Vincent Fehmer. With the provocative thesis: "A new idea is ridiculed in the first phase, antagonized in the second phase and in the third phase, everyone was excited about it from the beginning," as they draw attention to the question. However, they had to admit that desire and reality do not always coincide and the optical impression of individual quadrants work very well, but entire jaws are problematic. Furthermore, the economic justification is not yet given and yet other limiting factors such as surface quality of casts stereolithographically generated played a role.

MDT Ralph Riquier dealt with the issue of "Digital Forecasts" with a practical orientation and visionary at the same time, where it was important to him "to not go to far forward," but to build his line of argument on the basis of facts. The forecasts were broken down into the material, production, CAD software and workflow. Each of these elements was analyzed on its own. Monolithic ceramics, high-performance plastics, milling and generative processes are keywords of the past and future. However, in the opinion of the speaker, the greatest potential lies in the field of CAD software (interaction of software, integrity of external data) and the further development of process chains (networking to server portals, cloud solutions). The good news is that portals will be more controlled and regulated in the future, but it is apparent that economic CAM fabrication will also be possible in small laboratories.

## Special Speaker

Beat Krippendorf, lecturer in strategic and operational marketing, provided a fantastic end to the Swiss Dental Technology Congress 2012. His main focus is the "principle of humanity" and the belief that good relationships affect business success sustainably. According to Krippendorf, good relationships are less a question of technical competence and more a question of attitude and personality or in his own words, the "own culture". "People do not care how much you know until they know how much you care," is just one of his striking theses.

With this, an outstanding event came to a deeply inspiring and motivating end. We can already look forward with eager anticipation to the continuation of the Swiss Dental Technology Congress and the coming motto!



## HIGHER, FASTER, FARTHER!

The 35<sup>th</sup> International Dental Show will be held from 12–16 March 2013 in Cologne, Germany. With more than 110,000 show visitors and 2,000 exhibitors, this event is undisputed as the world's leading exhibition for the dental industry. IDS provides an ideal platform to learn about the latest products and trends.

Of course, CAMLOG will also be present as usual in 2013 with an inviting booth in hall 11.3. Following the positive development of the CAMLOG business trend, we have expanded our booth space to 235 m<sup>2</sup>. CAMLOG is looking forward to welcoming our customers personally to our booth and to present a few product innovations on site. Personal contact with you is also clearly in the foreground at IDS 2013. We aim to maintain our lounge in comfortable surroundings as a deliberate contrast to the exhausting bustle of the show.

And experience the premiere of our new communications presence live in Cologne. *Who knows, maybe you can be inspired by it and even accept a small role?* You'll be in for a surprise in any case – we guarantee it! Without giving away too much already, we can assure you at this point that CAMLOG will be at IDS with a remarkable innovation. But we'll talk about that more at a later time – in March 2013 in Cologne.

So you see, a visit to the CAMLOG booth at IDS in Cologne this year will be well worth your time.

You'd be well served to reserve the time in your calendar now to visit CAMLOG in Hall 11.3 from 12 – 16 March 2013. Booth A10-B19. We look forward to seeing you.

