

Special Edition

logo

Issue 7 | 2014  
CAMLOG Partner Magazine

5<sup>TH</sup> INTERNATIONAL

**CAMLOG CONGRESS**

26<sup>TH</sup> to 28<sup>TH</sup> JUNE 2014

**VALENCIA, SPAIN**



### Dear readers,

from 26<sup>th</sup> to 28<sup>th</sup> June 2014, the 5<sup>th</sup> International CAMLOG Congress will be held in fascinating Valencia under the motto "The Ever Evolving World of Implant Dentistry". The exclusive event location for the Congress – the Palau de les Arts in the Ciudad de las Artes y de las Ciencias, designed by the leading architect, engineer and artist Santiago Calatrava – has inspired the international scientific committee even more to provide an absolute top Congress program.

The objective of the congress is to convey the latest insights from research, clinical and private practice, so that all delegates can already apply these insights to their daily work on the Monday after the meeting. The core of the program consists of surgical and prosthetic concepts and recommendations based on the 1<sup>st</sup> and 2<sup>nd</sup> CAMLOG Foundation Consensus Report. These reports were – or will be – prepared by a renowned team of experts from 18 countries during meetings in the years 2013 and 2014. Personally speaking, I am proud that the 1<sup>st</sup> CAMLOG Foundation Consensus Report has been published online by the renowned Clinical Oral Implant Research Journal. The Consensus Reports serve as basis for questions relating to daily practice and these will be addressed at the Congress in Valencia both from an academic as well as clinical, practical point of view.

The Congress sessions "Multifactorial decision-making" and "Controversial topics" cover and discuss current topics, with which you are confronted on a daily basis. A special highlight at the end of the Congress will be when we present case discussions on the topic "Complications – what can we learn from them?" with a voluntary panel discussion from the audience. I hope that as many interested parties as possible will register to participate on the first day of the Congress.

If you want to expand your theoretical knowledge and/or practical experience in implant dentistry further, an opportunity will be provided to do so on the day before the actual Congress by participating in one of the nine offered practical "hands-on" or theoretical workshops. An Iberian symposium in Spanish for young scientists will be held on the same day. All as part of the CAMLOG Foundation philosophy with the objective of providing a platform for exchanging experience among young talents.

And not to forget: life is not only about working and learning, but also about caring for friends and celebrating occasions. This leads up to the next legendary Congress party in the fitting surroundings of a picturesque Spanish hacienda. Valencia not only has something for those eager to learn, its location on the Mediterranean Sea will also offer accompanying persons unforgettable options, as you can see from the Congress brochure.

I already look forward to welcoming you from 26<sup>th</sup> to 28<sup>th</sup> June 2014 in Valencia at the 5<sup>th</sup> International CAMLOG Congress.

Dr. Alex Schär  
CAMLOG Foundation  
Member of the Foundation Board





**WIN &  
JOIN US  
in Valencia**

## WIN AN INVITATION

### TO THE 5<sup>TH</sup> INTERNATIONAL CAMLOG CONGRESS!

Since its take-off in 2012, CamlogConnect has gained a considerable reputation among CAMLOG users. More than 2,700 dental professionals have already joined the CamlogConnect community. This outstanding success gives us the opportunity of launching a CamlogConnect prize competition in connection with the 5<sup>th</sup> International CAMLOG Congress.

To take part in the competition, please submit a CASE, VIDEO or TIP presentation until March 31<sup>st</sup>, 2014. Participants can be general practitioners, specialists, dental technicians, and students. For editing, translation and layout of the competition material, the CamlogConnect team offers you their full support.

### PRIZES

CAMLOG will award 5 prizes for the best cases. The prizes include:

- admission to the 5<sup>th</sup> International CAMLOG Congress in Valencia from June 26<sup>th</sup> through 28<sup>th</sup>, 2014 including participation in the party
- plus a grant of € 500.– for travel and accommodation cost.

For more information about the prize competition, visit:  
[www.camlogconnect.com](http://www.camlogconnect.com)

Learn, share & enjoy





## 5<sup>TH</sup> INTERNATIONAL CAMLOG CONGRESS 26<sup>TH</sup> TO 28<sup>TH</sup> JUNE 2014 IN VALENCIA



Following four successful CAMLOG Congresses in Germany and Switzerland with over 1,000 participants attending each congress, we are now venturing south to the warm climate of the Spanish Costa del Azahar, to Valencia, Spain's third largest city. This city of the arts and sciences offers an excellent base for yet another unforgettable Congress.

Participants will be able to enjoy the unique contrast between antiquity and modernity, a contrast that is special to Valencia. The event location, the Palau de les Artes, is Europe's largest opera house and we are proud to be the first implant manufacturer ever to hold our 5<sup>th</sup> International CAMLOG Congress there.

### Ten practical/theoretical workshops set the mood

The large demand for and excellent ratings of the past congresses have encouraged us to extend the number of workshops. On the Thursday prior to the actual congress, four practical workshops with limited places and three theoretical workshops will be held. The highly current topics of the practical workshops range from "Implant planning in using 3D-printing" to "Peri-implant complications" and from "Maxillary sinus grafting" to "Microsurgery techniques".

The theoretical workshops look at questions such as "Which surgical measures lead to long-term success?", clarify queries in "Prevention and maintenance therapies" and demonstrate the option of "greater efficiency in implant dentistry" using the revolutionary iSy Implant System. Experienced CAMLOG specialists lead the workshops and guarantee further education at the highest level.

Additional international workshops will also be held on the Thursday, including a full-day symposium in Spanish. We recommend early registration as experience has shown the practical workshops to be booked out well in advance.

### "The ever evolving world of implant dentistry"

The scientific committee of the CAMLOG Foundation with its top level experts has prepared a varied program. Under the chairmanship of the two Congress presidents Prof. Dr. Mariano Sanz and Prof. Dr. Fernando Guerra, some 48 international speakers well versed in research, teaching, as well as clinical and practical aspects will be presenting a representative cross-section on the state-of-the-art in implant dentistry.

The surgical/prosthetic concepts and recommendations developed by a team of experts from 18 countries for the 1<sup>st</sup> CAMLOG Consensus Report are at the core of the program. The report has recently been accepted for publication by the renowned Clinical Oral Implant Research Journal. The Consensus Report serves as basis for questions relating to daily practice and these will be addressed at the congress in Valencia both from an academic as well as clinical, practical point of view.


### The total variety of implant dentistry at a glance

Friday takes us without delay into the impressive realms of complexity in implant dentistry. Under the heading "Multifactorial decision-making", topics such as procedures in periodontally impaired patients, the necessity of template guiding, strategic procedure for angled implants and immediate loading, functional and esthetic considerations for biotype categories, strategies for implant loss etc. are presented and discussed.

Implant positioning, which is an essential part of the Consensus Report, starts the second session of presentations with the title "Surgical concepts and recommendations":

- Where, how many and when should implants be placed?
- Which strategies are successful?
- What are the biological reactions?
- And what are the factors for success?

These and many other questions are answered competently and evidence-based. During the afternoon, the time period up to loading of the implant moves into the focus of the presentations. This entire session is based on the CAMLOG Consensus Report and covers prosthetic concepts and recommendations. Whether immediate loading or platform switching, the presentations will certainly



deliver major insights and immediate benefits for your daily practice.

### But it is not only about work

And to ensure that your work-life balance stays reasonably intact after a long day of attention and concentration: the meanwhile legendary series of our Congress parties will continue in Valencia with a Spanish flavor — on an authentic hacienda! The night will be short, the atmosphere unique, that we can guarantee!

### And the winner is...

Saturday starts somewhat later than on Friday at 9.30 am in the congress hall with six short reports on current research projects and the award ceremony for the CAMLOG Foundation Research Awards. Also during this morning, the winners of the newly added poster competition will be chosen. Conditions for entry are given in the congress brochure or online at [www.camlogcongress.com](http://www.camlogcongress.com)

### Support in difficult decisions

After the coffee break, controversial topics are the focal point of the program. Renowned speakers illustrate the advantages and disadvantages of short implants, the meaningfulness of digitalization, whether augmentation is required or not and whether one-piece abutments make sense.

The finishing touch at the end of the congress consists of several case discussions on the controversial issue "Complications — what can we learn from them?" with a voluntary panel discussion from the audience. This type of case discussion is unique, and we are already full of anticipation to see if YOU will be among the more adventurous persons we can welcome to go on stage in Valencia.

### Diversified supporting program

Valencia offers exceptional diversity and exciting contrasts, all within manageable surroundings. From the Palau de les Arts, the event location, to the old town center takes just 20 minutes on foot. The footpath takes you through the dried-out river bed of the Túria. Alternatively, you can also discover the city and surroundings by bicycle. The entire city offers numerous exemplary cycling routes, making a bicycle tour an attractive proposition.

If you want to stay in the vicinity of the Palau, there is plenty of entertainment or further education available in the futuristic world of the Ciudad de las Artes. Among other things, this includes the science museum and the Oceanogràfic: the largest aquarium of marine and coastal life in the oceans. And, of course, the "real" sea is not far away either! Our congress support program offers you and your accompanying persons a number of options, an outing by boat through the Albufera National Park or a catamaran cruise for sun lovers.


### Fair prices

CAMLOG customers have for many years been accustomed to our fair prices and well established price guarantees. We have applied this principle to the congress fees, too, the prices remain unchanged. The congress fee for early bird registration by the end of February 2014 remains at only € 480. Students, university assistants as well as dental professional staff are entitled to reduced fees of € 240. The legendary party is subject to a cost contribution of € 110 per person and you will no doubt be delighted at the largely moderate and appropriate prices for hotel accommodation.

### Registration

You can register at any time on our homepage [www.camlogcongress.com](http://www.camlogcongress.com) or look up all the information. The QR-code provides direct access to the congress website.

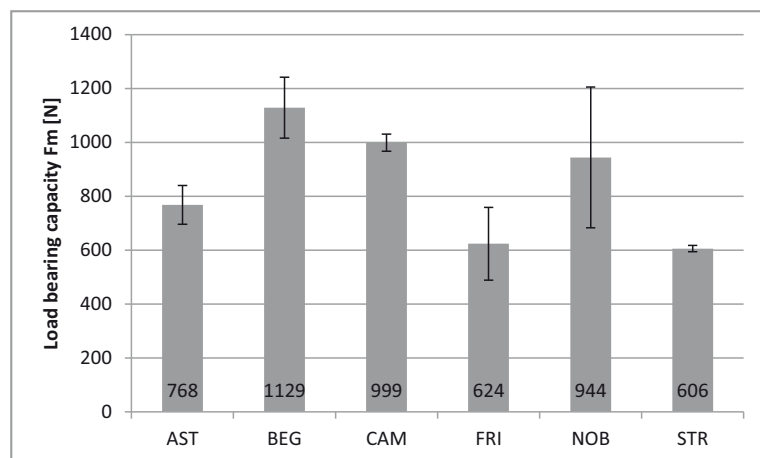




## "CAMLOG AND SCIENCE" — NEW BROCHURE AVAILABLE SOON

Although first scientific papers on titanium dental implants have been available since their commercialization approximately five decades ago, the need for scientific documentation is nowadays even more important for the development of new products, their commercialization and follow-up.

The profound scientific documentation of the three Implant Systems developed, manufactured and marketed by CAMLOG reflects the company's state-of-the art research and is the result of many projects initiated either directly by CAMLOG Biotechnologies AG, Basel, or by independent research groups and/or assignments supported through grants of the CAMLOG Foundation ([www.camlogfoundation.org](http://www.camlogfoundation.org)).



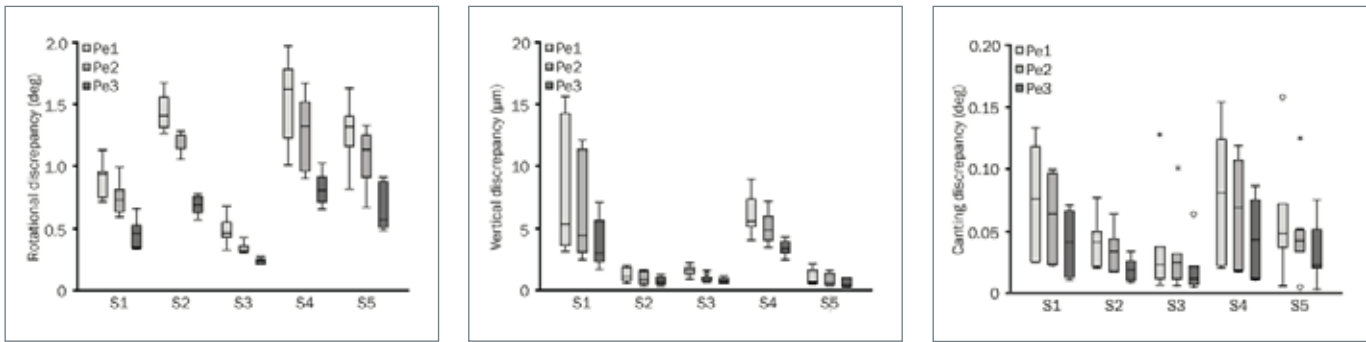
**Fig 1:** Load bearing capacity (Fm) versus implant-abutment connection type. Means and standard deviations are given. AST — Astra Tech, BEG — Bego, CAM — CAMLOG®, FRI — Friadent, NOB — Nobel, STR — Straumann®. Adapted from Dittmer et al. (2011).

Along with the progress of research in the field of implant dentistry, the quantity of scientific data has continually been increasing and strongly influencing product development of the CAMLOG Group. Associated with the intensification of scientific knowledge, high-precision manufacturing technologies have also advanced thus leading to the improvement of standard abutment restorations and the recent

introduction of platform switching. CAMLOG offers implants with identical SCREW-LINE outer geometries but with two different implant-abutment connections: CAMLOG® implants with the Tube-in-Tube™ and CONELOG® implants with the conical CONELOG® connection. This aspect enables implantologists to insert implants of two systems, the CAMLOG® and the CONELOG® Implant Systems, by using only one surgical kit.

In adequate cases, bone augmentation can be avoided by using short implants. Today, this is becoming a more and more relevant alternative treatment concept. With the introduction of the highly precise and mechanically stable CONELOG® implant-abutment connection, CAMLOG additionally offers such a short 7mm implant.

Because science is rapidly evolving, the CAMLOG brochure "Science and Practice" has been reviewed, updated, and renamed as "CAMLOG and Science". This new brochure includes summaries of important scientific papers dealing with the various CAMLOG products. Also included are illustrations of in vitro, preclinical and clinical data from papers that are the result of profound research of leading scientists in the field of implant dentistry. The following lines are a short summary of this brochure and intended to whet the reader's appetite.



**Fig 2:** Rotational deviations (A), vertical deviations (B), and canting discrepancies (C) after repeated detachment and re-attachment procedures. Median values. Pe1, Pe2, Pe3 test persons performing the test procedures. S1 Straumann® Tissue Level, S2 SteriOss, S3 CAMLOG®, S4 Astra Tech, S5 Replace™ Select. Adapted from Semper-Hogg et al. (2013).

## Solid clinical results

High success rates in single restorations, in partially edentulous patients, and in edentulous jaws were reported in clinical studies using sand-blasted, acid-etched Promote®-surfaced implants from CAMLOG. Implant type, diameter or length, time of implantation or time of loading did not have a significant influence on the implant success rate. Summaries of the findings were published in logo 24 and logo 25 (German Editions). The reasons for these good results appear to be related to the specific features of the Implant Systems provided by CAMLOG. For example, the precise fit and the excellent mechanical stability of their implant-abutment connections, the specific implant designs and surface structures. Evidence for this is provided in several in-vitro and animal studies.

## Stability of implant-abutment connections

Implant-abutment connection stability is strongly influenced by precision of fit, connection design and manufacturing precision. Several research groups analyzed and compared the stability of different implant-abutment connections (Reinert and Geis-Gerstorfer 2007; Edinger et al. 2007; Semper et al. 2009 and 2010; Dittmer et al. 2011 **Fig. 1**). The CAMLOG® Tube-in-Tube™ connection with its cam-groove index design exhibited favorable results in these analyses with regard to precision in reproducing the abutment position, rotational fit as well as load distribution and load-bearing capacity. Although conical connections

may have design-related disadvantages regarding precision of fit and load distribution, the CONELOG® implant-abutment connection demonstrated in studies evidence of high-precision manufacturing and superior positional stability when compared to other conical connections (Semper-Hogg et al. 2013 and **Fig. 2**).

## Loading capacity, sealing and fit of modern implant-abutment connections and prostheses

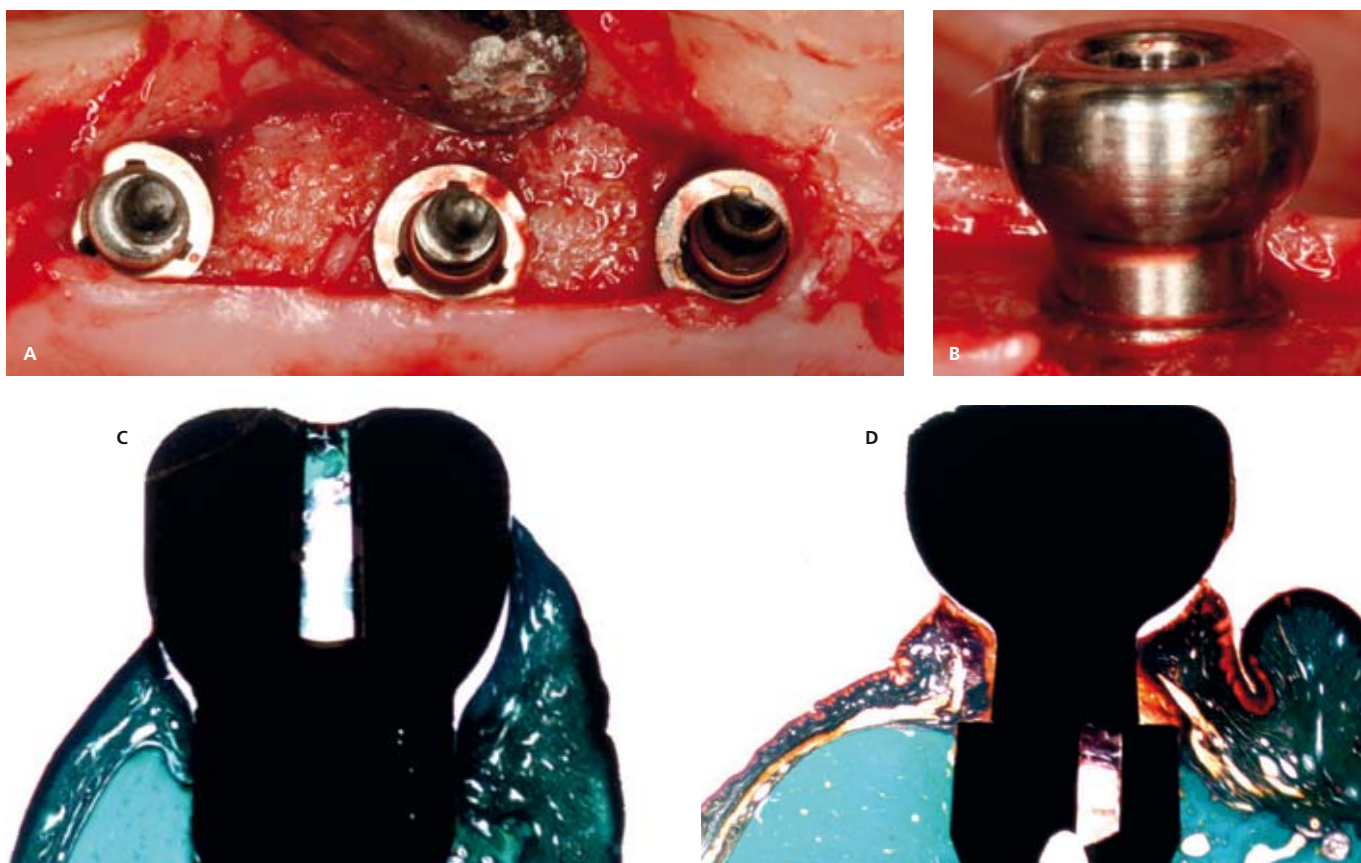
There is general agreement that a two-piece implant without micro-gap and without micro-movements still has to be developed. Even conical implant-abutment connections have micro-gaps, which increase under loading. For the CAMLOG® Implant System, very favorable load capacity has been demonstrated.

Numerous studies were performed on prosthetic aspects of the Implant Systems provided by CAMLOG: Although the use of ZrO<sub>2</sub> abutments on titanium implants has various clinical advantages, increased wear and abrasion may be expected compared to titanium abutments. Therefore the recommendations for use and processing of ZrO<sub>2</sub> abutments should be followed (Stimmelmayer et al. 2012). When using CAD/CAM technologies, a precise fit of scanbodies during implant transfer between the original and the cast is a prerequisite for achieving an optimal passive fit of the prosthetics. Glass-ionomer cements should be used for semi-permanent cementations, polycarboxylate or composite resin cements are better suited for permanent

cementations (Mehl et al. 2012a, 2012b).

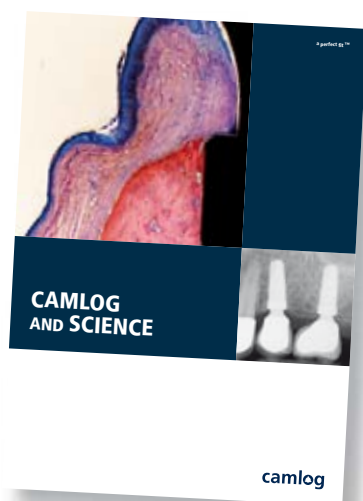
## Pre-clinical studies

Design modifications to the CAMLOG® and CONELOG® implants systems were systematically tested pre-clinically. The enlargement of the coarse neck area of SCREW-LINE implants (Promote® plus design) was shown to improve osseointegration (Schwarz et al. 2008). Bacterial micro-leakage does not seem to play a role in marginal bone resorption around CAMLOG® implants. Studies on the concept of platform switching demonstrated successful osseointegration of both standard and platform-switched implants (Becker et al. 2007, 2009). Repeated abutment dis- and reconnection during the healing phase may impair stability of the hard and soft tissue both with Ti and ZrO<sub>2</sub> abutments (Becker et al. 2012, **Figs. 3 A-D**). Vertical loading due to removal of cemented restorations does not impair stability when the implants are well osseointegrated (Mehl et al. 2013).



**Fig. 3A:** Implants (K-Series) inserted 0.4 mm supracrestal according to the standard surgical protocol. **Abb.3B:** Inserted implant covered with a nonmatching healing cap (platform switching). **Fig. 3C:** Implant with standard healing cap (control), histology after 6 months healing. **Fig. 3D:** Implant with nonmatching healing cap (platform switching), histology after six months healing. Bone loss is slightly reduced compared to the standard configuration.

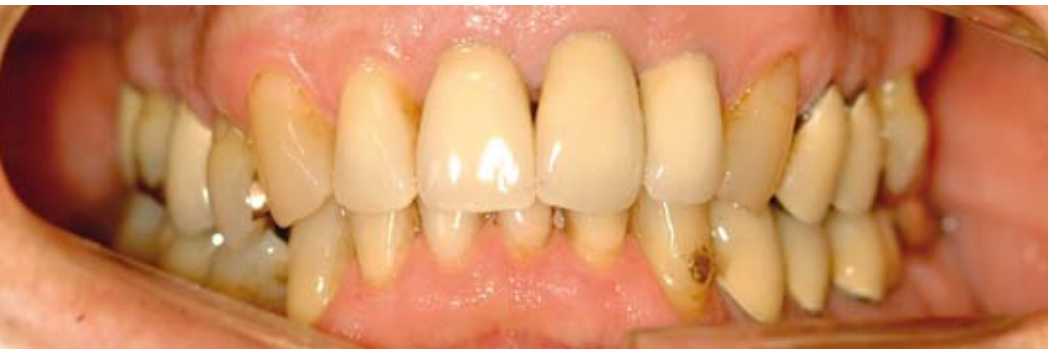With kind permission of Prof. Dr. F. Schwarz



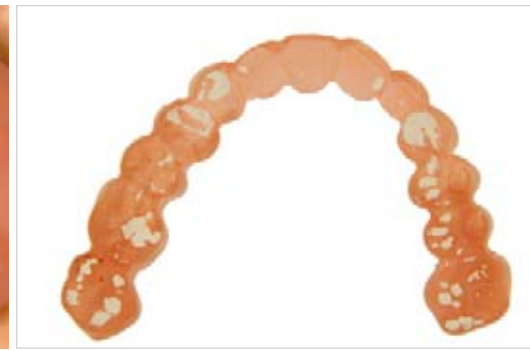## REFERENCES

- Becker J, Ferrari D, Hertel M, Kirsch A, Schaer A, Schwarz F. (2007) Influence of platform switching on crestal bone changes at non-submerged titanium implants: a histomorphometrical study in dogs. *J Clin Periodontol* 34 (12):1089-96
- Becker J, Ferrari D, Mihatovic I, Sahn N, Schaer A, Schwarz F. (2009) Stability of crestal bone level at platform-switched non-submerged titanium implants: a histomorphometrical study in dogs. *J Clin Periodontol* 36(6):532-9
- Becker K, Mihatovic I, Golubovic V, Schwarz F. (2012) Impact of abutment material and dis-/re-connection on soft and hard tissue changes at implants with platform-switching. *J Clin Periodontol* 39(8):774-80
- Dittmer S, Dittmer MP, Kohorst P, Jendras M, Borchers L, Stiesch M. (2011) Effect of implant-abutment connection design on load bearing capacity and failure mode of implants. *J Prosthodont* 20(7):510-6
- Edinger D, Kahler E, Hilgers R. (2007) Untersuchung der Rotationspassgenauigkeit. *BDIZ EDI konkret* 2:68-71
- Schwarz F, Hertel M, Bieling K, Becker J. (2008) Crestal bone changes at non-submerged implants (Camlog®) with different machined collar lengths. A histo-morphometrical pilot study in dogs. *Int J Oral Maxillofac Implants* 23:335-342
- Mehl C, Harder S, Schwarz D, Steiner M, Vollrath O, Kern M. (2012a) In vitro influence of ultrasonic stress, removal force preload and thermocycling on the retrievability of implant-retained crowns. *Clin Oral Implants Res* 23(8):930-7
- Mehl C, Harder S, Shahriari A, Steiner M, Kern M. (2012b) Influence of abutment height and thermocycling on retrievability of cemented implant-supported crowns. *Int J Oral Maxillofac Implants* 27(5):1106-15
- Mehl C, Becker ST, Acil Y, Harder S, Wiltfang J, Dabbagh-Afrouz AA, de Buhr W, Kern M. (2013) Impact of vertical loading on the implant-bone interface. *Clin Oral Implants Res* 24(8):949-56
- Reinert M, Geis-Gerstorfer J. (2007) Vergleichende Untersuchung zur Passgenauigkeit von prothetisch-zahn-technischen Komponenten verschiedener Implantatsysteme. *Deutsche Zahnärztliche Zeitschrift* 62:668-674
- Stimmelmayer M, Edelhoff D, Güth JF, Erdelt K, Happe A, Beuer F. (2012) Wear at the titanium-titanium and the titanium-zirconia implant-abutment interface: A comparative in vitro study. *Dent Mater* 28(12):1215-20
- Semper W, Kraft S, Krüger T, Nelson K. (2009) Theoretical optimum of implant positional index design. *J Dent Res* 88(8):731-5
- Semper W, Heberer S, Mehrhof J, Schink T, Nelson K. (2010) Effects of repeated manual disassembly and reassembly on the positional stability of various implant-abutment complexes: an experimental study. *Int J Oral Maxillofac Implants* 25(1):86-94
- Semper-Hogg W, Kraft S, Stiller S, Mehrhof J, Nelson K. (2013) Analytical and experimental position stability of the abutment in different dental Implant Systems with a conical implant-abutment connection. *Clin Oral Investig* 17(3):1017-23





**Fig. 1:** The initial situation revealed a deep bite situation, with a center line shifted to the right by four millimeters, with molars and anterior teeth requiring a replacement construction.



**Fig. 2:** Color abrasion on the BruxChecker® foils demonstrates clear overloading on tooth 47, ...

## STRATEGIC MOVEMENT OF TEETH WITH THE AID OF FINAL CAMLOG® IMPLANTS FOR RECONSTRUCTION OF FUNCTIONAL OCCLUSION

Dr. Gerd Reichardt, MSc, PhD, Dr. Yukimitsu Miyakawa, DDS, PhD, Dr. Wolfgang Wünsche, Stuttgart  
MDT Christoph Keltsch, Weinstadt

The stomatognathic system plays a key factor in the health and emotional expression of humans. It determines the facial profile and affects articulation, breathing and body posture. Subconsciously it also affects the processing of emotional processes. This is expressed by individual levels of bruxism. Sometimes the teeth are positioned so poorly, that they even affect chewing and speaking. In the long term this malposition can also lead to consequential damage to the teeth or the jaw joint [1,2]. Muscular compensation often causes tension with resulting head, neck or shoulder pains, sometimes even afflicting skeletal posture. These effects can be remedied by targeted orthodontic intervention. The following article describes how the malposition of teeth is regulated with the aid of final CAMLOG® SCREW-LINE implants according to esthetic and functional aspects.

The reasons for later secondary tooth malposition are often due to deficiencies not remedied during younger age or a shift in teeth due to periodontal disease, or lost teeth per se. The subconscious permanently attempts to alleviate the functional deficits of the missing or changed structures through muscular compensation. These chronic compensation attempts induce hyperactivity in the neuro-muscular system and, as a consequence, destructive parafunctions.

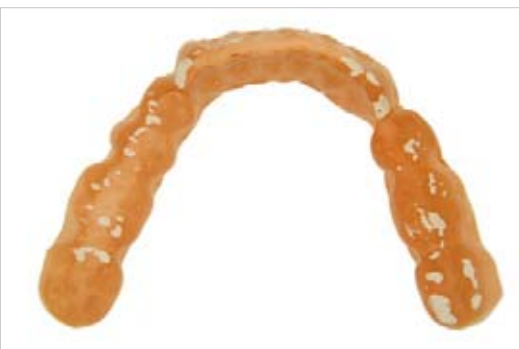Our holistic treatment approach embraces consistent tooth/jaw malposition treatment prior to prosthetic restoration. This also includes straightening and functionally correct positioning of individual teeth and tooth groups. Implants are well suited

as counter supports for the movement of teeth. Studies have confirmed that mini implants have been used successfully for several years now in orthodontic treatment [3,4]. However, due to the individual bone structures involved, our clinical experience has shown a high failure/loss rate. These mini implants are placed in the palate or distal to the rear molars and need to be removed once treatment is completed. Often they cannot be placed in the physiological tooth arch and can therefore not be loaded with a regular, direct load transmission system. The achieved position of the tooth is therefore often unsatisfactory. In our treatment approach we avoid these additional surgical interventions wherever possible and regulate the teeth with final,

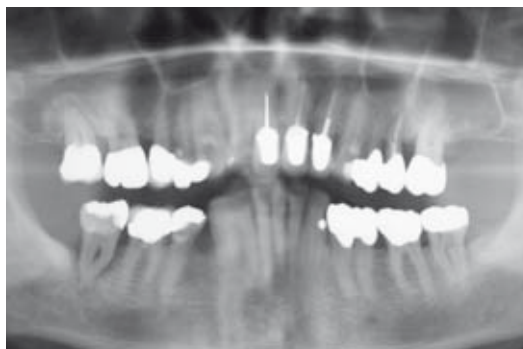
osseointegrated implants. These firmly anchored implants provide excellent counter supports for the regulation of teeth in all three dimensions. They are inserted at the optimal position for later final restoration and fitted with a temporary hybrid abutment crown for a healing phase of approximately twelve weeks. A bracket is attached to the implant crown and, applying a special bending technique for the orthodontic wire or rubber bands, the teeth are shifted into the optimal position in accordance with functional criteria.

### Initial findings and diagnosis of the first case study

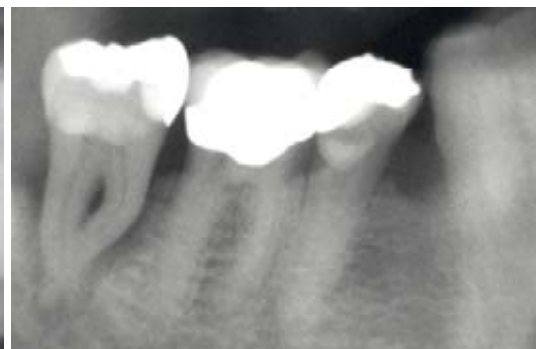A 55-year old patient presented in our practice in 2008 with a prosthetic



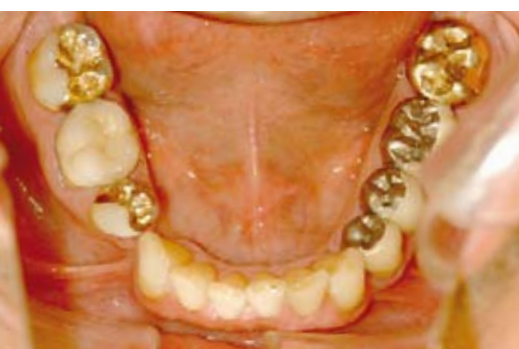**Fig. 3:** leading to interference in dynamic occlusion.



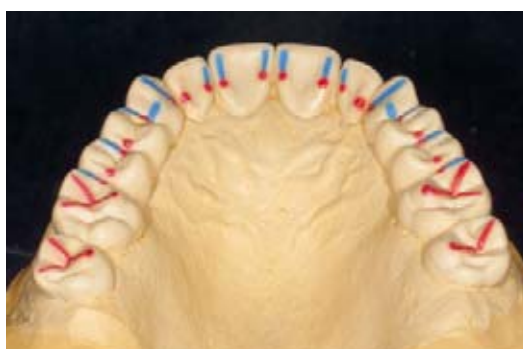**Fig. 4:** The X-ray image for diagnosis shows insufficient root fillings and protruding crown margins as well as pronounced periodontitis marginalis in the molar region.



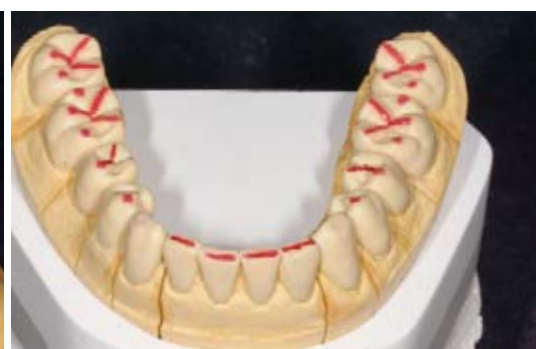**Fig. 5:** Teeth 45 and 46 are canted to mesial. Tooth 47 is not worth saving and needs to be extracted.



**Fig. 6:** The earlier extraction of tooth 44 without orthodontic treatment is the reason for the massive bone degeneration in the region.



**Fig. 7:** Wax-up prepared according to functional and esthetic criteria as planning basis for overall restoration.



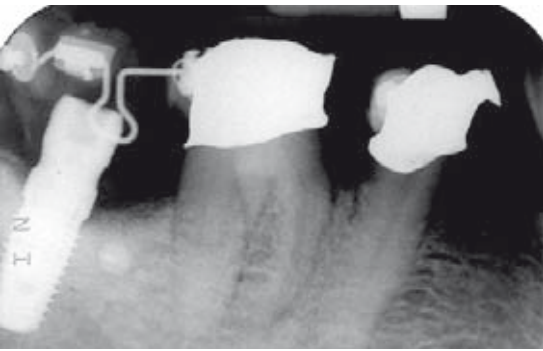
restoration going back over 20 years. The patient felt he could no longer bite properly and that the molars were overloaded, which was confirmed in the subsequent diagnosis (**Fig. 1**). The shifted center line, deep bite situation and uneven occlusal levels were immediately apparent. In addition to the results from instrumental functional analysis, we gained further valuable information on the individual function modes by using BruxChecker® foils (Scheu Dental) [5]. The 0.1 mm thin foil is drawn over the maxilla and mandible model and cannot be felt by patients during wear. The patient wears the BruxChecker® separately for two nights each in the maxilla and the mandible. The bruxism pattern on the foils allows feedback on possible pathological phenomena which need to be addressed through suitable types of therapy. Next to bruxism as part of stress management, the reasons for nocturnal grinding of teeth may also be due to tooth malposition, vertical degeneration, too steep anterior-to-cuspid guidance as well as functionally inadequate occlusion levels. The effects of this uncontrolled induction of forces to the anatomical structures may cause caries of the tooth

neck, abrasions, chipping, periodontal disease and, as a consequence, tooth loss. The pronounced visible abrasion on the BruxCheckers® of our patient after only one night of wear illustrates clear overload on tooth 47 (**Figs. 2 and 3**). Besides showing the periodontal collapse of tooth 47, the X-rays also revealed insufficient root fillings, protruding crown margins and pronounced general periodontitis marginalis in the molar region (**Fig. 4**). Teeth 45, 46 and 47 are canted to mesial (**Fig. 5**). The reason is the extraction of tooth 44 at young age without orthodontic post-treatment which led to massive bone degeneration. Due to the missing structures, a pathological tooth structure developed over time. (**Fig. 6**)

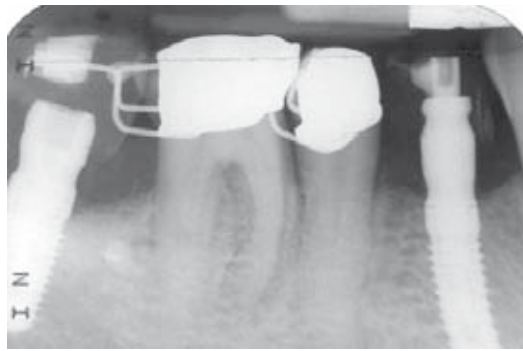
### Pre-prosthetic treatment

When planning treatment, the esthetic demands of the patient and the longevity of prosthetic restoration are prime factors. We accomplish this not only by selecting suitable materials, but mainly by providing harmonious function of the static and dynamic occlusion. During pre-prosthetic treatment the patient underwent an intensive hygiene program,

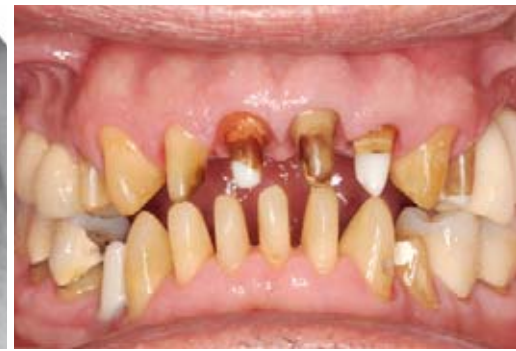including root planning, deep scaling and periodontal surgery to all posterior teeth. Using a myocentric splint in the mandible, a so-called flat guidance splint, the therapeutic position of the mandible was recorded diagnostically. In this splint therapy the mandible occupies its individual and most relaxed muscular spatial position, completely free of manipulation by the dentist [6]. A wax-up was prepared by the dental technician for discussing the esthetic preferences of the patient and for planning the reconstruction of a functional, interference-free occlusion (**Fig. 7**). The bite lift necessary was determined via the index of the teleradiographic analysis. Durable temporary dentures were fabricated for this therapeutic position. In the meantime our practice surgeon extracted teeth 17, 25, 26, 47 which were regarded as not being worth saving and the endodontist corrected the insufficient root fillings. Following the healing phase, the CAMLOG® SCREW-LINE implants were placed in the maxilla using a sinus lift on both sides. He also inserted the implant in regio 47 (diameter 5.0 mm/length 11 mm) in the optimal position for later



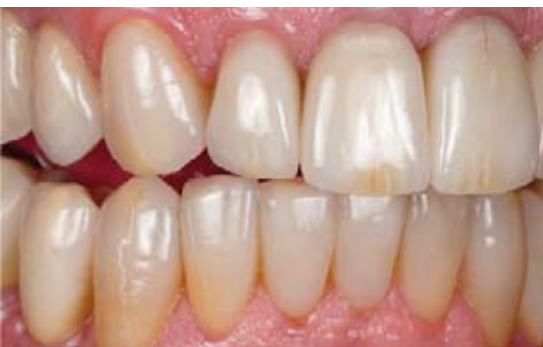**Fig. 8:** Tooth 46 is uprighted distally with the aid of the implant in regio 47 and the gap to the hybrid abutment crown is closed.



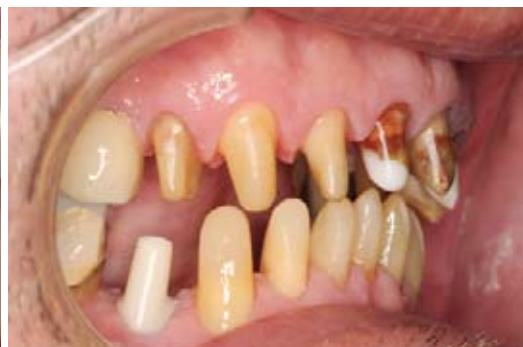**Fig. 9:** After the premolar 45 has been uprighted over implant 47, implant 44 is inserted following bone augmentation.



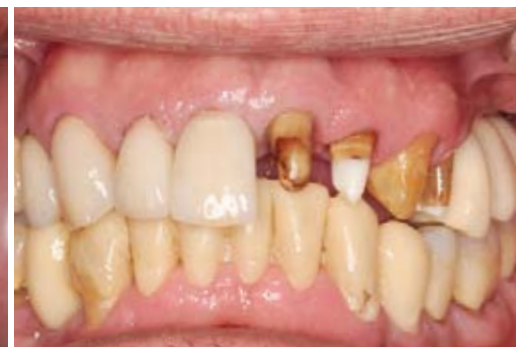**Fig. 10:** The therapeutic bite position is retained by first preparing the anterior teeth including the premolars and then providing final restoration.



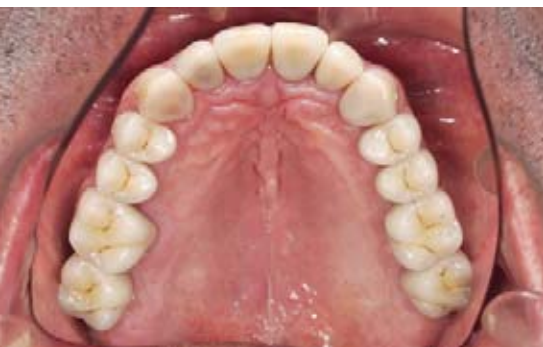**Fig. 11:** The esthetic anterior crowns are fabricated fully ceramic in press and layer technique.



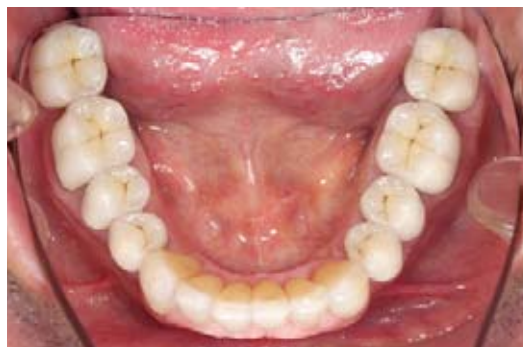**Fig. 12:** A pressed hybrid abutment, bonded to the CAMLOG® titanium base CAD/CAM, acts as sub-construction for the full ceramic crown 44.



**Fig. 13:** The full ceramic crowns are inserted individually with a bond. Then the cuspids are prepared and prosthetically restored together with the implants.



**Figs. 14 and 15:** The harmoniously positioned fully veneered metal ceramic crowns in the dental arch are veneered fully anatomically and inserted.



**Fig. 16:** A functionally stable Class II dentition has been achieved on the right, and Class I on the left. The alignment of the teeth and their axial loading can be seen clearly.

final prosthetic restoration according to functional criteria.

### Orthodontic treatment

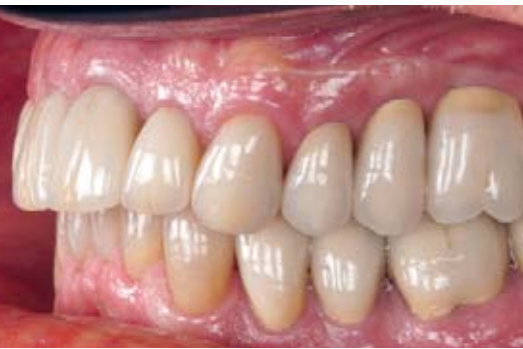In order to return the mesial canted teeth 45 and 46 to functionality and axial loading, they needed to be uprighted orthodontically. To this end we used the implant in regio 47 as counter support. After the healing phase it was restored using a temporary hybrid abutment crown in full Class II dentition. Brackets were attached to the anatomically correct design of the hybrid

abutment crown and on tooth 46 and connected with a wire spring. The molar was uprighted with the special bending technique of the orthodontic wire which closed the gap to the implant crown (**Fig. 8**). Regulation of tooth 46 was complete after approximately three months. Then the premolar which was canted at approximately 28° degrees was uprighted in the same manner. After a further three months, sufficient space was available in regio 44 for reconstruction of the first premolar. The defect of the jaw bone was augmented laterally with bone chips

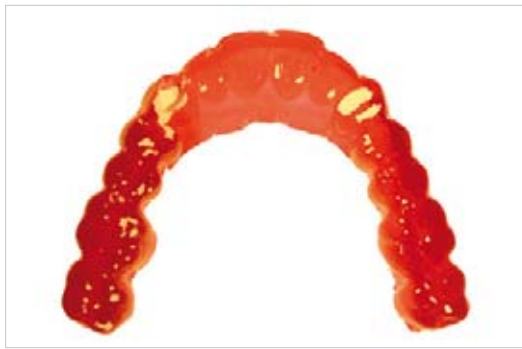from the retromolar region and bone replacement material and a 3.8 mm diameter and 13 mm long CAMLOG® SCREW-LINE implant was inserted (**Fig. 9**). During the healing phase of the implant we optimized the vertical dimension and the static and dynamic occlusion, maintaining the therapeutic position with Table Tops.

### The final restoration

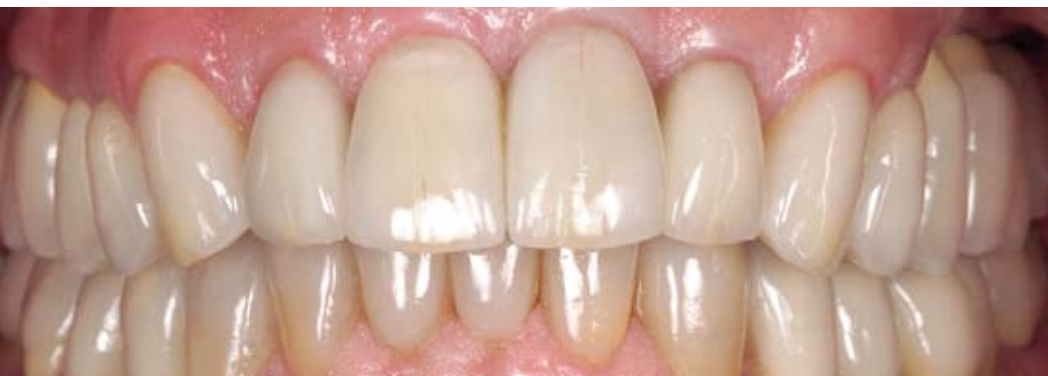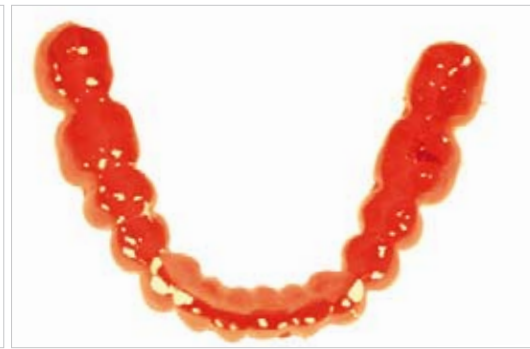After 18 months the pre-prosthetic treatments had been concluded and the patient felt very comfortable with the



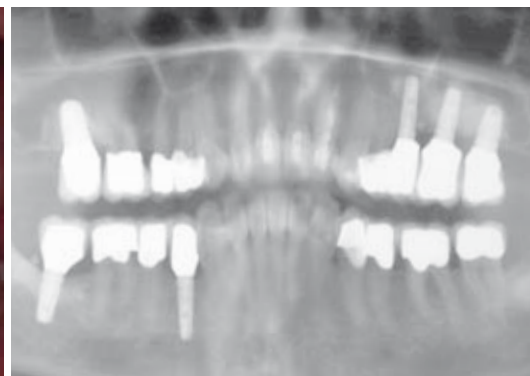**Fig. 17:** This dentition affords the prosthetic restoration with a long-lasting prognosis.



**Figs. 18 and 19:** The color abrasion on the BruxChecker® foil shows control via the cuspids and interference-free dynamic occlusion.



**Fig. 20:** An esthetic and well functioning outcome, also due to setting of the therapeutic position and the new vertical.



**Fig. 21:** Three years after insertion of the prosthetic restoration the X-ray follow-up shows a stable periodontal condition.

mandibular bite position. To maintain this, we started with the preparation and restoration of the maxillary and mandibular anterior teeth including the first premolars (**Fig. 10**). After hydrocolloid impressions and bite registry an immediate temporary denture was prepared chairside on the basis of a diagnostic wax-up. The working models were fabricated and articulated in the dental laboratory. The diagnostic wax-up was transferred precisely into the final restoration. The anterior crowns were fabricated from lithium-disilicate glass ceramics IPS e.max® applying a press and layer process and inserted with a bond (**Fig. 11**). This ceramic material fulfilled the patients demands and provides longevity in functional use. The implant in regio 44 was restored with an IPS e.max® press hybrid abutment on a CAMLOG® titanium base CAD/CAM and a pressed full-contour crown (**Fig. 12**). After placement of the crowns (**Fig. 13**), thus keeping the bite position intact, the posterior teeth were prepared. Impressions were taken of the four quadrants including the implants. Following these preparatory measures the customized

titanium abutments were screwed to the implants. The metal ceramic crowns were modelled, cast and fully veneered in the laboratory and then finally inserted in a conventional manner (**Figs. 14 and 15**). The chewing surfaces were designed according to the sequential occlusion principle of the Vienna School such, that the teeth and implants were evenly loaded axially during static bite (**Figs. 16 and 17**). Interference-free articulation was checked with the aid of the BruxChecker® foils and corrected if necessary. Abrasion of the color demonstrated the desired functional parameters during dynamics, in particular the reliable check of the cuspids (**Figs. 18 and 19**). The alignment of the therapeutic position, stable posterior support and axial loading of the teeth all lead to good long-term prognosis for the prosthetic restoration. Adaptation of the occlusion levels (**Fig. 20**) to the individual, skeletal growth type of the patient and the created intra-coronal space greatly facilitate functional loading of the stomatognathic system and not only simply relieve the previously heavily loaded jaw joints. Even after three years, the X-ray shows a



**Fig. 22:** A fully relaxed and happy patient.

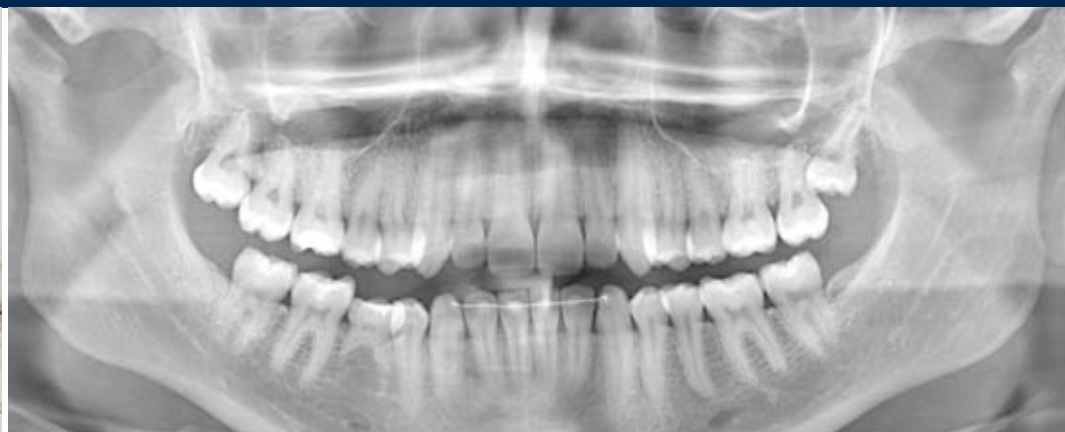stable periodontal condition (**Fig. 21**). A relaxed and happy patient leaves our practice (**Fig. 22**).

### Initial situation of the second case study

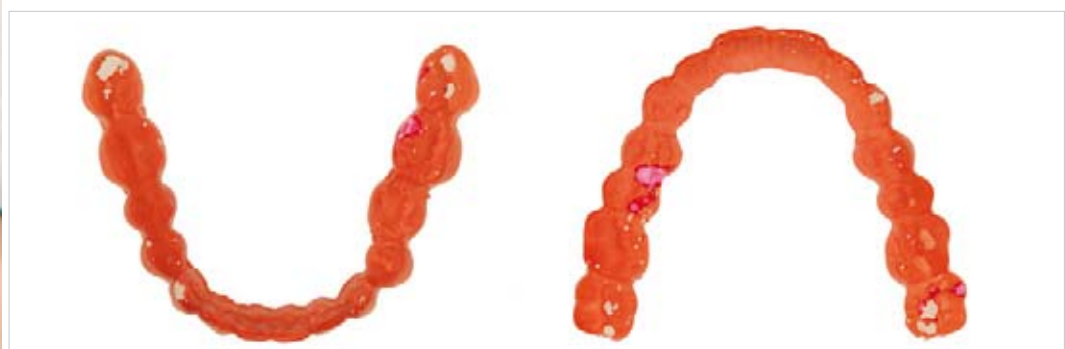A 25-year old female patient presented in our practice in 2009 with severe problems of the jaw joints. Her visible hypertrophic masseter muscles were indicative of her pronounced muscular hyperactivity (**Fig.**



**Fig. 23:** Pronounced problems with jaw joints, visible through pronounced masseter muscle, and open bite led patient to present in practice.



**Fig. 24:** Among other things, the X-ray findings reveal arthrotically modified jaw joints and a persisting milk tooth in the fourth quadrant.



**Fig. 25:** The BruxChecker® foil reveals massive interference on all four terminal molars.

**23).** Despite years of orthodontic treatment she still had an open bite and the jaw joints occasionally blocked so badly that she was unable to open her mouth. Due to her anxiety she wore a bite splint permanently. The X-ray revealed an impacted and shifted wisdom tooth in the second quadrant and a persisting milk tooth 85 (**Fig. 24**). The result of the Brux-Checker® test confirmed the evaluation of the instrumental function analysis and illustrated the malfunction on the posterior molars (**Fig. 25**). The massive loading of the jaw joints had resulted in pronounced capsular contracture and anterior disc displacement on the right with terminal reposition. Diagnosis revealed a Class II ½ PB dentition on the right, and on the left, a Class II ¼ PB with impairment of the static and dynamic occlusion.

### Treatment planning

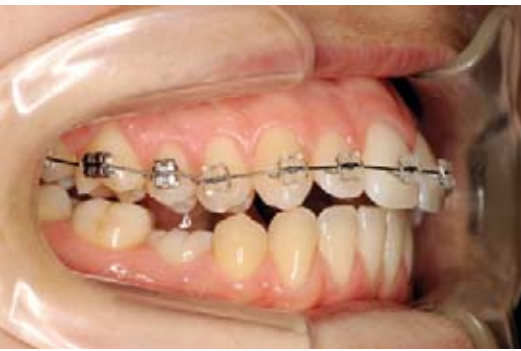After intensive functional diagnostic measures and significant improvement of her symptoms through permanent wearing of the diagnostic splint, the patient could be convinced to agree to

further time-intensive orthodontic therapy followed by minimally invasive measures [5]. A possible alternative would have been a classical massive, orthodontic surgical intervention to adjust the mandible, although this would not necessarily have guaranteed individual function optimization. In the case of this patient we did not feel we could justify this major surgical measure as her fundamental problem is a joint compression which cannot be controlled by surgery.

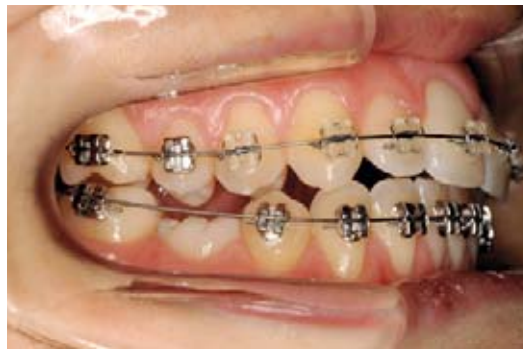### Pre-prosthetic treatment

After extracting the wisdom tooth in the maxilla we were able to commence with orthodontic treatment. First the teeth in the maxilla were bracketed and the archwire shaped correctly into a parabola in terms of function and anatomy (**Fig. 26**). This in itself led to slight mandibular adaptation to vertical/caudal, which as a logical consequence relieved the joints and led to a reduction in symptoms. Then the teeth in the mandible were bracketed and the dental arch regulated in semi-elliptical form. This allowed the

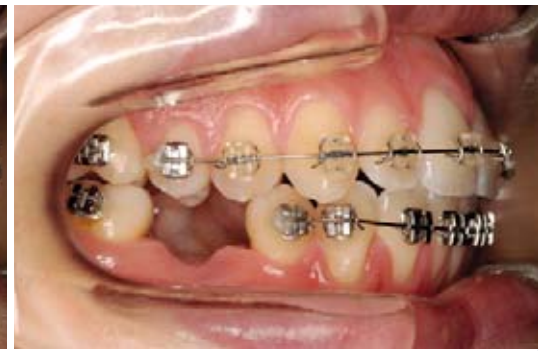mandible the freedom necessary to slide into the functionally correct position (**Fig. 27**). Ten months later dentition had been improved significantly. Now the persisting milk tooth 85 in the fourth quadrant was extracted (**Fig. 28**) and a CAMLOG® SCREW-LINE implant (length 11 mm and 3.8 mm diameter) inserted in regio 45 in the prosthetically correct position for a Class I dentition (**Fig. 29**). Healing was submerged. The molars were still positioned in a statically unstable ½ Class II versus each other (**Fig. 30**). After three months the implant had osseointegrated. It was opened, an impression taken, and a temporary hybrid abutment crown was fabricated and inserted. A CAMLOG® Esthomic® Abutment Inset was used for temporary restoration (**Fig. 31**). The titanium abutment was customized, with undercuts milled and silanized in the veneer surface. The abutment was opaqued and an anatomic premolar fabricated from resin with an esthetic crown emergence profile corresponding to the natural size. The hybrid abutment crown was screwed directly into the implant and the screw access channel sealed



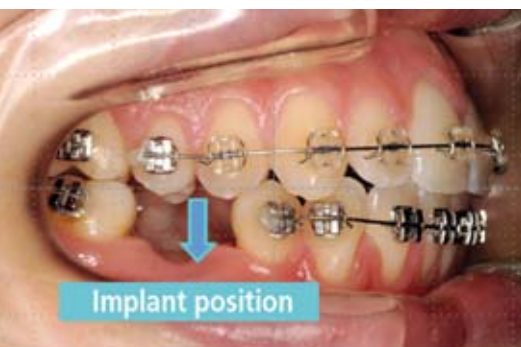**Fig. 26:** The maxillary dental arch is formed orthodontically.



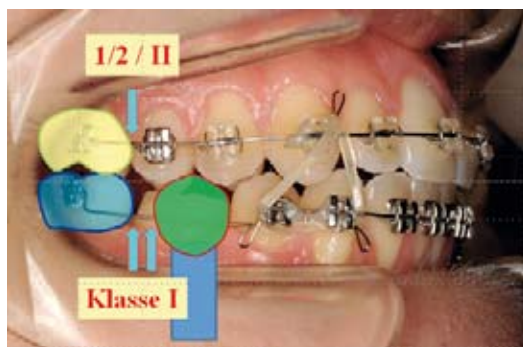**Fig. 27:** After four weeks the teeth in the mandible are bracketed and the mandible placed in the therapeutically correct position.



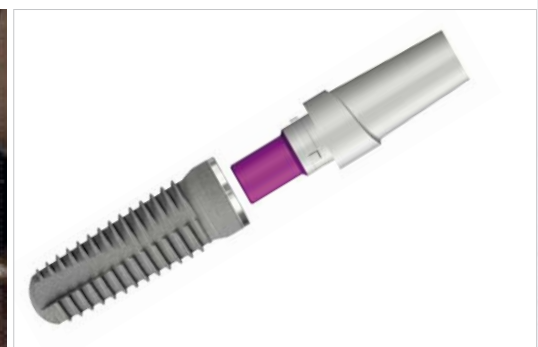**Fig. 28:** Ten months later dentition had been improved significantly. Milk tooth 85 was extracted.



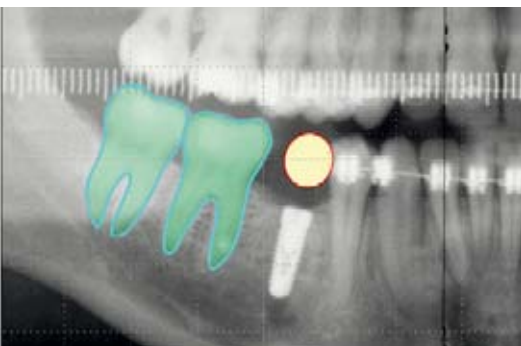
**Fig. 29:** To obtain a future Class I dentition, the CAMLOG® SCREW-LINE implant is inserted in the prosthetically correct position.



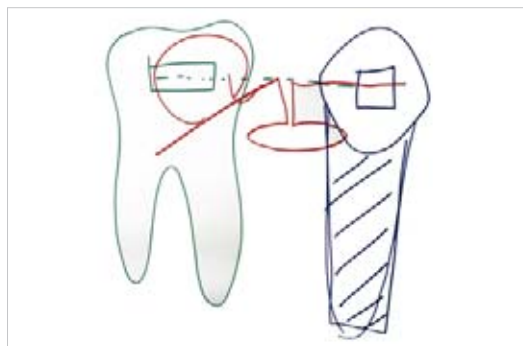
**Fig. 30:** The molars are positioned in 1/2 Class II versus each other. To achieve the objective of optimal functioning occlusion, they need to be physically regulated to mesial.



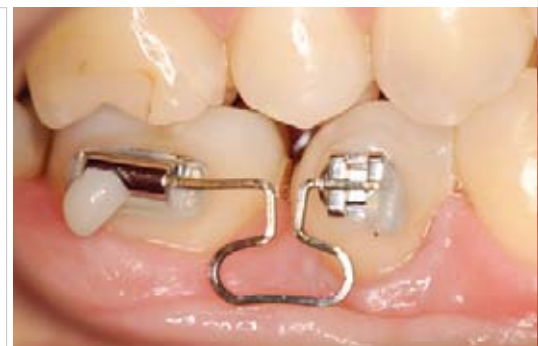**Fig. 31:** The CAMLOG® Esthomic® Abutment Inset was used to fabricate the temporary hybrid abutment crown.



**Fig. 32:** Placement of the implant according to functional and esthetic criteria.



**Fig. 33:** Graphic illustration of the bracket bending technique to regulate a tooth in the supporting structure with the aid of an implant.



**Fig. 34:** Tooth 46 is physically shifted to mesial. Two months later the gap is closed and tooth 47 is readjusted in the same manner.

with composite. To obtain a stable and balanced occlusion, the gap between tooth 45 and 46 now had to be closed. A stable implant-abutment connection is essential for the regulation of teeth with the aid of an implant.

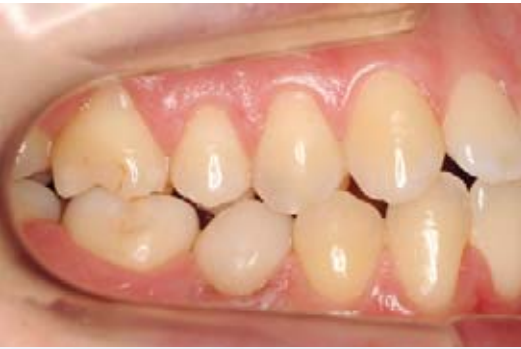**Figure 32** shows the gap, approximately 1/4 premolar width, between 45 and 46. After checking occlusion, the implant crown and tooth 46 were fitted with brackets and connected via a specially bent orthodontic wire (**Fig. 33**). The spring tension of the wire regulated tooth

46 physically in mesial direction (**Fig. 34**). After three months the gap had closed and tooth 47 was positioned in the same manner.

### Prosthetic restoration

Orthodontic treatment was completed successfully after 27 months. We had achieved stable posterior support and set the vertical new (**Fig. 35**). The patient felt very comfortable with the therapeutic position of her mandible

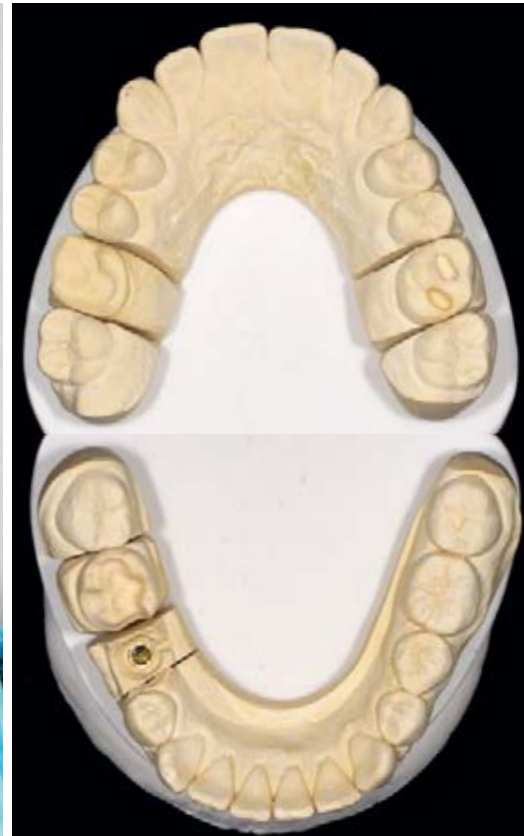and was completely pain-free. The strong pronunciation of her masseter muscles was visibly reduced which was due to a significant reduction of compensatory muscular activity (**Fig. 36**). At the end of treatment the extensively conservatively restored teeth 16 and 46 were prepared minimal invasively (**Fig. 37**) and an impression taken together with the implant. The implant was restored with a CAMLOG® ceramic abutment on the CAMLOG® titanium base and restored with an IPS e.max® press



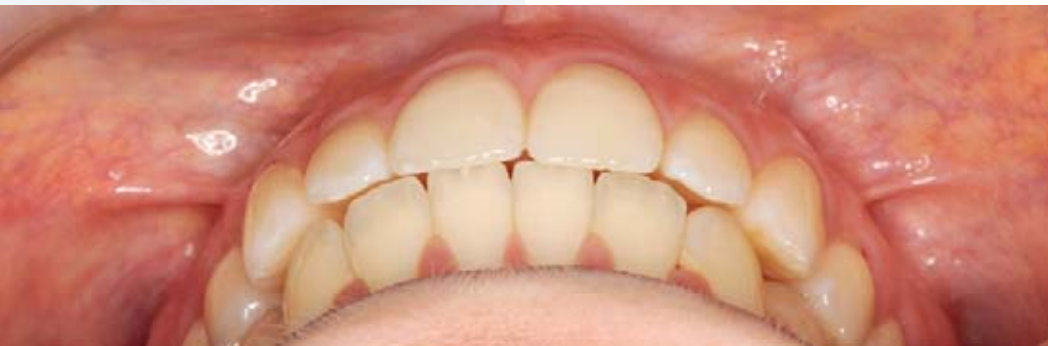**Fig. 35:** The treatment outcome after 27 months demonstrates a stable Class I dentition.



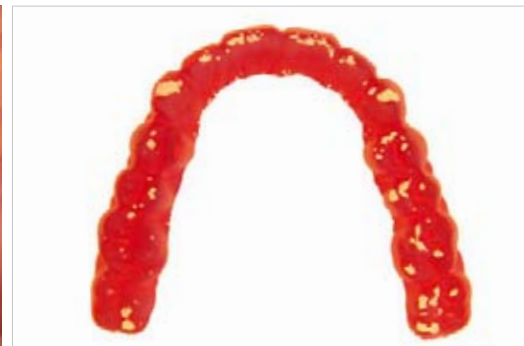**Fig. 36:** ...the interim result and a delighted, complaint-free patient.



**Fig. 37:** The master models with the prepared stumps of the minimally invasive prepared molars 16 and 46 and impression of the implant.



**Fig. 38:** The treatment objective has been achieved: the bite is closed, the anterior teeth and cuspids can meet their tasks as intended by nature.



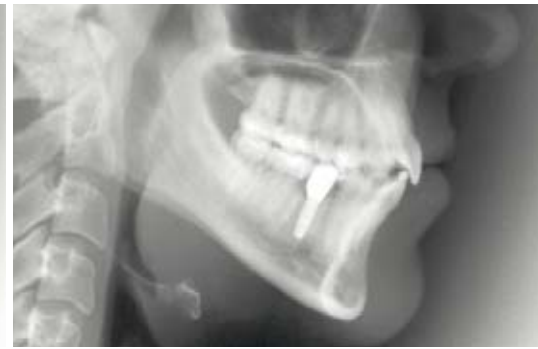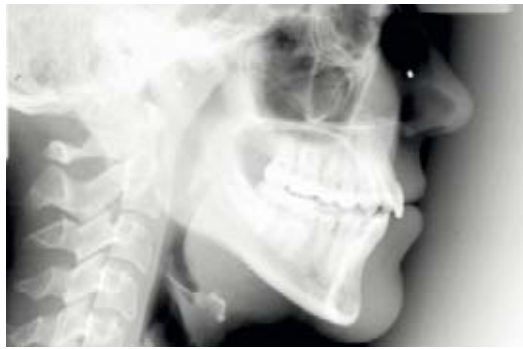**Fig. 39:** The BruxChecker analysis shows functional cuspid guidance.

crown. The prepared teeth were restored with pressed full ceramic partial crowns and the other molars and premolars conservatively with composite. **Figure 38** demonstrates a convincing treatment outcome: the bite is closed and occlusion is harmonious and functional. In this case, too, the functional therapeutic goal was checked with BruxChecker® foil (**Figs. 39 and 40**). Color abrasion demonstrated stable static support and completely interference-free dynamics of the mandible, enabled by individual

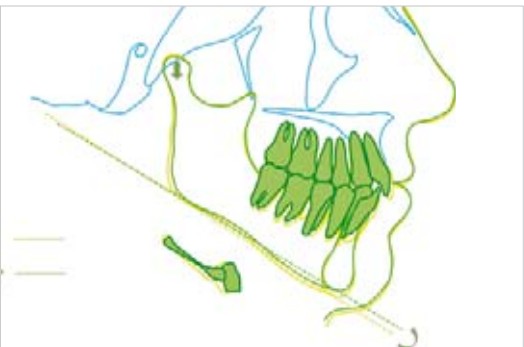
cuspid guidance. The success of treatment and the significantly changed position of the mandible are well illustrated by teleradiography (**Figs. 41 and 42**). Superimposition illustrates the degree of mandibular adaptation (**Fig. 43**). One year after completion of treatment the X-ray follow-up is without findings (**Fig. 44**). Clinically the overall situation remains unchanged and stable (**Figs. 45 and 46**).



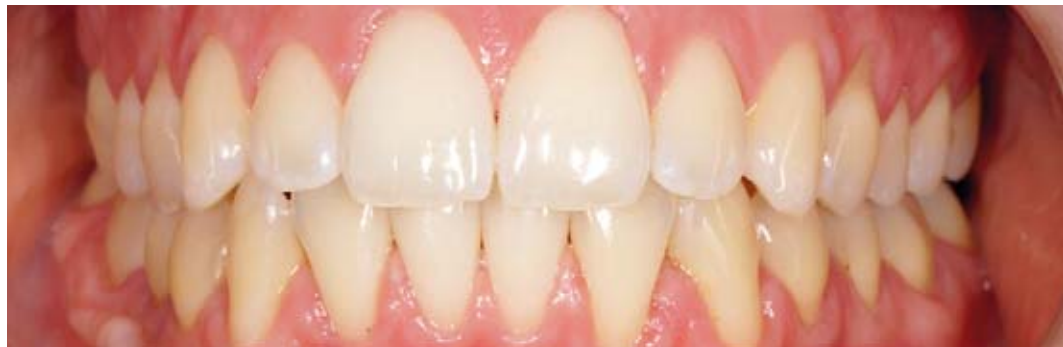**Fig. 40:** No functional barriers can be detected in the dynamic occlusion.



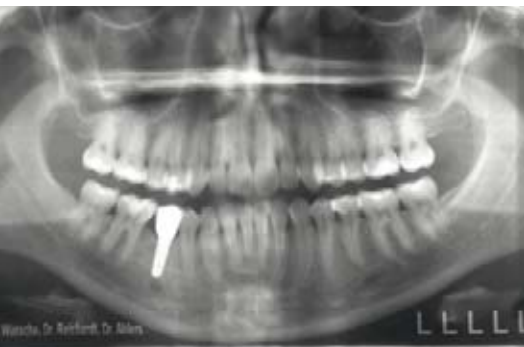**Figs. 41 and 42:** teleradiographic images show the clearly changed position of the mandible and the closed bite following treatment.



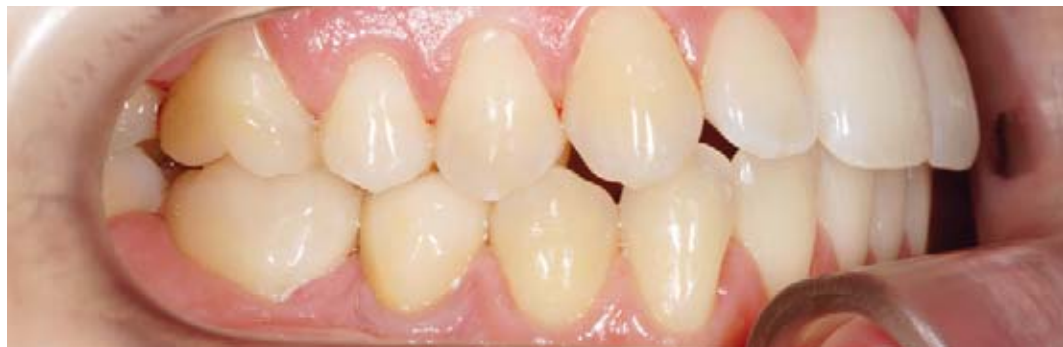**Fig. 43:** Superimposition of the X-ray impressively illustrates the skeletal changes.



**Fig. 45:** The situation is unchanged and stable and the patient is happy and does not suffer from complaints.



**Fig. 44:** Follow-up one year after completion of treatment shows a very stable treatment result.



**Fig. 46:** The situation is unchanged and stable and the patient is happy and does not suffer from complaints.

## DISCUSSION

Extreme false loading of teeth may interfere with blood circulation in the alveolar bone and lead to bone degeneration, thus causing tooth loss. Axial loading and thus optimized force induction into the bone are important factors for the longevity and stability of rehabilitation. Teeth and prosthetic restorations have a considerably better prognosis if the functional aspects are taken into consideration. For teeth to be loaded physiologically, functional disturbances must be alleviated by orthodontic measures in many cases. The objective of our treatment concept is the consistent management of the individual

therapeutic position of the mandible. In order to install a stable static posterior support, the occlusal management needs to be clearly defined in advance of treatment. Often gaps need to be closed or widened. Final implants with a stable implant/abutment connection are well suited for this purpose. With the aid of implants anchored in the bone, teeth are shifted in horizontal direction at approximately 200 g traction to their prosthetically optimal position. This procedure is still being discussed with great controversy. We have been treating our patients with functional disturbances of the

stomatognathic system and the resulting, often considerable, CMD diseases with this method for over five years. The success rates have encouraged us to continue pursuing this concept. In our practice, good cooperation between the respective treatment teams is a prerequisite for the long-term success of therapy to improve the general well-being of our patients and to their benefit.



## LITERATURE

- [1]. Gesch, D; Bernhardt, O.; Mack, F.; John, U.; Kocher, T.; Alte, D.: Association of malocclusion and functional occlusion with subjective symptoms of TMD in adults: results of the Study of Health in Pomerania (SHIP). *Angle Orthod* 2005; 75, 183-190.
- [2]. Sato S, Slavicek R. The masticatory organ and stress management. *Int J Stomatol Occl Med*. 2008;1:51-7.
- [3]. Glasl, Kinzinger, Lisson, Ludwig: Aufrichtung gekippter unterer Molaren mit Hilfe kortikaler Verankerungstechniken Quintessenz Kieferorthopädie 3/2010, S. 47 – 54.
- [4]. Farret MM, Benitez Farret MM.: Skeletal class III malocclusion treated using a non-surgical approach supplemented with mini-implants: a case report. *J Orthod*. 2013 Sep;40(3):256-63.
- [5]. Onodera K, Kawagoe T, Sasaguri K, Protacio-Quismundo C, Sato S. The use of a Brux Checker in the evaluation of different grinding patterns during sleep bruxism. *Cranio*. 2006;24:292-9.
- [6]. Reichardt G, Miyakawa Y, Otsuka T, Sato S. The mandibular response to occlusal relief using a flat guidance splint. *J. Stomat. Occ. Med.* DOI 10.1007/s12548-013-0093-8.

## AUTHORS

**Dr. Gerd Reichardt, MSc, PhD**

is a self-employed dentist in joint practice with Dr. Wolfgang Wünsche in Stuttgart. He is a scientific assistant and PhD graduate of Kanagawa Dental University/Japan in the Department of Craniofacial Growth and Development Dentistry under Prof. Sadao Sato, and winner of the international AIG Award for the best scientific work 2008. Dr. Reichardt is a member of the DGZMK, DGFDT, DGÄZ, GAK Stuttgart, Tufts Orofacial Pain Society and the study group "Vienna School" under Prof. Rudolph Slavicek and the ITI study group Stuttgart. Since 2008 he has been active as speaker and course leader at a national and international level.

**Dr. Wolfgang Wünsche**

has his own dental practice since 1981 and founded the joint practice in the Landhausstraße 74 in Stuttgart. His areas of expertise are implant dentistry and implant prosthetics. He is an examined and certified specialist of the European Dental Association for Implant Dentistry and member of the DGZMK, DGP, DGI; BDIZ and DGÄZ as well as the EAO and EDI. Dr. Wünsche has been on the Focus physician list as specialist for implant dentistry for many years and is course lecturer for various periodontal and implantological practice courses.

**Yukimitsu Miyakawa, D.D.S., PhD**

completed his basic studies in dentistry at the Health Sciences University of Hokkaido and his PhD in the Department of Orthodontics, at Kanagawa Dental University in Japan. Four years he worked there as orthodontist and lecturer and as a scientist. As right hand of Prof. Sadao Sato he spent many years as a teacher for functional occlusion and orthodontics in clinical courses at the Danube University Krems in Austria and the Egas Moniz University in Portugal. In this role he continued via the Rudolfinerhaus in Vienna with Prof. Slavicek to the interdisciplinary academy for dental education IDEA, Foster City, California, USA. Since 2009 he is employed in the dental practice "Ihre Zahnärzte Landhausstrasse 74" as functional orthodontist.

**Contact information****"Ihre Zahnärzte"**

Landhausstraße 74  
70190 Stuttgart

Tel.: +49 (0)711 285 21-0

Fax: +49 (0)711 285 21-9

E-mail: praxis@landhausstrasse.com

**MDT Christoph Keltsch**

took his master certificate in 1987 in Stuttgart. After a few years as dental technician in New Zealand he established his dental laboratory in Aichtal and moved to Weinstadt seven years later. He completed a course on "Function and dysfunction of the masticatory organ" at the Danube University Krems with Prof. Dr. Slavicek. He is a member of the working group for esthetic-functional dentistry and has attended numerous further education courses at home and abroad.

**Contact information****Dentallabor Christoph Keltsch**

Strümpfelbacherstr. 4  
71384 Weinstadt

Tel.: +49 (0)7151 906790

E-mail: dlkeltscht@t-online.de

## THE ISY Implant System – EXPERIENCE IN PRACTICE

Since the International Dental Show 2013, CAMLOG has offered iSy, a novel Implant System for greater efficiency in implant dentistry. It is a concept which opens new perspectives for the rehabilitation of partially and fully edentulous patients through a high level of standardization and lean processes. Since its market introduction in March 2013, several hundred users have already decided in favor of iSy. Four iSy users from day one in three dental practices were interviewed by the logo editors on their experience with the iSy concept.

The same questions were given to the experts separately. The various statements were grouped by topic to give a clearer overview and better readability.



*"With iSy, we have a system conceived for open healing, which is one of the reasons we like to use it."*

Dr. Jan Klenke, Hamburg, Germany



*"We have defined a therapy standard for each iSy indication, which lies clearly below the usual price levels. This broadens our base for implant dentistry."*

Dr. Thomas Barth, Leipzig, Germany



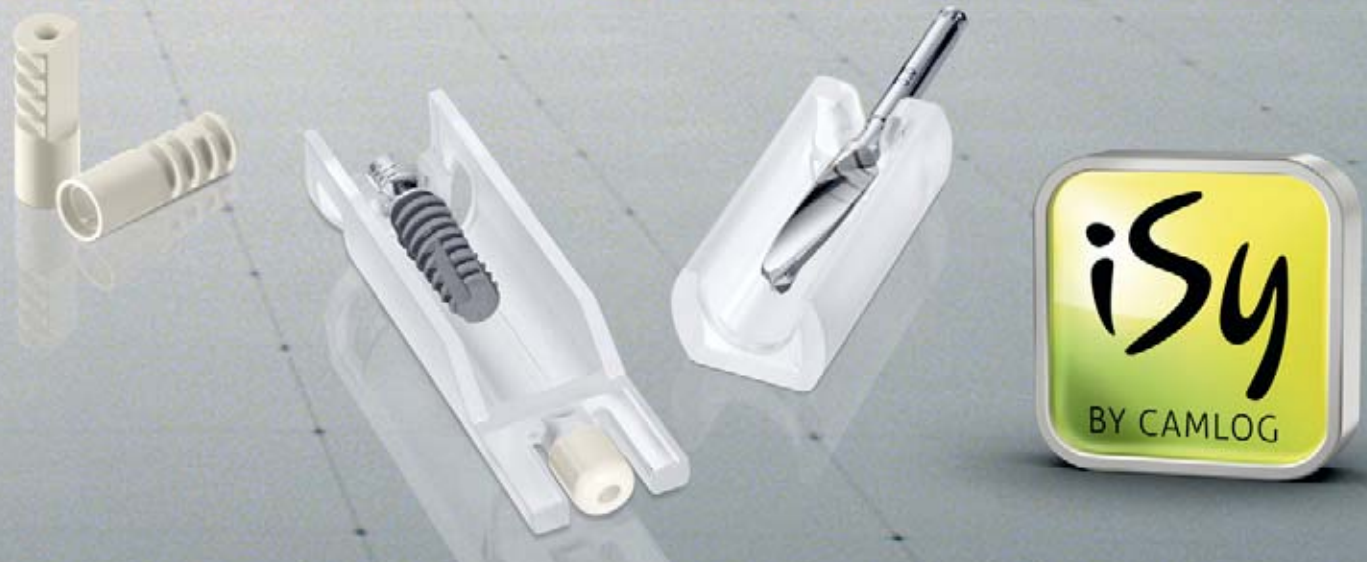*"This concept has proven to be particularly attractive for younger patients."*

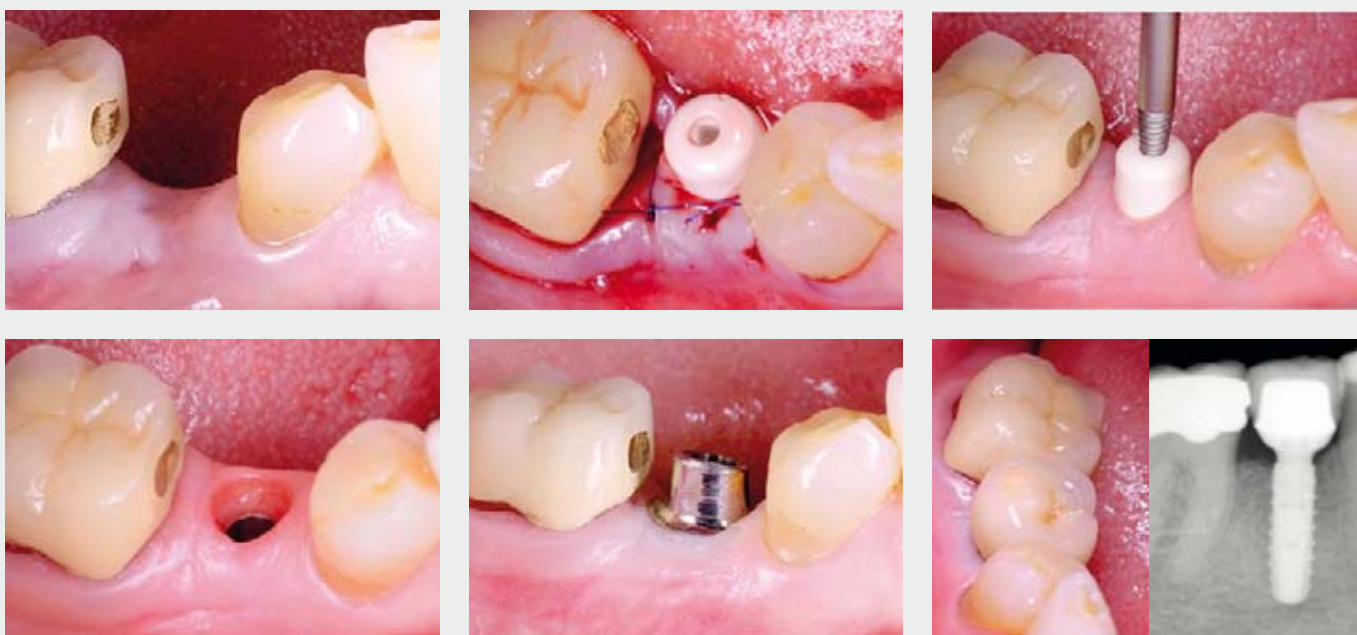
Dentist Stefan Ulrici, Leipzig, Germany



*"In surgery, we save around 30 per cent of our time by using iSy when compared with other systems."*

Dr. Manfred Wolf, Leinfelden-Echterdingen, Germany





Single-tooth reconstruction in the posterior region with the iSy Implant System: a standardized procedure with open healing for a functional restoration (Photos: Dr. Jan Klenke).

**iSy claims to be especially transparent, time-efficient, of high quality and at a favorable price. What attracted you most?**

**Dr. Thomas Barth:** The crucial argument for us as clinicians was time-efficiency in combination with quality made in Germany.

**Dr. Manfred Wolf:** When we talk about iSy, I would like to first say that we are talking about a certain spectrum of indications, one where I would like to exclude highly demanding esthetic cases as factors such as time or money are only of secondary importance here. For those cases where iSy is appropriate, time-efficiency is the key. Quality is a prerequisite and a favorable price is always a good argument.

**Dr. Jan Klenke:** For those cases where we can use iSy, time-efficiency is certainly the most important aspect. Add to which, the product is made by CAMLOG, is of high quality and of favorable cost. The overall concept is a solid one.

**Which main benefits can you see for your patients?**

**Stefan Ulrici:** With iSy, we can offer more patients solid implant restoration at a favorable price.

**Dr. Jan Klenke:** For patients, iSy means one operation less, that also means fewer visits and lower financial burden.

**Dr. Manfred Wolf:** Basically, the lean concept with all its advantages, for example time-saving treatment and the caring procedure which does not require reopening.

**How important for your decision was the fact that iSy is by CAMLOG?**

**Dr. Jan Klenke:** The source of the system is absolutely important. We work together closely with CAMLOG since the year 2000.

**Dr. Thomas Barth:** That was absolutely decisive for us. We go for solid and long-term partnerships as a matter of principle.

**Dr. Manfred Wolf:** CAMLOG offers a quality standard which is a known quantity. This provides a basis of trust which the user automatically conveys to new products. This leads to high acceptance right from the start.

**In which cases do you use iSy?**

**Dr. Manfred Wolf:** We use iSy for standard indications – edentulous gaps, free-end situations and edentulous jaws. Use in the anterior region is an exception. Augmentation is not an automatic

exclusion criterion for iSy, but depending on the degree of augmentation it may prove more prudent to refer to the CAMLOG or CONELOG Implant System.

**Dr. Jan Klenke:** In our experience, iSy can be used in less demanding surgical cases with a good bone offer, which permit transgingival healing and where patients do not have exceptional demands on esthetics. Smaller levels of augmentation are possible.

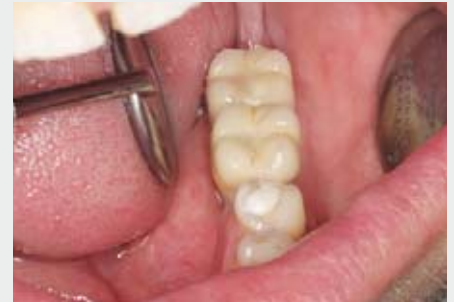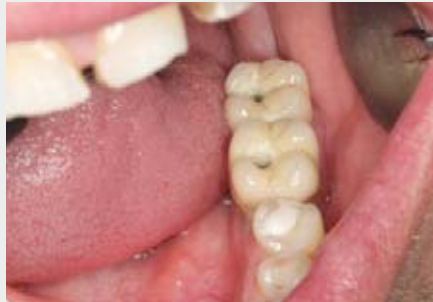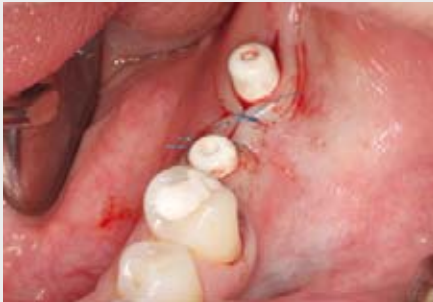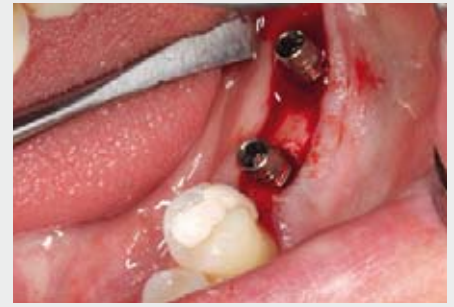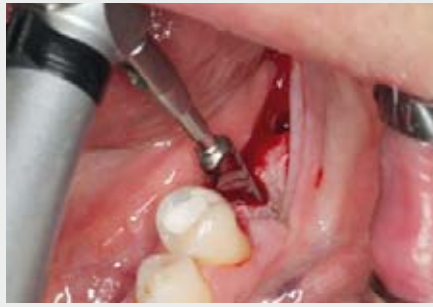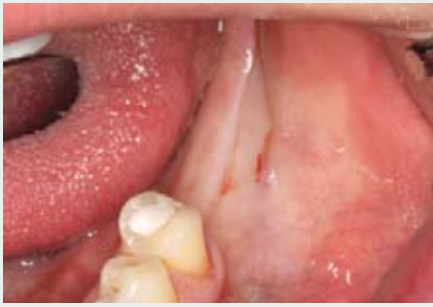**Dr. Thomas Barth:** For us, iSy is a concept with a clearly defined spectrum of indications. We use iSy in the mandible from the premolars onwards for single-tooth gaps and small edentulous gaps, in free end situations and in edentulous jaws for fixing prostheses; in the maxilla only for posterior use without augmentation and in the edentulous maxillary region for fixing prostheses.

**What was your first iSy patient case?**

**Dr. Thomas Barth:** We performed the first four operations on a single day. These were various indications from the above mentioned indication spectrum.

**Dr. Jan Klenke:** A lower number six.

**Dr. Manfred Wolf:** A five-pontic bridge in the posterior region on three implants.



A free end situation which was solved by using two iSy implants and occlusally screwed IPS e.max CAD restorations on CAD/CAM titanium bases (Photos: Dr. Thomas Barth/Stefan Ulrici).

### What is your experience with regard to the surgical procedure and open healing?

**Stefan Ulrici:** The surgical procedure works perfectly. iSy implants have excellent primary stability and we therefore already load them after eight weeks. Open healing is mandatory with iSy, which we highly appreciate for the iSy indications.

**Dr. Jan Klenke:** I find the drills very good, and also the implant thread. We already looked back on good experience with transgingival healing and have always appreciated the benefits. With iSy we have a system conceived for open healing, which is one of the reasons we like to use it.

**Dr. Manfred Wolf:** Surgical handling is extremely user-friendly. The drills are fantastic and the thread cutters are excellent. Transgingival healing is unusual for CAMLOG users. One first needs to become accustomed. In standard indications, transgingival healing is the simpler method and, as is known, one that works.

### How do you rate the prosthetic procedure, also in relation to DEDICAM, CAD/CAM prosthetics by CAMLOG?

**Stefan Ulrici:** Prosthetic restoration follows a simple, standardized procedure.

The multifunctional cap serves for impression taking and the model scan. The restoration is designed on the computer. As a rule we use hybrid abutment crowns, in other words a milled, customized IPS e.max CAD crown bonded to a CAD/CAM titanium base and screwed occlusally. We have no experience to date with DEDICAM, but this could be very interesting for us in the future for individual titanium abutments and bars, especially in conjunction with the CAMLOG Implant System.

**Dr. Manfred Wolf:** The multifunctional cap which is also used for impression taking, simplifies the procedure considerably. All the standard indications can be solved well with the available prosthetic components. The height and diameter of the CAD/CAM titanium bases meet our needs exceedingly well. We have not yet used DEDICAM, but are certain to try it in the future.

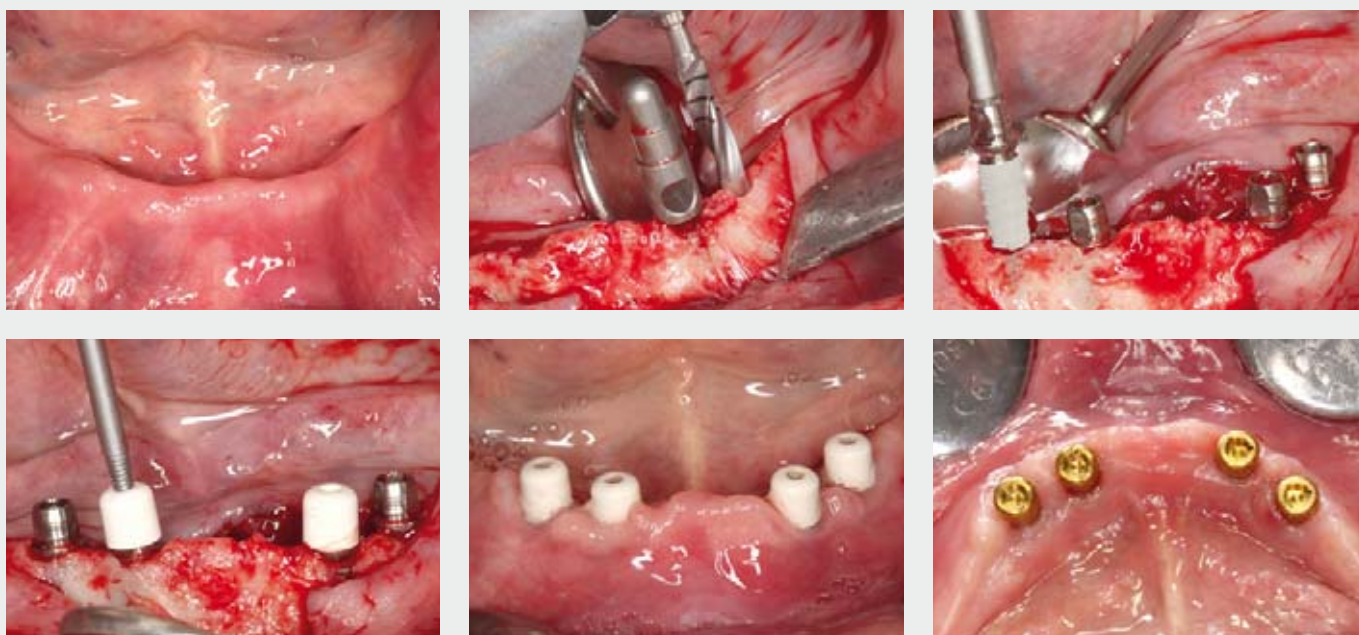
**Dr. Jan Klenke:** The feedback from my laboratory partners on iSy is positive. The titanium CAD/CAM bases are our first line of choice, but the universal abutment made of titanium alloy is also used regularly. The customized abutments which can now be realized with DEDICAM present a very useful option. However, their use depends on the degree to which the laboratory has already installed the digital process chain.

### In terms of the time factor, how does iSy compare to conventional implants systems?

**Dr. Thomas Barth:** The iSy system is designed fully to provide efficiency. This is already demonstrated by the three-step drill sequence, consisting of a round drill, the pilot drill and the single-patient form drill, but thus rather to be recommended with caution for beginners. Uncovery surgery and many intermediate steps are no longer necessary. The iSy concept clearly explains the procedure up to the prosthesis.

**Dr. Jan Klenke:** The surgical procedure with iSy is somewhat quicker than with conventional systems. Add to this considerably less effort in terms of preparing instruments due to single use and the small number of instruments for repeated use. The click system for placing the healing cap and the multifunctional cap works well.

**Dr. Manfred Wolf:** In surgery we save around 30 per cent of our time by using iSy when compared with other systems. Depending on the indication, it is possible to save even more time in prosthetics. The entire treatment structure is lean and standardized.



Use of four iSy implants in the edentulous mandible for later restoration with a Locator-retained prosthesis (Photos: Dr. Manfred Wolf).

### How do you manage iSy when counselling patients?

**Dr. Thomas Barth:** Initially our patients are only offered the variant which allows us all options and the greatest possible flexibility, i.e. restoration with the CAMLOG Implant System. Only once the findings and diagnostics have been completed and iSy could be an option due to the individual situation, and if we feel that the patient has reservations about the cost, do we introduce iSy. In such cases we tell patients that there is also an Implant System with a high degree of standardization, high quality "made in Germany", a time-saving treatment protocol and a favorable price. The solution is high value, functional, and tooth-colored. This is important for patients and highly appreciated.

**Dr. Jan Klenke:** For us, iSy is an additional option which we use on a very targeted basis in daily practice. We actively pursue this option with all patients where iSy can be used under consideration of their personal wishes and expectations. After all, iSy offers all the attributes we need for a high quality restoration.

**Dr. Manfred Wolf:** Communication with patients is changing. Patients will determine the extent of their dental prostheses far more in future than is presently the case. Talking with the patient is essential to find out about his/her wishes and in

order to suggest optimal restoration from their point of view. For example, we need to know whether highly individual esthetics play a major role for the patient or not.

### The favorable price of iSy should also make implants attractive for patients with limited budgets. Is this the case?

**Dr. Jan Klenke:** The overall concept of iSy may well make a restoration with implants attractive for more patients. For one, we have reduced surgical effort and prosthetic expenditure with iSy cases, which is of course reflected automatically in the charges billed. And secondly, iSy offers a favorable price and saves time. These two effects add up to considerable cost benefits for the patients and could lead to increased demand.

**Dr. Manfred Wolf:** iSy implant restorations are up to one third less expensive in our practice than when using CAMLOG Implant Systems. It is difficult to judge whether, and how many, patients we can attract in addition for implant restoration. But one thing is sure, price is becoming increasingly important.

**Stefan Ulrici:** The arithmetic certainly works. iSy restorations have become significantly less expensive in our practice and we were able to gain additional patients for implant restorations, mainly

younger ones, who would otherwise not have been able to afford implant treatment. 500 to 800 euros more or less for a single tooth — just to mention a figure — is a lot of money.

**Dr. Thomas Barth:** What is decisive for us is are the hourly rates for costs and services we need to generate in our practice. With iSy we are able to save considerable time in suitable cases. We have defined a therapy standard for each iSy indication which lies clearly below the usual price levels. This broadens our base for implant dentistry.

*Thank you for the interview.*



## NEW DISTRIBUTION PARTNER IN THAILAND STRENGTHENS ASIAN POSITION ON CAMLOG



In Thailand, dentists receive excellent training which also benefits implant dentistry. The implant market in Thailand currently accounts for about 70,000 placed implants per year nationwide by approximately 2,000 dental clinics. In contrast to conditions in other markets, Thailand offers attractive market growth.

Besides the "identical" international medical benefits of implant therapy, some parts of Asia offer additional incentives as esthetics play a major role in Far East cultures. And this is where implant dentistry often has the edge over conservative restoration methods and can offer patients considerably more in terms of improved quality of life.

Due to these facts and perspectives it made sense for the world-wide operating CAMLOG Group to decidedly increase its presence on the Thai market recently.

### **The new CAMLOG distributor – not an "unknown quantity" in the business**

With the Accord Corporation Limited, CAMLOG was successful in gaining a competent and highly attractive partner for the distribution of the CAMLOG product and service portfolio. This is a subsidiary of the US Henry Schein Inc. and the largest dental dealer in Thailand, led by Suchada Charnsethikul. Until a few years ago, the Accord Corporation was the official dealer of a known international competitor of CAMLOG and therefore has extensive knowledge and profound insider insights of the Thai implant market.

### **CAMLOG presentation – who we are, what we can do...**

On 22<sup>nd</sup> April, a senior CAMLOG delegation travelled to Bangkok to conduct an introductory event together with the Accord management in the Hotel Grand Millennium Sukhumvit, which received wide-spread interest and highly positive acclaim among local implantologists and dental physicians.

The event was attended by over 140 participants from across the country and was made up of important opinion leaders in the business and dentists of the Thai Implant Association.

The CAMLOG management was supported by competent dental support on their visit in the shape of Dr. Karl-Ludwig Ackermann, Filderstadt, who contributed greatly to the success of the event in his role as knowledgeable and convincing speaker.

### **... and what are the benefits for CAMLOG users**

In advance of the event, over 25 laboratories with more than 40 technicians were trained on the handling of the Implant Systems developed, manufactured and distributed by CAMLOG to ensure that sufficient knowledge and know-how was

available from day one to ensure success on the Thai market.

Following the meeting, numerous Training & Education events and workshops were held in Thailand's universities and private clinics.

**Conclusion:** With our convincing introductory event in Bangkok, we have been able to generate interest and awareness in the local market. This represents a promising basis for further CAMLOG market advances in Thailand.

A further highlight was the first course conducted in Germany for Thai specialists. The location for the course was the University of Freiburg, where, under the management of Professor Nelson, presentations were given, live surgery was experienced, including a hands-on session on pigs' jaws. The program in Wimsheim, where the CAMLOG production site is located, was rounded off by a tour of the factory and product presentations.

The course was a resounding success and we are pleased that our guests took a piece of CAMLOG back to Thailand.



## THE CAMLOGCONNECT CHALLENGE – WIN AN INVITATION TO THE 5<sup>TH</sup> INTERNATIONAL CAMLOG CONGRESS 2014 IN VALENCIA!

CamlogConnect is certainly appreciated: some 3,000 professionals from more than 61 countries have already joined the CAMLOG Community. CAMLOG does them justice and awards several prizes for contributions sent in by CAMLOG users by 31<sup>st</sup> March, 2014 and which will then be published on CamlogConnect.

### The competition

Entries may include case reports, videos or presentations with useful tips for surgeons or dental technicians for use with CAMLOG products or for the treatment planning and restoration. **Each entry received by 31<sup>st</sup> March, 2014 will automatically take part in the competition.**

### The prizes

Prizes include five invitations to the 5<sup>th</sup> International CAMLOG Congress in Valencia in June 2014. The participants are also invited to join the legendary Congress party. And there is an additional bonus of € 500.00 towards travel and hotel expenses.

### Who can participate?

All dentists, surgeons, dental technicians and dentistry students who are already members of CamlogConnect – or want to become one – are eligible. Membership in the CAMLOG Community is free.

### What to do?

Send us a case report, video or contribution to the section "Tips" via the website [www.camlogconnect.com/challenge](http://www.camlogconnect.com/challenge). Peter Hunt and his team will be happy to advise and help you prepare and translate your contribution from an editorial and graphic point of view.

### And this is what we wish all our CamlogConnect fans!

Continued interesting professional exchange in the CamlogConnect Community. We look forward to welcoming you as a winner in Valencia at the unique "Palau des Artes" and an unforgettable Congress.



Learn, share & enjoy!