

Special Edition

logo

Issue 8|2014
CAMLOG Partner Magazine



THE GUIDE SYSTEM

"One can be forced by changes, or even better – one can participate actively. We at CAMLOG are optimistic and readying ourselves for the challenges of today and tomorrow."



Dear readers,

since the days of the Ancient Greeks we know that everything is in flux. New solutions are always in demand in times of high dynamics. Today's challenges are different from yesterday's and have little in common with those of yesteryear. The world is changing at a dramatic pace. The media and communications are undergoing major changes and these fully affect our business, our market and our daily work.

All of us – the industry, dentists, surgeons and dental technicians – can expect our business with implants and restorative dentistry to continue to grow long-term, albeit with fluctuating demand cycles, but we will see some profound changes. This requires a high level of responsiveness, speed, continuous adaptation, performance, quality at all levels and in all areas, the application of new technologies and the courage to embark on new paths.

Courage for entrepreneurs means: challenging the habitual and venturing to new horizons. Being sustainable in the future always results from openness to new avenues.

Long-term thinking, which implies hardship today to achieve success tomorrow, is a question of cleverness and forward thinking – but also, and in particular, discipline.

The demographic change to an ever older society necessitates advancement in automation. Industry, dentists, surgeons and dental technicians face the challenge of organizing more and more cooperation internally and externally, optimizing interfaces and driving value creation processes.

Our future is digital. Advancing technology, starting with 3D diagnostics and digital impression taking via computer-guided planning and navigation through to CAD/CAM-fabricated restorations, will bring the complex interdisciplinary workflows in the restoration with implants closer together and simplify them. Greater involvement of the patient in the planning and design of his prosthetics is also possible.

One can be forced by changes, or even better – one can participate actively. We at CAMLOG are optimistic and readying ourselves for the challenges of today and tomorrow. We will continue to accompany you with our products in the future in a partner-like manner and continue successfully along our mutual path, especially with regard to your business opportunities in the dental practice and dental laboratory.

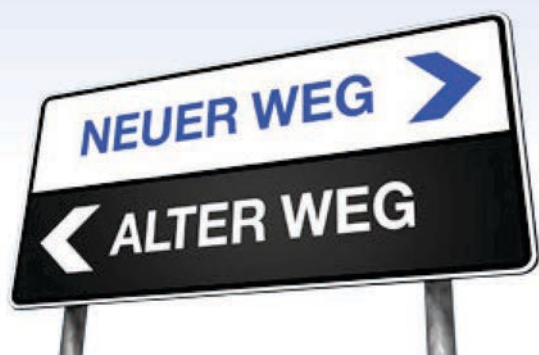Manage your practice or dental laboratory with passion and control your business with intelligence, people make the difference in success.

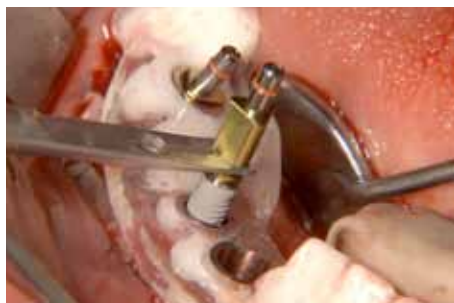Take the opportunity of networking with colleagues at our 5. International CAMLOG Congress in Valencia from 26. to 28. June 2014 and gain valuable knowledge from the workshops and the scientific program for your daily practice and a successful future.

My team and I look forward to welcoming you in Valencia.

Sincerely,

Michael Ludwig
Managing Director
CAMLOG Vertriebs GmbH





Title story

- Extended and modified Guide System for template-guided implantation 4



Case study

- 3D planning and template-guided implantation in fully and partially edentulous jaws 8
- The iSy implant concept – efficiency in daily practice 16



Science/Clinical research

- CAMLOG Foundation Consensus Report 7



Products

- New: The iSy cover cap – totally relaxing! 22
- The market trend for “digital dentistry” is gathering significant momentum 23



EXTENDED AND REVISED GUIDE SYSTEM FOR TEMPLATE-GUIDED IMPLANTATION

The CAMLOG Guide System is used for template-guided preparation of the implant bed and for insertion of CAMLOG® and CONELOG® SCREW-LINE implants in conjunction with 3D diagnostics and planning. Following its successful launch in the fall of 2008, the CAMLOG® Guide System will be extended by the CONELOG® SCREW-LINE implants as from May 2014 and continued under the name "Guide System".

The system includes implants with pre-assembled Guide insertion posts, as well as laboratory and surgical instruments. All components of the system are matched precisely to one another. Color-coded guide sleeves enable safe use. Additional sleeves and depth stops are not required.

The depths of the implant beds are prepared stepwise with guided single-use drills, and the implant is inserted accurately to the planned placement depth using the pre-assembled insertion post with guide shaft.

Since its introduction to the market, the users of the CAMLOG® Guide System have increasingly asked us to extend this system. The continuously growing usage of the CONELOG® Implant System increased the demand for CONELOG® Implants for template-guided insertion. In addition, more and more of the thinner implants are being placed.

	CAMLOG SYSTEM
	CONELOG SYSTEM
GUIDE SYSTEM TEMPLATE-GUIDED IMPLANTATION	
<small>Accurate guiding of instruments and implants Easy and convenient to use Single-use products - direct application of surgical instruments Compatible with several planning systems</small>	
<small>a perfect fit™</small>	camlog

The portfolio of the Guide System has been extended by CAMLOG® SCREW-LINE Promote® plus implants with diameters of 3.3 mm and lengths of 16 mm. These are now available in the lengths 9, 11, 13 and 16 mm and the diameters 3.3, 3.8 and 4.3 mm. CONELOG® SCREW-LINE Promote® plus implants are available in the Guide System with the lengths 7, 9, 11, 13 and 16 mm and the diameters 3.3; 3.8 and 4.3 mm.

The existing CAMLOG® Guide System is fully compatible with the new Guide System in terms of surgical application. When using the new sleeves and/or the new implant geometries, their geometries should already be saved in the 3D planning software – this is essential in the case of implant3D and CeHa imPLANT®.

Planning systems which include the new Guide System can be found on our website <http://www.camlog.com/products/digital-technique>.

Important note: the seating tool and the checkup pin of the old Guide System are no longer compatible with the new guide sleeves. A new seating tool and a new checkup pin are available for the new guide sleeves for the implant diameters 3.8 mm and 4.3 mm. If you have questions, please get in touch with your contact person at CAMLOG.

The product catalog 2014 for the CAMLOG® Implant System includes the Guide System with all its components for the insertion of CAMLOG® Implants.

The portfolio of the Guide System CAMLOG® SCREW-LINE implants, Promote® plus

Length	Ø 3.3	Ø 3.8	Ø 4.3
9 mm	---	✓	✓
11 mm	✓	✓	✓
13 mm	✓	✓	✓
16 mm	✓	✓	✓

The portfolio of the Guide System CONELOG® SCREW-LINE implants, Promote® plus

Length	Ø 3.3	Ø 3.8	Ø 4.3
7 mm	---	✓	✓
9 mm	✓	✓	✓
11 mm	✓	✓	✓
13 mm	✓	✓	✓
16 mm	✓	✓	✓



Pilot drill

The new system has been enhanced by the 2.0 mm pilot drill with guide shaft. Pilot drilling avoids a possible deflection of the form drill from its drilling axis in the case of very heterogeneous bone, if the drill template is not supported optimally, in immediate implantations and in the case of bicortical use. Lateral bone condensation in the case of largely cancellous bone is possible with the pilot drill using osteotomes.



Driver

In addition to the existing driver for manual insertion of the Guide implants, a driver with ISO shaft is now available for mechanical insertion. Both variants are now possible for implant insertion.

Improvements at a glance

New products:

- ✓ CONELOG® implants with Guide insertion posts with diameters 3.3, 3.8 and 4.3 mm and lengths 7, 9, 11, 13 and 16 mm.
- ✓ CAMLOG® implants with Guide insertion posts with a diameter of 3.3 mm from lengths of 11 mm.
- ✓ CAMLOG® Implants with Guide insertion posts with a length of 16 mm for all available diameters.
- ✓ Guide pilot drill with a diameter of 2.0 mm.
- ✓ Guide driver with ISO shaft, for mechanical insertion of the Guide implants.
- ✓ Laboratory and surgical instruments for implant diameters 3.3 mm and for the implant lengths 7 mm (only CONELOG®) and 16 mm.

Product modifications:

- ✓ The guide sleeves are reduced in height from 4 mm to 3 mm. Lateral flattening allows integration in narrow interdental gaps without manipulation. A drill hole on the upper side serves as marking for alignment of the inner geometry of the implant.
- ✓ Form drills now have four cutting edges instead of two to provide improved concentricity.
- ✓ Single-use instruments have the CAMLOG-specific color coding to clearly correlate them to the selected implant diameters. Surgical drills are fitted with clearly legible length and diameter information which facilitates correlation in addition to diameter-specific color coding.
- ✓ Template drills with spiral instead of spatula shaped cutting edges for drilling true to shape



Guide sleeve

The guide sleeve is reduced in height from 4 mm to 3 mm and laterally flattened. The reduced height offers the option of minimally invasive surgery and implantation. This treatment concept can be employed in cases where the lower edge of the sleeve can be placed on or above the gingiva according to 3D planning.



Form drill

The concentricity of the single-use form drills with internal irrigation has been optimized with four cutting edges with peck drill grooves. This enhances the caring preparation of the implant bed, also in case of thin bone lamellae. All surgical drills are fitted with circumferential color coding on the shaft. Length and diameter are lasered for fast and clear assignment.



CAMLOG FOUNDATION CONSENSUS REPORT

The CAMLOG Foundation is committed to the promotion of scientific knowledge in dental dentistry. To this purpose, the CAMLOG Foundation organized an international meeting of experts in Rome in January 2013. Around 80 specialists from 16 countries discussed two topics which were prepared as systematic views. The CAMLOG Foundation Consensus Report was published as result of the expert meetings.

In a systematic overview paper and meta analysis, Strietzel et al. (2014) investigated the effect of platform switching on the marginal, peri-implant bone level, whereas Schwarz et al. (2014) investigated the effect of the implant-abutment connection and the positioning of the micro gap and the rough-smooth boundary at the implant neck on the crestal bone level in a systematic review paper.

Divided into groups, the clinical treatment approaches were discussed and the evidence weighed with regard to their effects on the implant-abutment connection, the positioning of the micro gap and the rough-smooth boundary on the implant neck and platform switching on marginal bone level. The results of these meetings and the discussion were summarized in form of a consensus report.

The widespread transfer and conveyance of evidence-based knowledge is important for the well-being of the patient. The CAMLOG Foundation Consensus Report

as well as the two systematic reviews by Schwarz et al. and Strietzel et al. were published in peer-reviewed journals:

Strietzel FP, Neumann K, Hertel M. Impact of platform switching on marginal peri-implant bone-level changes. A systematic review and meta-analysis. *Clin Oral Impl Res.* 00, 2014, 1-16. doi: 10.1111/clr.12339.

Effect of platform switching on changes of the peri-implant bone level: A systematic overview of the literature and meta analysis.

Schwarz F, Hegewald A, Becker J. Impact of implant-abutment connection and positioning of the machined collar/micro gap on crestal bone level changes: a systematic review. *Clin Oral Impl Res.* 25, 2014, 417-425. doi: 10.1111/clr.12215.

Effect of the implant-abutment connection and the position of the micro gap and machined implant neck on crestal bone changes: A systematic overview of the literature.

Schwarz F, Alcoforado G, Nelson K, Schaer A, Taylor T, Beuer F, Strietzel FP. Impact of implant-abutment connection, positioning of the machined collar/microgap, and platform switching on crestal bone level changes. *Camlog Foundation Consensus Report. Clin Oral Impl Res.* 00, 2013, 1-3. doi: 10.1111/clr.12269.

Effect of the implant-abutment connection, the position of the micro gap and machined implant neck and of platform switching on crestal bone changes. CAMLOG Foundation Consensus Report.

To provide general access and for widespread communication of the recommendations, the three publications were prepared as Open Access files and are available online free of charge. The corresponding links can also be found on the website of the CAMLOG Foundation www.camlogfoundation.org and menu point "Publications/Consensus".

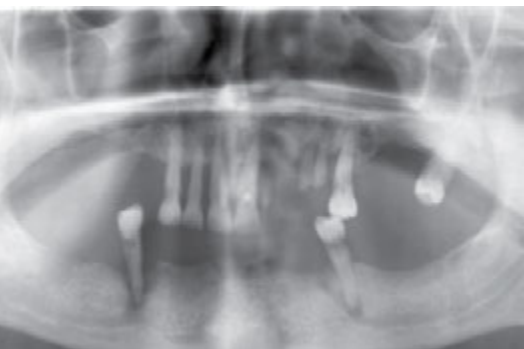

Fig. 1: The panorama layer image of the 49-year old patient shows the extremely poor condition of the remaining dentition with pronounced bone loss.

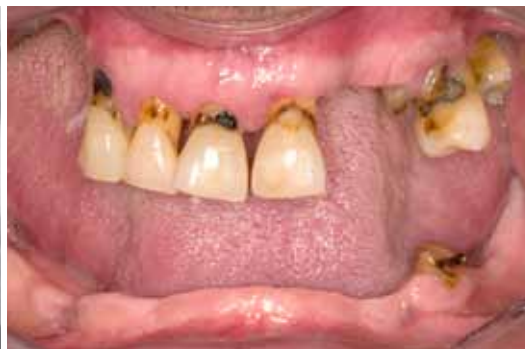

Fig. 2: The patient presents in the dental practice without dentures. The remaining teeth display extensive caries lesions.

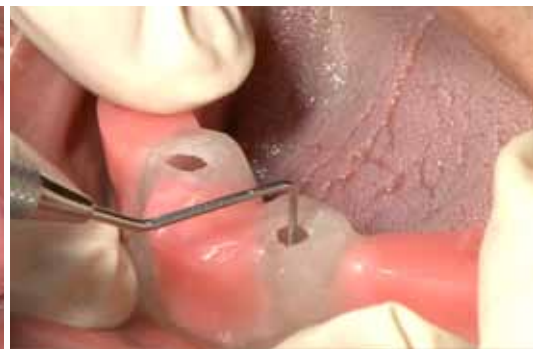

Fig. 3: With the aid of an individually prepared orientation template, the positions of the interim implants are marked on the mucosa.



3D PLANNING AND TEMPLATE-GUIDED IMPLANTATION IN FULLY AND PARTIALLY EDENTULOUS JAWS

Dr Karl-Ludwig Ackermann, Dr Axel Kirsch and MDT Gerhard Neuendorff, all Filderstadt



“Fewer visits to the dentist, favorable prices and attractive esthetics”, those are the demands of today's patients. To meet these demands, the integration of digital process chains in the dental practice and the laboratory is an essential tool. Hard and soft tissue defects are visualized realistically and serve as basis for preparing implant-prosthetic treatment concepts in fully and partially edentulous jaws. Taking the clinical situation and the esthetic wishes of the patient into account, a case-specific prosthetic restoration is defined and initially prepared as a wax-up. The aimed for prosthetic treatment goal forms the basis for implant planning. For example, functional esthetic immediate restoration can be realized through 3D planning and computer-guided, template-guided implant insertion [1,2]. If the backward planning concept is rigorously applied, the treating team is in a position of delivering high quality and long-term stable rehabilitation.

The two following examples illustrate restoration options whereby the individual treatment steps have been summarized. To save time and costs, the number of surgical interventions can be reduced in some cases of immediate restorations [3,4,5]. The CAMLOG® Guide System is especially suited for realizing strategically determined and controlled treatment planning with the aid of planning software. Knowledge of the surgical and technical possibilities of the system used are essential to provide an exact fit of the planned rehabilitation. With consequent pre-planning, an immediate restoration

with tension-free fit is also possible by employing the Passive-Fit technique.

First case study Computer-guided immediate restoration in an edentulous jaw

A 49-year old patient requested comprehensive prosthetic restoration. His teeth are not worth preserving and need to be extracted (**Figs. 1 and 2**). After a detailed consultation he decided to opt for a screw-retained, implant-supported bridge in the lower jaw and, initially, a mucosa-supported complete denture. The lower

jaw bridge was to be inserted immediately following implantation.

The required exact prosthetically oriented implant positioning is best performed with a template-guided insertion. As mucosa-supported planning and transfer templates lead to imprecision due to soft tissue resilience [6], four interim implants are placed in this patient case. The templates and the interim restoration can be anchored on these with the aid of ball abutment [5,7]. An orientation template is prepared as positioning aid for inserting the interim implants (**Fig. 3**). At the same

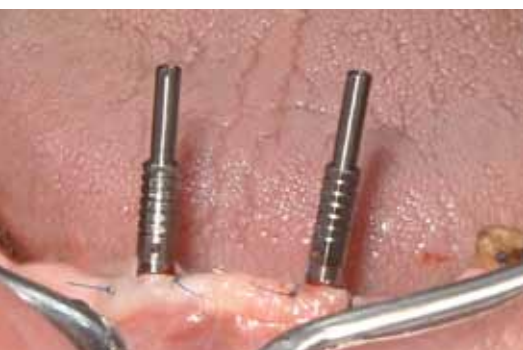

Fig. 4: The four interim implants are inserted following minimally invasive flap preparation.

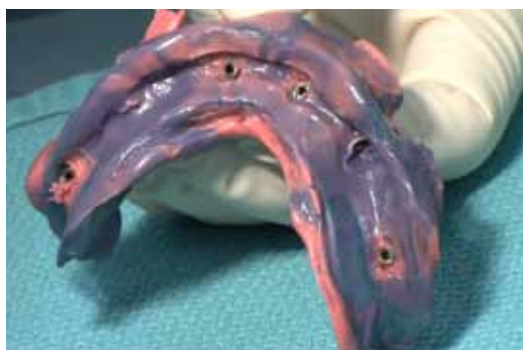

Fig. 5: The insertion posts of the interim implants serve as impression posts for the pick-up and the orientation template as individual impression tray.

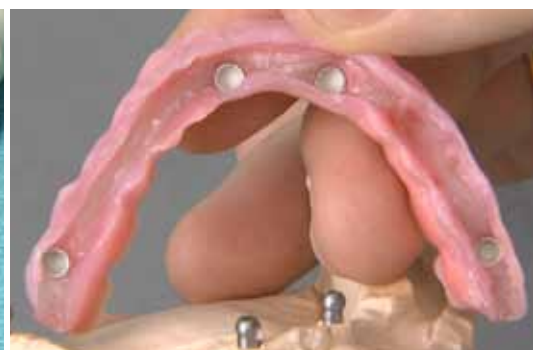

Fig. 6: Ball abutments are screwed into the interim implants on the master model. They serve to provide exact fixation of the CAMLOG® Guide drilling template.

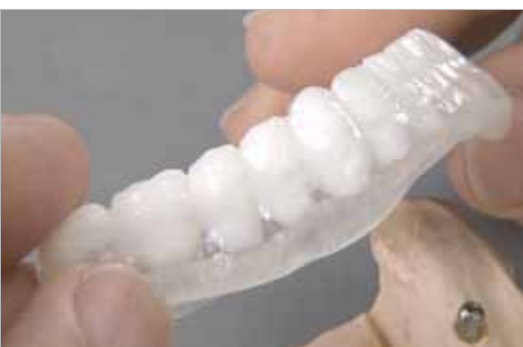

Fig. 7: The planning template for the CT or DVT image is prepared from barium sulphate-containing plastic teeth with anatomical crown emergence profile.

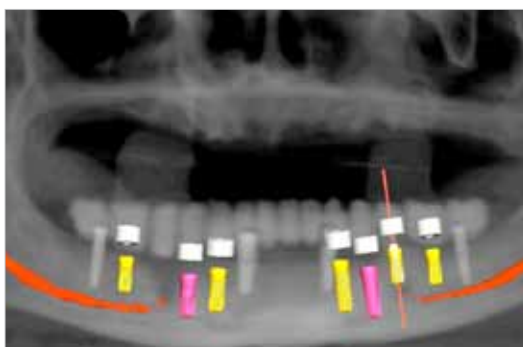


Fig. 8: The implants are positioned digitally and prosthetically correct. Three implants were regarded as being sufficient in the third quadrant.

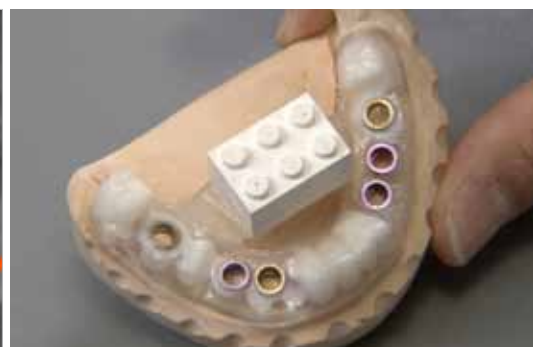

Fig. 9: The planning template is modified into a Guide drilling template according to the three-dimensional planning.

time, this is used for bite registration and also as individual tray for impression taking of the lower jaw and the interim implants (**Figs. 4 and 5**).

Planning and fabrication of the prosthesis

After impression taking, the dental technician prepares the master model with the lab analogs of the interim implants. Ball abutments are screwed into the interim implants to fixate the wax-up and restoration (**Fig. 6**). Following a functional, phonetic and esthetic try-in, bite registration is performed in practice for a final correction. The wax-up is duplicated and a planning template fabricated from radiopaque plastic with a glass-clear prosthetic base for digital computer-guided tomography (**Fig. 7**). With the aid of the software (implant3D®, med 3D), the implant positions and lengths can be planned precisely in terms of the final prosthetic restoration (**Fig. 8**). Then the planning template is converted to a transfer template and the guide sleeves of the CAMLOG® Guide System are incorporated (**Fig. 9**).

To fabricate the pre-implant denture, the dental technician fixates the transfer template to the ball abutments of the interim implants and marks the implant positions on the master model through the sleeves. The template is removed and the master model ground in these areas taking into account the inclination of the implant axis. The lab analogs are screw-retained with the CAMLOG® Guide insertion posts and fixated with sufficient bonding wax in the sleeves in their exact position to ensure positioning. The template is then placed on the ball abutments and the lab analogs mounted on the model with plastic (**Figs. 10 and 11**).

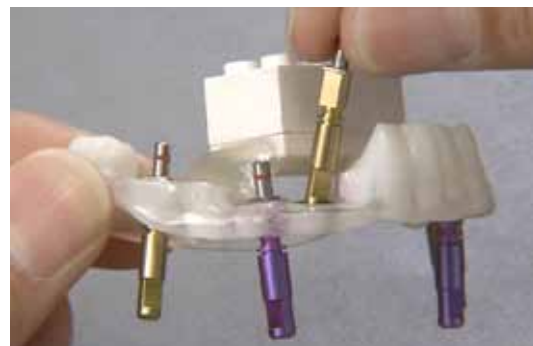

Fig. 10: The CAMLOG® Guide insertion posts and lab analogs are screwed together and fixated in the sleeves of the template.

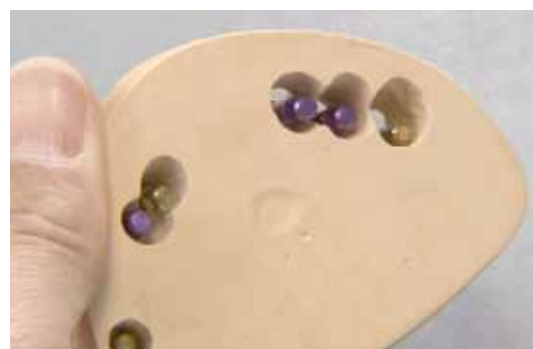

Fig. 11: The lab analogs are fixed with plastic in the ground implant areas in the model.



Fig. 12: Lab analog, Vario SR abutment, Vario SR lab screw, Vario SR titanium cap and Vario SR prosthetic screw.



Fig. 13: The Vario SR titanium caps are shortened according to the wax-up. This is checked with a silicone matrix.



Fig. 14: An evenly large bonding gap between the titanium cap and the metal reinforcement is decisive for the Passive-Fit of the superstructure.

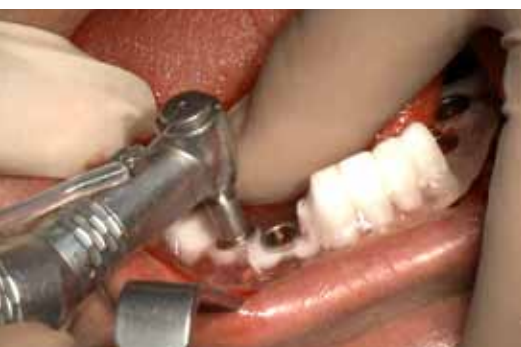

Fig. 18: Template-guided preparation of the implant beds. The cylindrical guide shaft prevents abrasion in the sleeves.

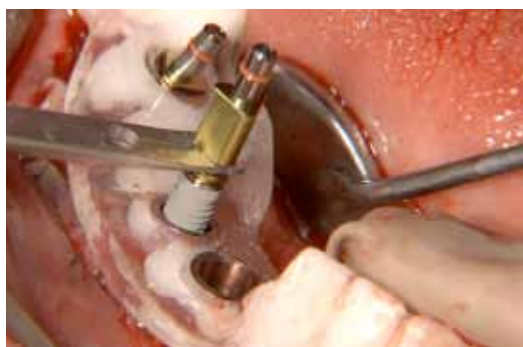

Fig. 19: Insertion of the SCREW-LINE implants CAMLOG® Guide, Promote® plus.

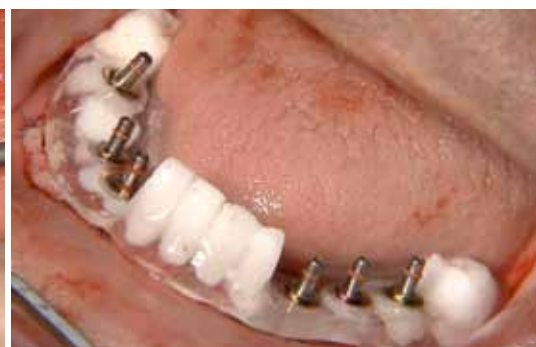

Fig. 20: As on the model – one groove of the inner configuration of the six inserted implants is directed vestibular in each case.

A metal reinforcement is fabricated for the partly removable dentures on the CAMLOG® Vario SR abutments. The abutment system consists of pre-fabricated conical abutments (straight, 20° and 30° angle) and different screw components for the superstructure (**Fig. 12**). The treatment team decided in favor of straight CAMLOG® Vario SR abutments with screw titanium caps, which are later bonded tension-free in the mouth to the metal reinforcement of the restoration (**Fig. 13**). A bonding gap is prepared between the metal reinforcement and the Vario SR titanium caps during the fabrication process to ensure a passive fit of the structure (**Fig. 14**). The frame is supported in the region of the ball abutments. This ensures bonding the titanium caps in their correct position while at the same time relieving the final implants during healing (**Fig. 15**). The wax-up is transferred to the metal reinforcement with the aid of the silicone index (**Fig. 16**) and then transformed to plastic. In the basal region care should be taken to ensure adequate oral hygiene potential for the screw-retained bridge. At the same time the dental technician

can prepare the occlusal access canals for the screws. Following preparation and polishing, the prosthetic restoration is now completed – even before insertion of the implants on which it will be supported.

Implantation and insertion

At the time of implantation, three interim implants and a fractured tooth are still present in the lower jaw. The interim implant in position 37 has become loose and had to be removed prior to final implantation. Tooth 34 is carefully removed preoperatively. Following crestal incision, a mucoperiosteal flap is prepared up to the mucogingival border. Then a split flap preparation is performed at the level of the mucogingival margin from the inner side of the flap. The myoperiosteum remains on the bone. To give a better overall view, the combined mucoperiosteal-mucosal flap is fixated to the inner side of the flap with sutures (**Fig. 17**). The implant template can be mounted in a secure position on the balls of the interim implants without the flap interfering. This is followed by the guided preparation of the implant

bed with the CAMLOG® Guide System (**Fig. 18**). The internal irrigation single-patient drills are used intermittently with sterile saline solution to avoid thermal damage to the bone. Preparation is guided precisely at a consistent diameter and stepwise increasing length. Then the SCREW-LINE implants CAMLOG® Guide, Promote® plus are inserted (**Fig. 19**). They are inserted until the CAMLOG® Guide insertion post is seated on the sleeve. If angled abutments are to be used, then the alignment of the grooves in the implant is of special significance and marking on the sleeve proves useful (**Fig. 20**). As a next step, the insertion posts and the template are removed, the CAMLOG® Vario SR abutments and titanium caps screwed together and the soft tissue sutured (**Fig. 21**). To reduce loading of the final implants during the primary healing time, the interim implants can be used additionally to support the restoration.

The “neutral” fit of the screw bridge is checked with FIT CHECKER™ (GC) and possible points of interference are ground. Then the screw access canals of the titanium caps are blocked, the



Fig. 15: The metal reinforcement is mounted on the ball abutments to support the superstructure during bonding in the mouth.

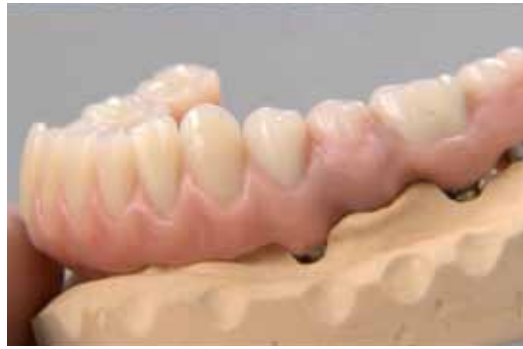

Fig. 16: The wax-up is transferred to the metal reinforcement, completed, and the screw access canals to the prosthesis screws ground free.

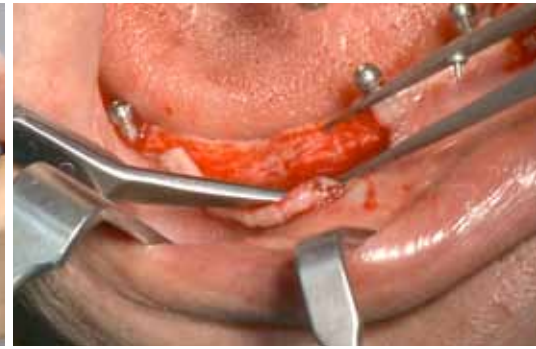

Fig. 17: Preparation of the implant bed: Following crestal incision and preparation of the mucosal flap, the intruding ligaments and muscles were dissected.

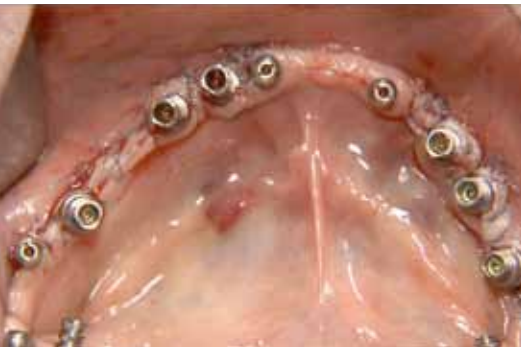

Fig. 21: The CAMLOG® Vario SR abutments and the corresponding titanium caps are screwed together and the soft tissue carefully sutured.

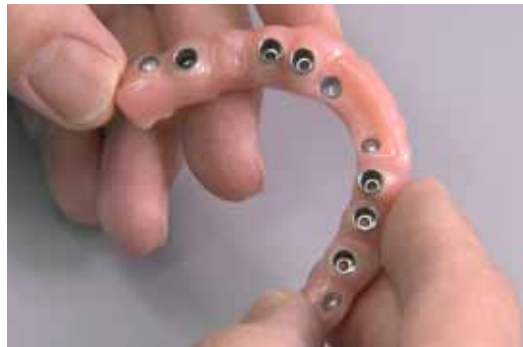

Fig. 22: The finished superstructure from basal following intraoral bonding, finishing and polishing.

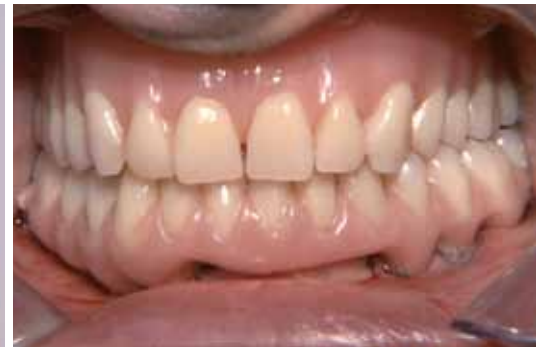

Fig. 23: The patient leaves the dental practice directly after surgery with the screw-retained bridge.

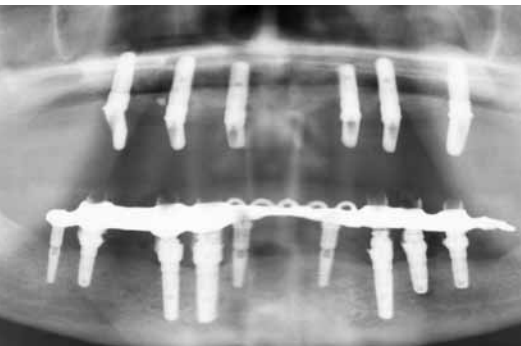


Fig. 24: Six months after restoration of the lower jaw the patient also decided in favor of implant-supported dentures in the upper jaw.

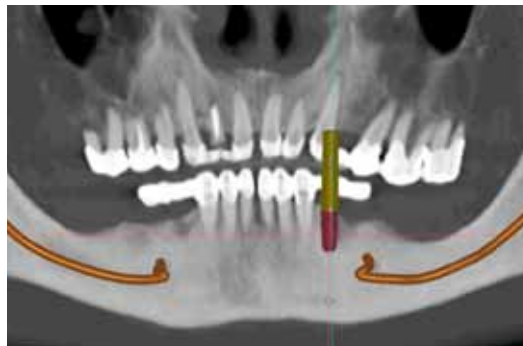


Fig. 25: The screenshot from the planning program shows a panorama view with free-end gaps on both sides in the lower jaw and a planned implant in position 34.

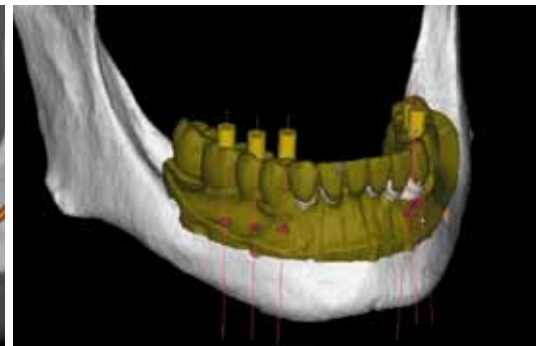

Fig. 26: The CT data are matched with the scan model in the software.

metal components for bonding cleaned, surface-conditioned, and the restoration bonded tension-free in the mouth.

Figure 22 displays the bridge from the basal side after preparation and polishing. At the end of the implantation session the patient leaves the dental practice with a functional, esthetically pleasing and perfectly designed prosthesis which is also suitable for oral hygiene (**Fig. 23**). He is so satisfied with his new restoration that he later also decides to have an implant-supported restoration in the upper jaw instead of the originally planned complete prosthesis (**Fig. 24**).

Second case study Template-guided implantation in the partially edentulous jaw

The second patient, also aged 49 years, wanted rehabilitation of both jaws with full ceramic crowns. As teeth were missing on both posterior sides in the lower jaw, three implant-supported single crowns each were planned. Following pretreatment, two metal-reinforced temporary extension bridges were inserted for a transitional period (**Fig. 25**). A CT image was made of this initial situation, together with a situation

impression of the lower jaw over the prepared anterior teeth. The model of the lower jaw is scanned in the laboratory and matched with the CT data using the planning software (SimPlant®, Materialise) (**Fig. 26**).

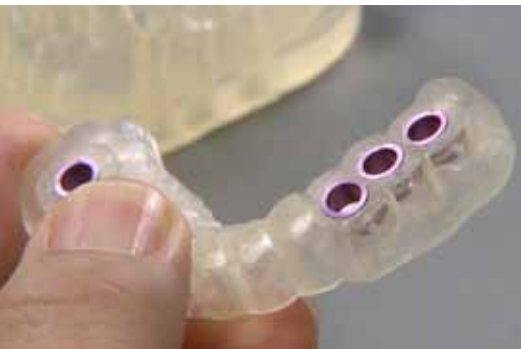

Fig. 27: The stereolithographically fabricated drilling template with the color-coded CAMLOG® Guide Guiding sleeves.

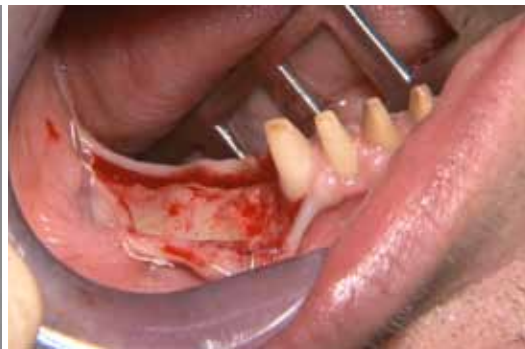

Fig. 28: The alveolar ridge is presented following crestal incision. The bone edges are smoothed prior to implantation.

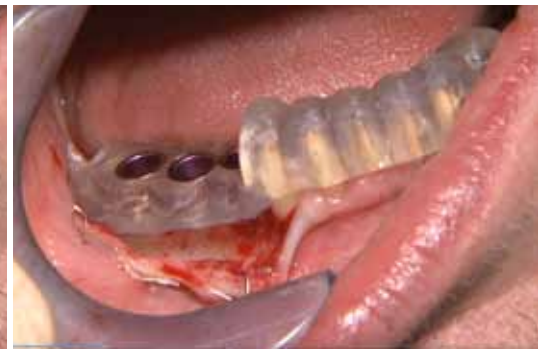

Fig. 29: The Guide drilling template is mounted in stable position on the prepared tooth stumps. Preparation commences with a short form drill.



Fig. 33: The mucosa profile was marked on the universal abutment. The abutment is mounted on the universal holder.

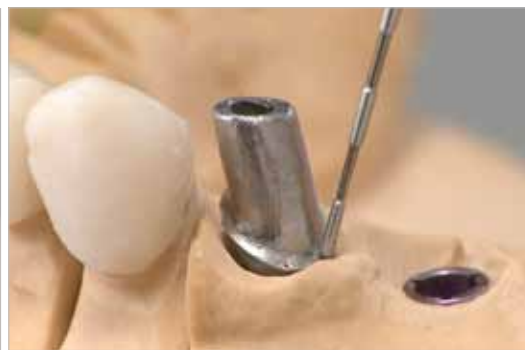


Fig. 34: The marginal profile of the customized abutments is checked, first on the model, ...

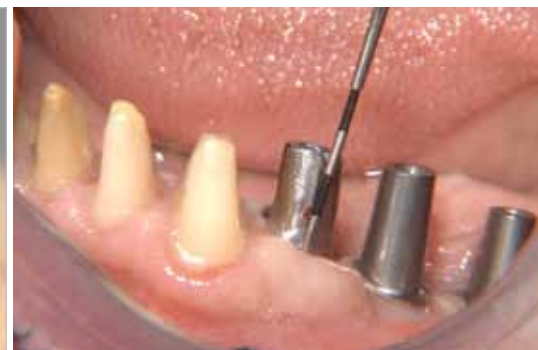

Fig. 35: ... then also intraorally. This way the later crown edge can either be corrected immediately in the dental practice or later in the laboratory.

The implant positions (suitable diameters and lengths) are defined by the treating team on the computer. Now the transfer template with incorporated CAMLOG® Guide Guiding sleeves can be ordered and fabricated externally (**Fig. 27**).

Guided implantation

The support of the transfer template on the prepared teeth is checked precisely as the precision of implant bed preparation and implant position depend on this. To this purpose the temporary bridge is removed and cement debris removed from the prepared teeth. Following crestal incision, the mucoperiosteal flaps are prepared on both sides and sutured to give a better overview (**Fig. 28**). Now the transfer template is inserted and the implant beds prepared with the CAMLOG® Guide System, as described in the previous case (**Fig. 29**) and the SCREW-LINE implants CAMLOG® Guide, Promote® plus inserted (**Fig. 30**). Healing is transmucosal using healing caps.

Impression taking and insertion

After ten weeks the implants are osseointegrated and impressions taken without a second surgical intervention. The treatment team uses hydrocolloid for impression taking to give exact details of the oral situation. As a special cooled tray needs to be used here, the impression posts for the closed tray technique with the color-coded impression caps are used here (**Figs. 31 and 32**).

The dental technician selects the suitable abutments for the master model and customizes them (**Fig. 33**). The preparation border of the abutment is placed approximately one millimeter below the gingival margin. This ensures that the cement debris can later be removed completely from the sulcus, that the restoration is suitable for oral hygiene, and that the crowns have a natural emergence profile. To check the preparation border, an abutment try-in is always performed in the

mouth (**Figs. 34 and 35**). The zirconium crowns for full ceramic restoration are fabricated in the laboratory; twelve tooth-supported crowns, two bridges and six implant-supported crowns (**Figs. 36 to 38**). Occlusion is checked as part of the function and esthetic try-in as is the cleanability of the restoration (**Fig. 39**). Following fine corrections, the final abutments are screwed to the implants, the previously conducted parameters are checked and the full ceramic restoration is then fixated with carboxylate cement. The satisfied patient leaves the dental practice with a functional, esthetically pleasing prosthesis with an excellent long-term prognosis (**Figs. 40 and 41**).

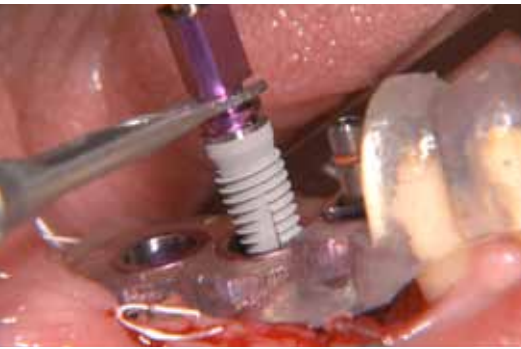

Fig. 30: Using the Pick-Up instrument, the implants are removed safely from the blister pack and transferred to the implant region.

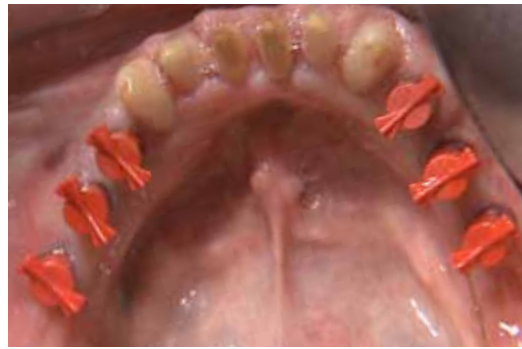

Fig. 31: For impression taking, the impression posts for the closed tray impression technique are screwed into the implants and the impression caps mounted.

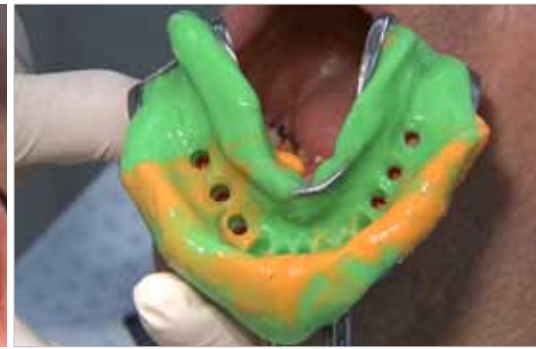

Fig. 32: Closed impression taking of implants and prepared tooth stumps is performed with hydrocolloid approximately after ten weeks of healing.



Fig. 36: The unsintered and sintered zirconium oxide caps in comparison: The previously stained ceramic has been shrunk in a controlled manner.

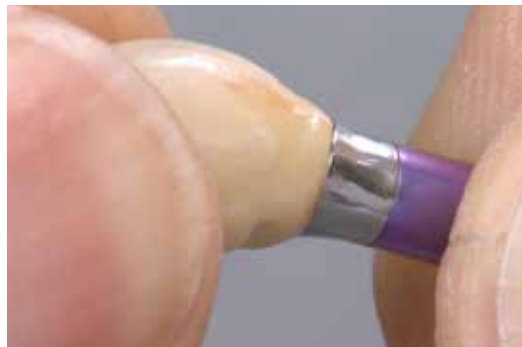

Fig. 37: The fit of the finished veneered crowns is checked.

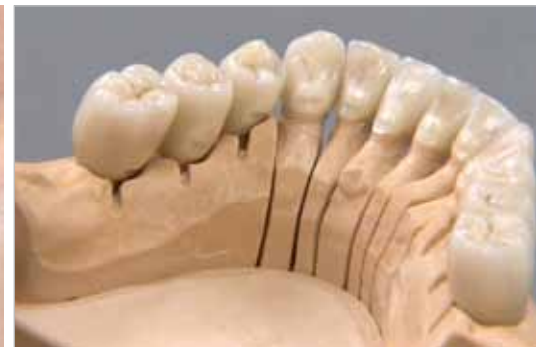

Fig. 38: The zirconium crowns in the lower jaw on the model. The removal aids placed in the crown framework can be seen clearly.

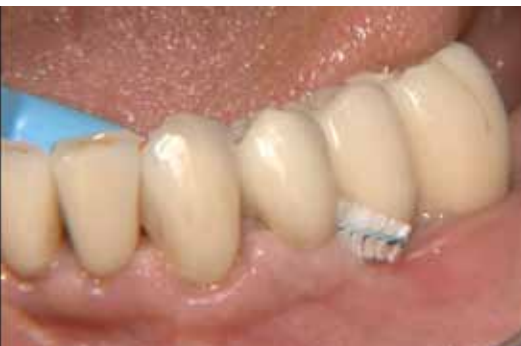

Fig. 39: All interdental spaces, also in the region of the implants, can be cleaned well with interdental brushes.

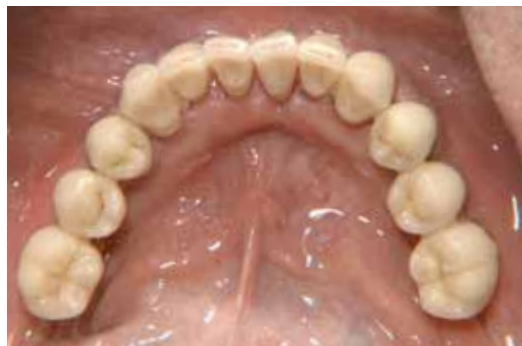

Fig. 40: The implant-supported crowns (34,35,36 and 44,45,46) are harmoniously integrated in the dental arch.

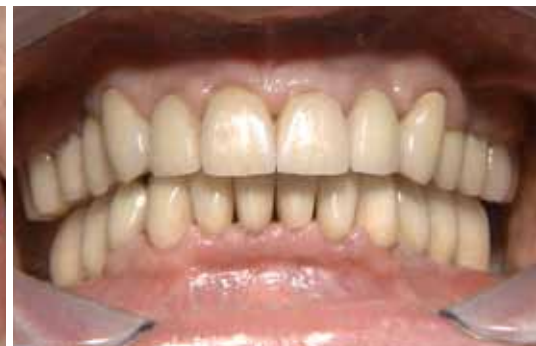

Fig. 41: The full ceramic complete rehabilitation is completed. Overall, 18 full ceramic single crowns and two bridges were integrated.

DISCUSSION

Computer-guided implantation contributes to best possible functional and esthetic results. Consequent backward planning proves to be a sensible and up-to-date further development of the analog concept, particularly in the case of extensive restorations [5]. In order to achieve the desired goal as accurately as possible, all work steps and the instruments used as well as the implant systems need to be precisely matched.

The CAMLOG® Guide System is part of an overall concept and achieves its high accuracy through exact guiding of the form drills in the sleeves in combination with the SCREW-LINE implants CAMLOG® Guide, Promote® plus.

Due to the consistent drill diameters neither sleeves nor templates need to be changed. A major effect on exact position transfer is provided by the

positional stability of the template which can be supported well with existing remaining dentition [8]. Interim implants are used to support the template in the edentulous jaw as described in the first patient example. They ensure the same high level of precision as tooth-supported templates [7,9].

CONCLUSION

Depending on the initial patient diagnosis, the temporary or final prosthetics can already be fabricated in advance on the basis of the planning data and placed immediately after implantation [4, 5]. In these cases, backward planning needs to be applied consistently and computer-guided planning and implementation must be followed strictly.

Even if all details are followed, a certain tolerance level will always exist with computer-guided implantation. If the prefabricated prosthetics are screwed directly to the implants in immediate restorations, this can lead to tension which in turn can lead to marginal bone deterioration and implant loss [10]. These tolerances can largely be avoided by using the Passive-Fit technique with intraoral bonding, as shown in the first patient case, an example for the intelligent combination of digital and analog prosthetic methods.

LITERATURE

- [1] Kirsch A, Ackermann K-L, Neuendorff G, Nagel R. New paths in implant prosthetics. Der klinische Einsatz des Camlog-Systems. Teamwork Journal of Multidisciplinary Collaboration in Prosthodontics 2000;3:8-39.
- [2] Garber DA, Belser UC. Restoration-driven implant placement with restoration-generated site development. Compend Contin Educ Dent 1995;16:796, 798-802, 804.
- [3] Harris D, Horner K, Grondahl K, Jacobs R, Helmrot E, Benic GI, et al. E.A.O. guidelines for the use of diagnostic imaging in implant dentistry 2011. A consensus workshop organized by the European Association for Osseointegration at the Medical University of Warsaw. Clinical oral implants research 2012;23:1243-1253.
- [4] Spiegelberg FE, Buhl C. Vierdimensional rückwärts geplant. Temporäre Implantatbrücke mit digital erstellter Weichgewebemaske. J Dent Educ 2011;612-620.
- [5] Kirsch A, Nagel R, Neuendorff G, Fiderschek J, Ackermann KL. Backward Planning und dreidimensionale Diagnostik. Teil 2: Schablonengeführte Implantation nach CT-basierter 3D-Planung mit sofortiger Eingliederung des präfabrizierten Zahnersatzes - ein erweitertes Backward Planning-Konzept. Teamwork Journal for Continuing Dental Education 2008;11:734-753.
- [6] D'Haese J, Van De Velde T, Elaut L, De Bruyn H. A prospective study on the accuracy of mucosally supported stereolithographic surgical guides in fully edentulous maxillae. Clinical implant dentistry and related research 2012;14:293-303.
- [7] Holst S, Blatz MB, Eitner S. Precision for computer-guided implant placement: using 3D planning software and fixed intraoral reference points. J Oral Maxillofac Surg 2007;65:393-399.
- [8] Ozan O, Turkyilmaz I, Ersoy AE, McGlumphy EA, Rosenstiel SF. Clinical accuracy of 3 different types of computed tomography-derived stereolithographic surgical guides in implant placement. J Oral Maxillofac Surg 2009;67:394-401.
- [9] Widmann G, Keiler M, Zangerl A, Stoffner R, Longato S, Bale R, et al. Computer-assisted surgery in the edentulous jaw based on 3 fixed intraoral reference points. J Oral Maxillofac Surg 2010;68:1140-1147.
- [10] Oyama K, Kan JY, Kleinman AS, Runcharassaeng K, Lozada JL, Goodacre CJ. Misfit of implant fixed complete denture following computer-guided surgery. Int J Oral Maxillofac Implants 2009;24:124-130.



Dr Karl-Ludwig Ackermann

is a specialist in oral surgery and has been working in the field of oro-maxillo-facial implant dentistry since 1980. He is a recognized specialist for periodontology in the EDA (European Dental Association) and works in joint practice with Dr. Axel Kirsch. Dr Ackermann is a board member of the DGI (German Society for Implant Dentistry) and the DGZMK (German Society for Dental and Oral Medicine), lecturer at the APW (Academy of Practice and Science) and the Steinbeis University Berlin (for implant prosthetics and esthetic dentistry) and visiting professor at the Nippon Dental University Niigata, Japan.



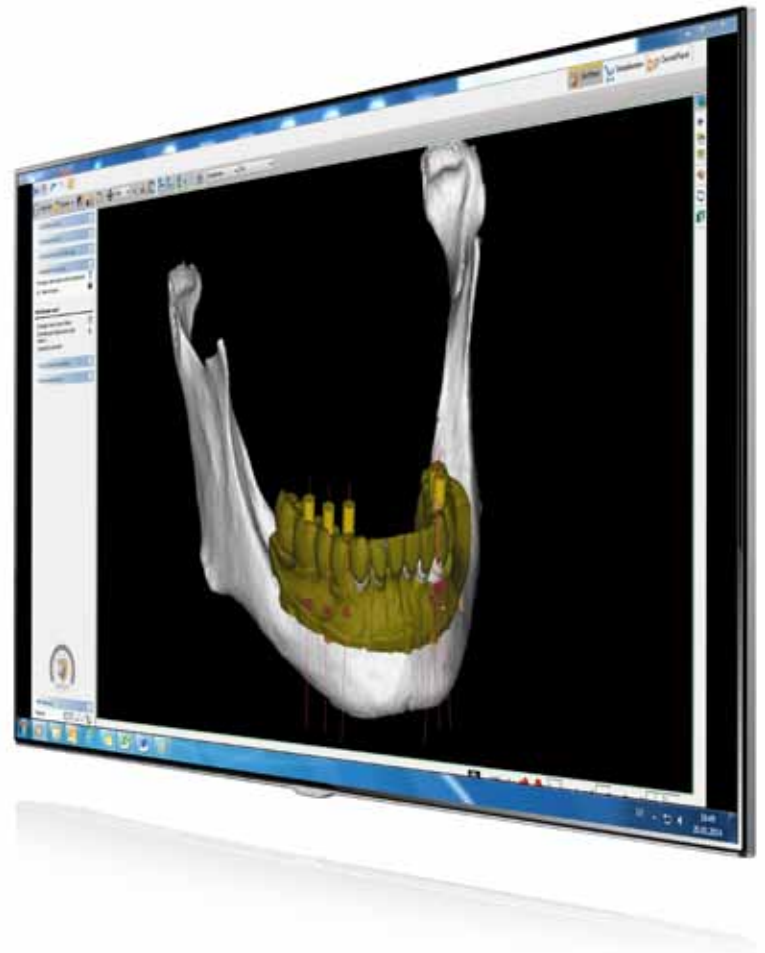
Dr Axel Kirsch

set up his own dental practice in Filderstadt in 1974 after qualifying as specialist for oral surgery. The development of the CAMLOG® implant system in the 1990's is based on his experimental, clinical scientific activities and results in the field of oromaxillofacial implant prosthetics. Dr Axel Kirsch has visiting professorships at various universities in the USA and Japan.



MDT Gerhard Neuendorff

is the head of the ZIF Innovationsschmiede (Dentaltechnik Dr Kirsch GmbH) in Filderstadt. He played a key role in developing the CAMLOG® Implant System for the field of dentistry. Gerhard Neuendorff is a recognized expert in the field of pre-prosthetic planning, implant prosthetics, titanium processing, electroplating technology and full-ceramic restoration techniques.



Experience this publication as a video! It comes from the video compendium "Implantatprothetik VIER TEAMS – IHRE KONZEPTE UND LÖSUNGEN" (Implant prosthetics FOUR TEAMS – THEIR CONCEPTS AND SOLUTIONS) (Quintessenz Verlag). Volume 1 with Dr Axel Kirsch, Dr Karl-Ludwig Ackermann and MDT Gerhard Neuendorff covers 3D planning and template-guided implantation in partially and fully edentulous jaws. The video compendium is available from CAMLOG as a DVD or Blu-Ray disc.

Our special thanks to MDT Janez Fiderschek, MDT Christine Hammerl-Riempp and Norbert Schweier for the technical explanations.

Contact information

Joint practice

Drs Kirsch & Ackermann

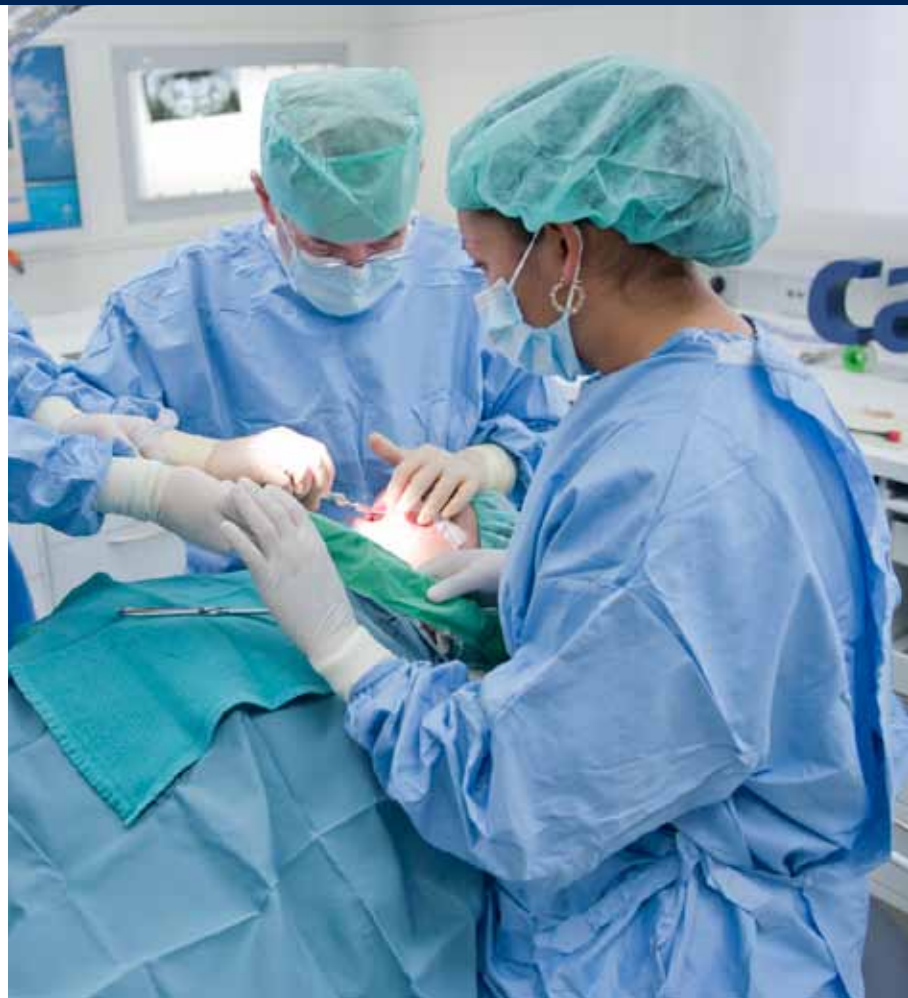Talstraße 23
D-70794 Filderstadt

Secretariat Dr Ackermann
Phone.: +49 (0)711 7088166
E-mail: kl.ackermann@kirschackermann.de

ZIF Innovationsschmiede

Dentaltechnik Dr. Kirsch GmbH

Talstraße 23
70794 Filderstadt



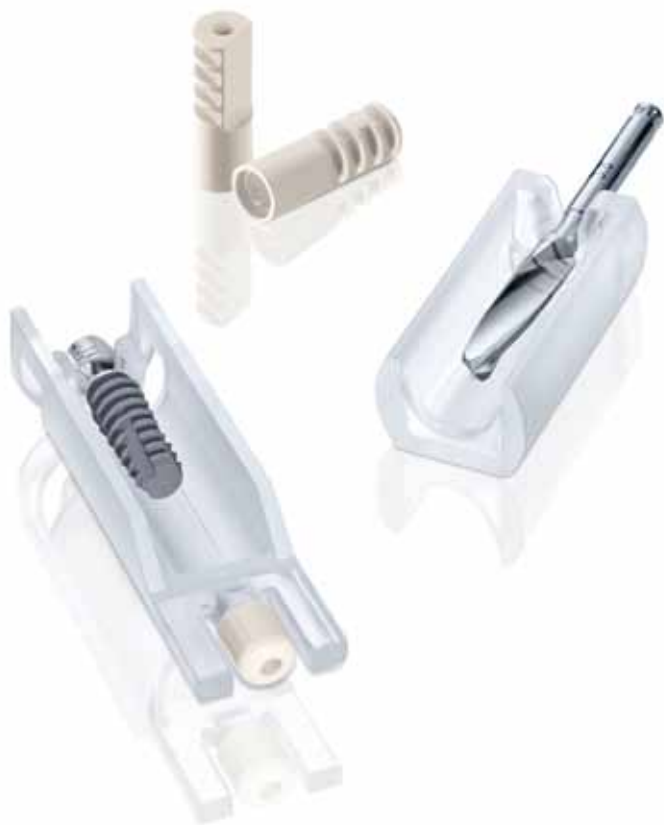

Fig. 1: The single unit iSy implant set comprises: one implant, pre-mounted on the implant base, one healing cap, two multifunction caps and a single-patient form drill.




Fig. 2: The iSy surgical and prosthetic set comprises 19 instruments and can be autoclaved in full.



THE ISY IMPLANT CONCEPT – EFFICIENCY IN DAILY PRACTICE

Dr Jan Klenke, MDT Ralf Kräher-Grube, MDT Jörn Lübbers, all Hamburg

Our patients today are very well informed about the restoration options available with implants. Many want well functioning and esthetically pleasing prosthetics. The expectations and also the financial means of the patient are important decision criteria when selecting treatment concepts with implants. With its high level of standardization and the lean processes, the iSy concept gives us new perspectives for the cost-efficient restoration of partially and fully edentulous patients. The case study describes the time-efficient procedure for a standardized low-risk implantation. The prosthetic restoration was realized with the aid of CAD/CAM technology – a zirconium crown cemented on a DEDICAM titanium abutment.

We employ the iSy implant concept as supplementary system in our dental practice. The implant is designed for standardized, simple methods focusing on functionality, both in terms of the surgical procedure and prosthetic restoration. This allows us to provide patients with limited financial means the

restoration with implants. iSy is supplied in three different implant sets (sets of 1, 2 and 4 units). The packages include the healing caps and multifunction caps as well as the single-patient form drills (**Fig. 1**). Transgingival healing saves time and costs. Based on the very lean and clearly organized component range of

the iSy implant system, the work steps are reduced both in terms of surgery and parts management (**Fig. 2**).

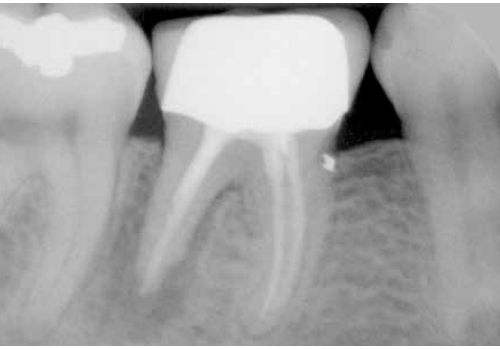

Fig. 3: The x-ray shows a tooth not worth preserving in regio 46.

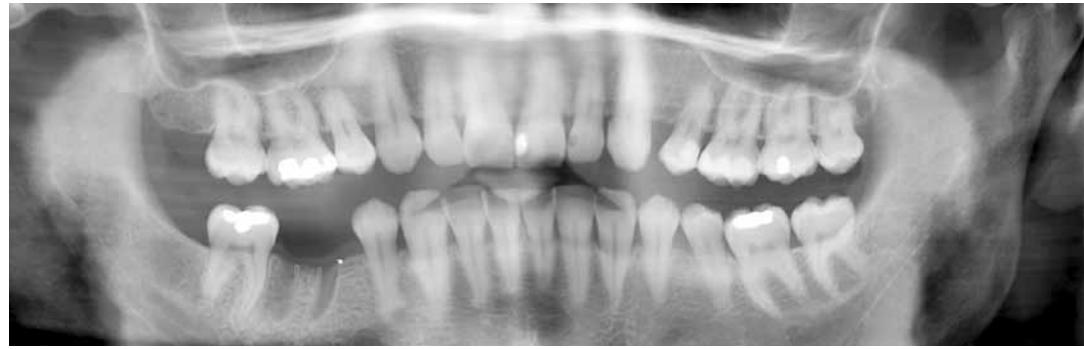

Fig. 4: Two-dimensional presentation of the OPTG structures following extraction of tooth 46.

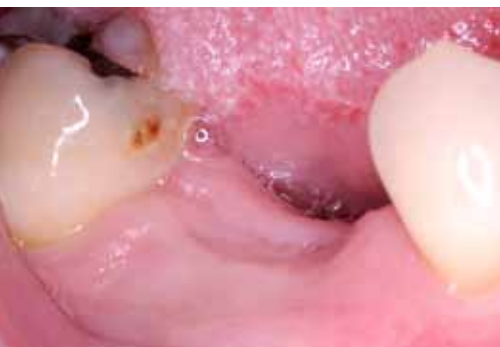

Fig. 5: The alveolar ridge is palpated preoperatively and the thickness of the mucosa measured.

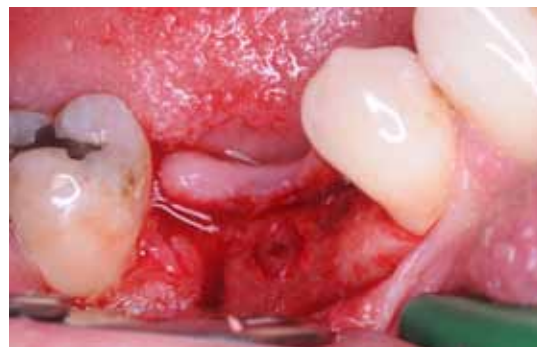

Fig. 6: Preparation of the flap with sufficient attached gingiva in the lingual region.

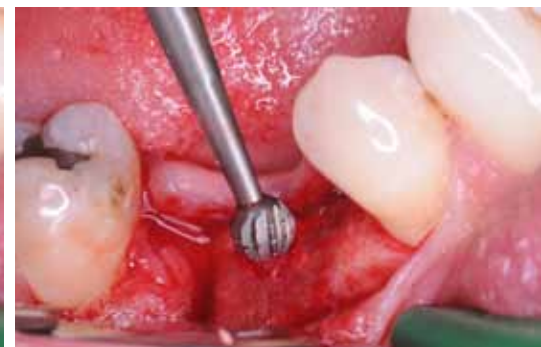

Fig. 7: The iSy round bur \varnothing 3.5 mm is sunk to the equator, this facilitates placement of subsequent drills.

Case description

The patient presented in our dental practice with a tooth in regio 46 that was not worth saving (**Fig. 3**). The first molar in the lower jaw was extracted carefully and the extraction pocket healed over the following three months. During the consultative interview the patient wished for a functional and standardized implant restoration rather than a conventional bridge restoration [1]. A preoperative OPTG and the preparation of planning models were performed initially to make a decision on the implant (**Fig. 4**). The alveolar ridge was palpated in the mouth of the patient, the mucosal thickness measured and the width of the attached gingiva assessed (**Fig. 5**). In order to present the available bone visually, the mucosal thickness measurement was transferred to the model with detachable segments and the alveolar ridge profile marked. The horizontal and vertical bone available was sufficient for implantation without requiring any major augmentative measures. The attached gingiva was also present in sufficient width. These are the prerequisites for transgingival healing [2].

Surgical procedure

Crestal incision was chosen as access, whereby a sufficient zone of attached gingiva remained in the lingual part of the flap (**Fig. 6**). A mucoperiosteal flap was prepared without vertical relief incisions to expose the alveolar ridge. To mark the implant position, the corticalis was punch-marked with the \varnothing 3.5 mm iSy round bur. To facilitate placement of the other drills, the ball is sunk to the equator (**Fig. 7**). Then, using the pilot drill \varnothing 2.8 mm, the depth and axis of the implant bed were determined (**Fig. 8**). The single-patient form drill (\varnothing 4.4 mm) contained in the implant set is removed from the holder directly with the angle piece and the implant bed prepared (**Fig. 9**). Precutting the thread was not necessary with the available bone quality. Following this significantly abbreviated drill protocol to prepare osteotomy, the iSy implant, which is pre-mounted on the implant base, is inserted.

The implant is removed directly from the holder. To this purpose the driver is inserted into the implant base applying slight pressure (**Fig. 10**). The instrument

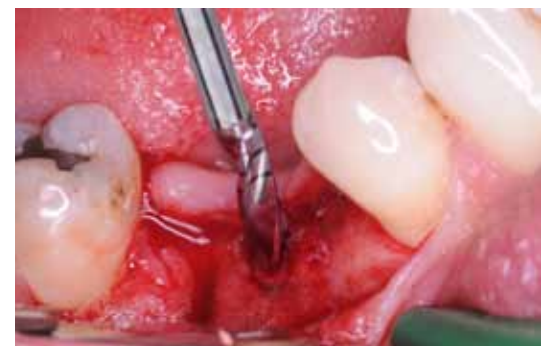

Fig. 8: Depth and axial inclination of the implant bed are determined with the pilot drill \varnothing 2.8 mm.

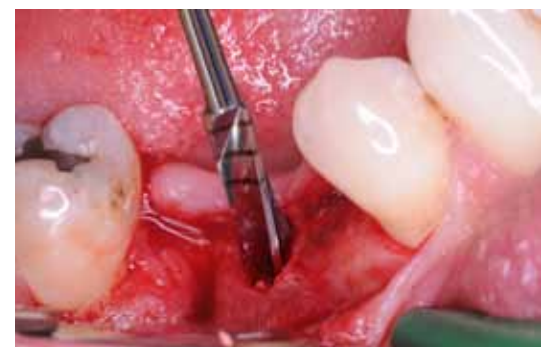

Fig. 9: The single-patient form drill included in the implant set is removed directly with the angle piece and the implant bed is prepared finally direct after pilot drilling.




Fig. 10: The driver is inserted into the implant base applying slight pressure and the implant transferred into the mouth.

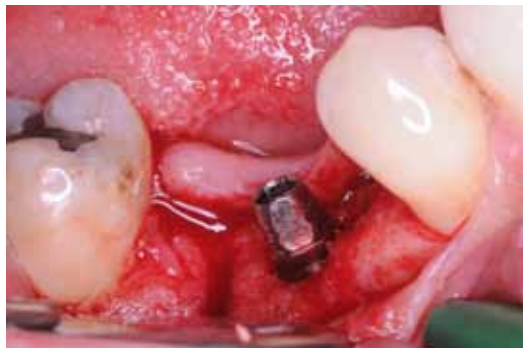

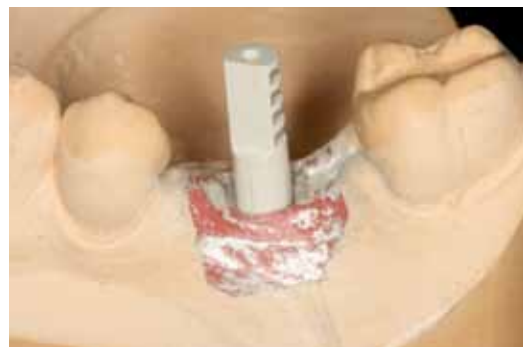Fig. 11: The implant was placed slightly subcrestal, whereby one surface of the implant base is aligned in buccal direction.



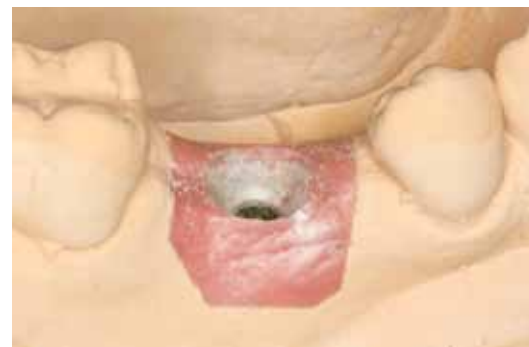Fig. 12: The gingiva former and multifunction caps are mounted on the implant base which stays on the implant until the final restoration is inserted.



Fig. 16: The multifunction cap remains in the impression material and acts as impression cap for the laboratory base with lab analog.



Figs. 17a and 17b: Both the multifunction cap and the gingival situation are scanned.



snaps in noticeably and the implant can be inserted safely into the implant bed. The implant shoulder is placed minimally below bone level and one surface of the implant base is aligned in buccal direction (**Fig. 11**). The surface corresponds to one surface of the inner hex of the implant. The deep placement allows creating an anatomical crown emergence profile (see Fig. 27) [3,4].

The healing cap is mounted on the implant base which stays on the implant until insertion of the final restoration [5]. The single unit implant set includes a healing cap, two multifunction caps and a single-patient form drill. Both the healing cap and the multifunction cap, which serve for impression taking, scanning and design of a temporary prosthesis, are mounted on the implant base (**Fig. 12**).

The flap was repositioned. To obtain tight wound closure, the soft tissue around the healing cap was cut out crescent-shaped and sutured with single button sutures (**Fig. 13**). The implant provided good primary stability, a result of its geometry.

Prosthetic procedure

After a healing time of three months (**Fig. 14**) an impression was taken of the implant. To this purpose only the healing cap was removed and the multifunction cap mounted on the implant base taking the rotation position into consideration (**Fig. 15**). An impression of the entire lower jaw was taken using a pre-assembled tray and polyether impression material. The multifunction cap remains in the impression material and acts as impression cap for the lab base (**Fig. 16**). In the laboratory a lab base was screwed together with the lab analog and placed in the multifunction cap. The dental technician fabricated a removable mucosal mask, prepared the model and articulated it. According to the treatment plan, the implant regio 46 was to be restored with a zirconium crown on a titanium abutment. The dental technician decided to utilize the benefits of a customized CAM-fabricated titanium abutment. With its customized crown emergence profile and placement of the marginal border, CAD/

CAM implant prosthetics are getting closer and closer to “established” teeth. Another aspect which should not be neglected, is the economic factor of CAD/CAM manufacturing. The optimization of the manufacturing processes saves time which can be usefully applied to other tasks. After work preparation measures, the dental technician starts with the necessary scans. To scan the multifunction cap in regio 46, the gingival mask was removed from the model and a sectional scan made of this region. Then the multifunction cap and the laboratory implant base were removed, the gingival mask repositioned and the lower jaw model scanned. For better scanning of the gingival material, this needs to be covered with silver powder. The software matches all the data and then generates a virtual model situation. Using three reference points, the scanbody is assigned from the data base to register the correct implant position and inner geometry.

The dental technician then selected the parameters in the abutment designer of the 3Shape software to design the

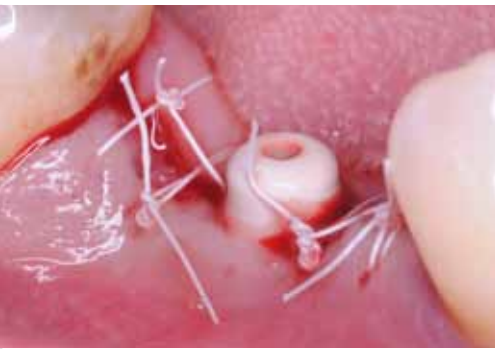

Fig. 13: The soft tissue is sutured tight around the healing cap mounted on the implant base with single button sutures.

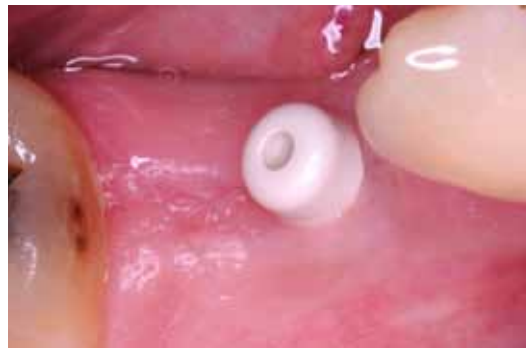

Fig. 14: After three months the iSy implant is osseointegrated and an impression can be taken.

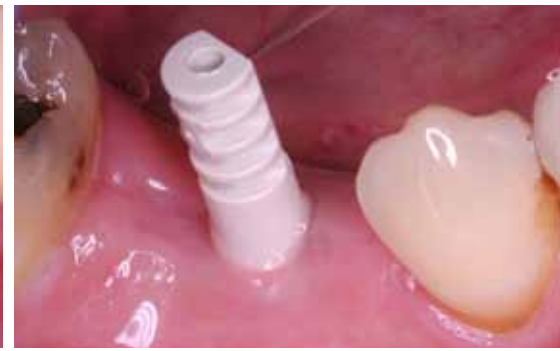

Fig. 15: The healing cap is removed and the multifunction cap mounted on the implant base for impression taking of the implant.

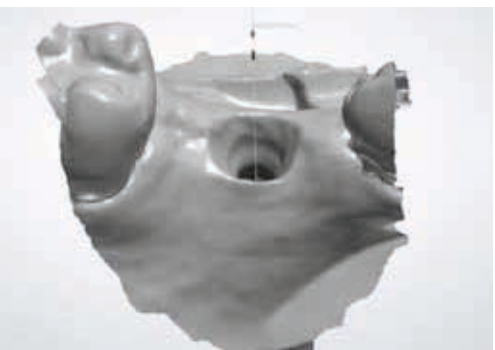


Fig. 18: Scan of the soft tissue situation and the implant shoulder.



Fig. 19: Design of the titanium abutment with impression of the subgingival region and isogingival placement of the cement gap.

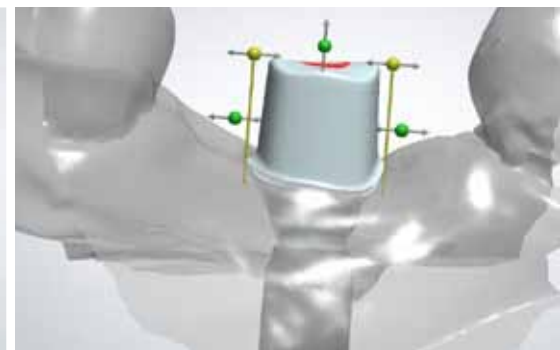


Fig. 20: Perfect placement of the abutment in the dental arch. Only slight angulation was necessary.

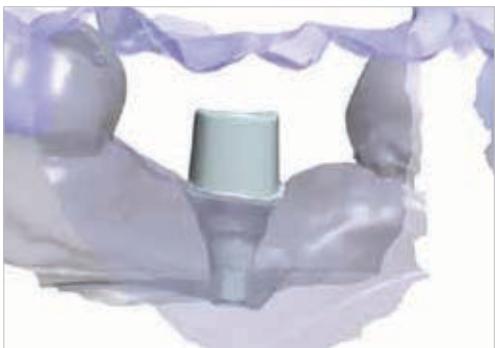

Fig. 21: Check of space conditions in all directions with superimposed opposite bite.



Fig. 22: The milling cylinder is superimposed and the positioning of the abutment checked.



Fig. 23: The virtually designed abutment.

abutment. To integrate the restoration into the dental arch in a harmonious manner, he only changed the axial alignment of abutment slightly. The suggestion of a single component titanium abutment was called up. The crown emergence was marked and the subgingival section shaped virtually. By dragging the reference points, the marginal region can be customized such that it blends in with the gingival profile (**Figs. 17 to 20**). We position the abutment/crown transition isogingival in the invisible area. This

procedure ensures that the sulcus remains free of cement debris when cementing the crown [6]. The abutment was modified digitally and the dimensions checked in all directions (**Figs. 21 to 23**) [7,8]. The open STL file was uploaded via the Dental Manager and the single component DEDICAM titanium abutment was milled in the milling center. After the highly polished titanium abutment arrived in the laboratory two days later, it was screwed into the lab analog and the occlusal and interdental gap to the adjacent teeth was

checked. As a next step, the abutment was scanned, a zirconium framework was designed and machine-made with the aid of the DEDICAM milling service. In the laboratory the framework was veneered with a special zirconium ceramic (**Figs. 24 to 29**).

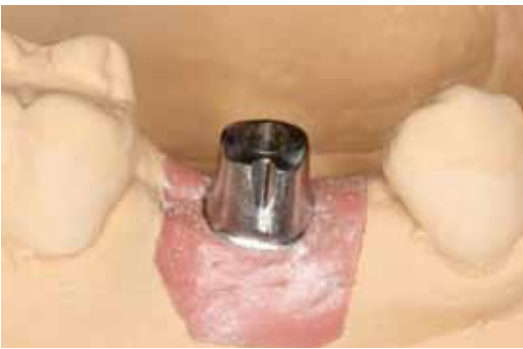

Fig. 24: The DEDICAM titanium abutment is scanned for fabrication of a zirconium crown framework.

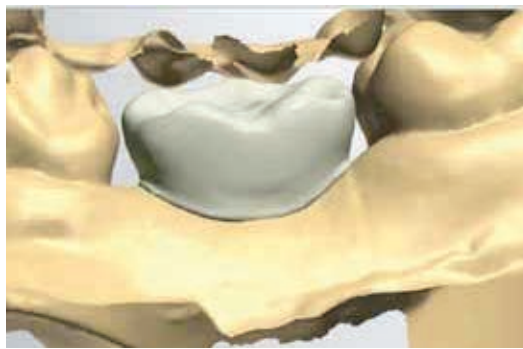


Fig. 25: The anatomical crown framework is designed virtually.



Fig. 26: The basal support area of the crown on the soft tissue is elaborated especially.

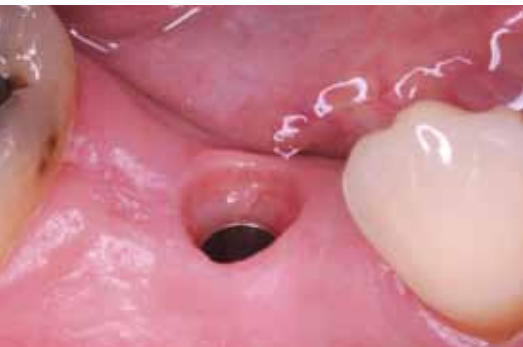

Fig. 30: A stable, irritation-free gingiva sleeve is given at the time of the final insertion.

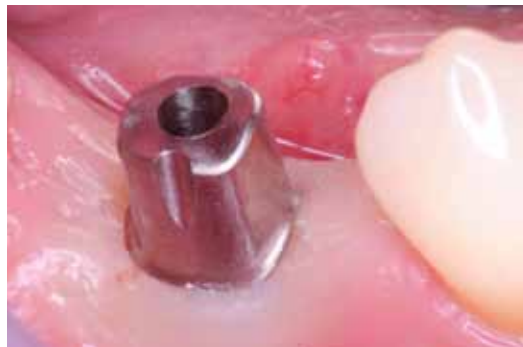

Fig. 31: When placing the DEDICAM titanium abutment the gingiva is displaced slightly due to the customized emergence profile. The abutment screw is tightened with 20 Ncm.

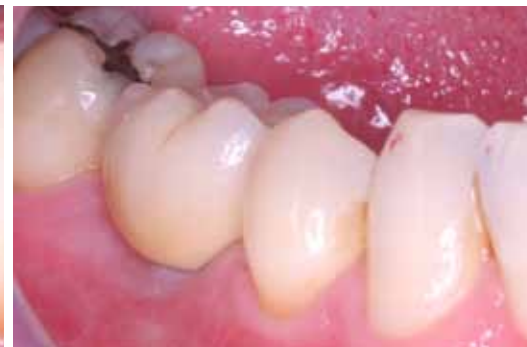

Fig. 32: The zirconium crown is cemented onto the abutment. Due to the isogingival position of the crown/abutment transition, excess cement is easy to remove.

The implant base was removed from the implant for the first time for insertion of the restoration in the dental practice. The soft tissue was absolutely stable and irritation-free (**Fig. 30**). The DEDICAM titanium abutment was inserted, the abutment screw tightened with 20 Ncm and the zirconium crown was cemented. After checking occlusion, the patient left our dental practice with a high quality, functional and less expensive prosthetic (**Fig. 31 to 34**).

CONCLUSION:

The standardized, extremely time-efficient iSy concept has been established in our practice for several months now and is well received by patients. Transgingival healing and the simple "unspectacular" surgery with only three drilling sequences saves time and money. For this reason we can offer patients with a limited budget restorations with implants. The diverse use of the implant base is a major improvement and time-saver. The healing cap and

the multifunction cap are mounted quickly and safely. No change of abutment is necessary right through to the final restoration when using an iSy implant for restoration. The implant interface is sealed saliva-proof from the point of surgery onwards, which means no cleaning of blood remains is required.

Using CAD/CAM prosthetics, the workflows are also standardized and time-efficient in the laboratory after a certain learning curve. The CAM processes allow restorations with different materials which would not be possible with analog methods. The use of biocompatible materials in the fabrication of an anatomically shaped crown emergence profile is of clinical advantage. The peri-implant structures are supported and the restoration has a good long-term prognosis.

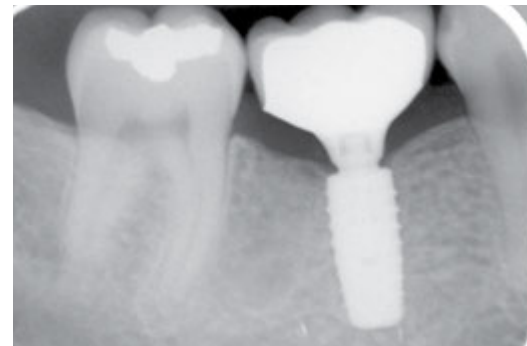

Fig. 33: The x-ray control image shows the epicrestal placement of the implant shoulder and the anatomically created crown emergence profile.

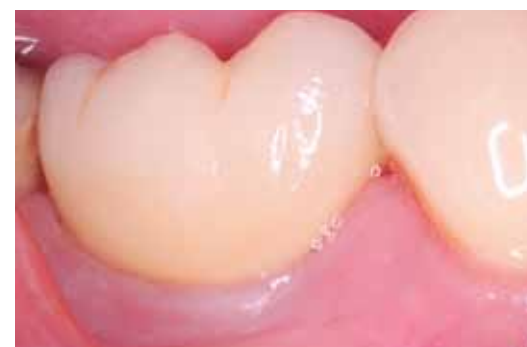

Fig. 34: Three months after insertion of the zirconium crown the soft tissue sleeve is stable.

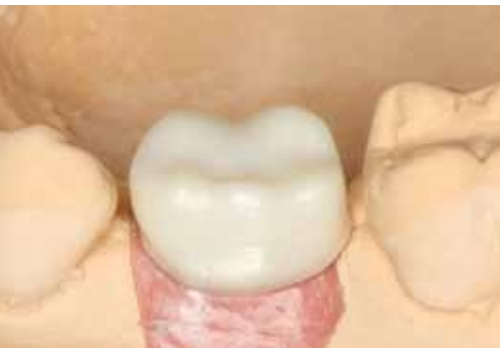

Fig. 27: The framework is milled from the zirconium block and prepared for veneering.

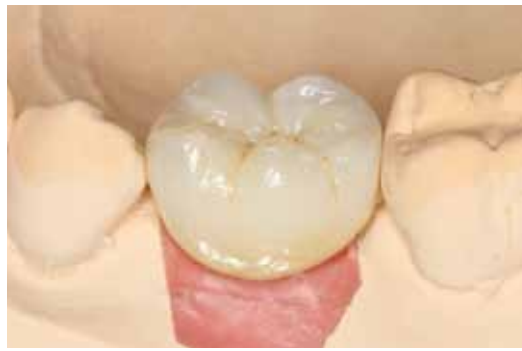

Fig. 28: The veneered zirconium crown on the model completes the row of teeth.



Fig. 29: The highly polished subgingival section of the titanium abutment and the anatomical zirconium crown profile form a harmonious transition.

LITERATURE

- [1] Ackermann KL, Kirsch A., Nagel R., Neuendorff G. Mit Backward Planning zielsicher therapieren. Part 1 Teamwork 2008;4:466-484
- [2] Cordaro L, Torsello F, Chen S, Ganeles J, Brägger U, Hämerle C. Implant-supported single tooth restoration in the aesthetic zone: transmucosal and submerged healing provide similar outcome when simultaneous bone augmentation is needed. Clin Oral Implants Res. 2013 Oct;24(10):1130-6.
- [3] Kutkut A, Abu-Hammad O, Mitchell R. Esthetic Considerations for Reconstructing Implant Emergence Profile Using Titanium and Zirconia Custom Implant Abutments: Fifty Case Series Report. J Oral Implantol. 2013 Oct 31. [Epub ahead of print]
- [4] Linkevicius T, Vindasiute E, Puisys A, Linkeviciene L, Maslova N, Puriene A. The influence of the cementation margin position on the amount of undetected cement. A prospective clinical study. Clin oral Implants Res. 2013;24(1):71-6
- [5] Schwarz F, Alcoforado G, Nelson K, Schaer A, Taylor T, Beuer F, Strietzel FP. Impact of implant-abutment connection, positioning of the machined collar/microgap, and platform switching on crestal bone level changes. Camlog Foundation Consensus Report. Clin Oral Impl. Res. 0, 2013, 1-3 doi:10.1111/crl.12269
- [6] Enkling N, Jöhren P, Klimberg T, Mericske-Stern R, Jervøe-Storm PM, Bayer S, Gülden N, Jepsen S. Open or submerged healing of implants with platform switching: a randomized, controlled clinical trial. J Clin Periodontol. 2011 Apr;38(4):374-84.
- [7] Schweiger J., Beuer F., Stimmelmayer M., Edelhoff D. Paths to the implant abutment. dental dialogue 2010; 11:76-90.
- [8] Beuer F, Schweiger J, Guth JF, Edelhoff D. CAD / CAM-Lösung nach Verlust eines Doppelkronenpfählers. ZM 2012;102(22a):42-46

Contact information

Joint practice

Dr Jan Klenke & Christian Regel

Große Bleichen 32
20354 Hamburg

Phone: +49 40 344499

E-Mail: dr.klenke@t-online.de

Zahntechnik GmbH

MDT Jörn Lübbers

Große Bleichen 32
20354 Hamburg

Cuspidus Zahntechnik GmbH

DMT Ralf Kräher-Grube

Sternstraße 105
20357 Hamburg

AUTHORS



Dr Jan Klenke

Dr Jan Klenke completed his studies of dentistry in 1993 at the Free University Berlin and received his state examination. From 1993 to 1996 he worked as research assistant in the Department for Tooth Preservation and Periodontology. After two years in free practice he took over a dental practice in Hamburg which he is managing jointly with Christian Regel since 2001. In 2005 he obtained his focus on implant dentistry from the BDIZ and completed a 2-year postgraduate study course on "Conscious sedation and pain management" at the Eastman Dental College in London. Since 2013 he is a certified expert for implantology of the DGOI and is a member of the associations DGZMK, DGP, DGZI, BDIZ, DGOI.



MDT Ralf Kräher-Grube

Ralf Kräher-Grube worked as dental technician in Hamburg after completing his apprenticeship diploma in 1977. In 1982 he obtained his Master Certificate in Hamburg and worked in the laboratory of a dental practice until establishing Ralf Kräher Zahntechnik GmbH in 1986. In 1999 the company was renamed "CUSPIDUS Zahntechnik GmbH" which he runs together with his equal partner MDT Stephan Marzok. In 2003 he started with CAD/CAM work processes. When the company relocated to St. Pauli in 2006, he focused on 3D planning, navigated implant dentistry and esthetic anterior tooth reconstruction. He is active as speaker and author in the field of navigated implant dentistry and digital construction of customized abutments and superstructures. He is a member of the ITI, DGI, DGZMK, FDZt Peers, FhZ, ZIHS and VDZI.



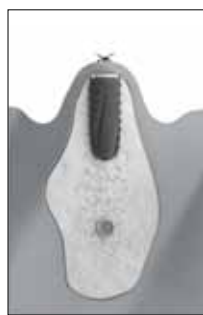MDT Jörn Lübbers

Jörn Lübbers received his apprenticeship diploma in 1988 from the Dental Technicians Guild Schleswig Holstein and obtained his Master Certificate in 1993 in Munich. Since 2006 he has been managing his own laboratory in Hamburg in close cooperation with a small group of excellent dentists. He attends numerous national and international further education events and is inspired by new techniques and materials. He incorporates much of this into optimized workflows in his daily routines at the laboratory and the treatment procedures for patient care.



Transgingival healing

Subgingival healing



NEW: THE ISY COVER CAP – DEEP RELAXATION!

The iSy implant system is designed for transgingival healing and ensures time-efficient and cost-effective treatments. At the end of January 2014 the component range was extended by the iSy sealing cap. This gives the user the intra-operative option of deciding on closed healing if required.

The iSy sealing cap is made of PEEK (plastic) and is inserted into the implant with the handpiece for the healing cap. It fits all three implant diameters. For closed healing, the implant is inserted in accordance with the protocol and the implant base is removed. Using the screwdriver, the abutment screw is loosened and the implant base is removed with the conical disconnecter. The iSy sealing cap is then

fitted and the soft tissue is sutured close. After exposure, an implant base is inserted and the user then proceeds in accordance with the iSy protocol.

The instrument range will be expanded by a short handpiece for the healing cap. The iSy healing cap and iSy multifunction caps are now packaged in separate sets of three. The implant base is also available individual sterile packed with a screw and a healing cap.

The iSy concept provides experienced users the option of broadening their base for implant dentistry. iSy concentrates on the essentials, which means lower costs despite tougher demands. Many users have waited a long time for an inexpensive

alternative from a reliable partner and use iSy as a second or third system.

Modern production technologies and consistent quality management ensure that the iSy implant system meets high demands. Relying on the implant expertise of CAMLOG means that you can implant iSy completely stress free.



THE MARKET TREND FOR "DIGITAL DENTISTRY" IS GAINING CONSIDERABLE MOMENTUM

The advent of modern digital technologies in the dental reconstruction process has led to a multiplicity of emotions. This ranges from excitement to rejection. Next to the euphoria in the CAD/CAM sector, a part of "digital dentistry", there are also concerns. Today, the CAD/CAM-fabricated reconstructions demonstrate high precision, material quality and diversity. It is a fact that the development trend in dental technology is unstoppable over the next few years, be it in terms of digitalization or materials. In order to remain competitive, owners of dental laboratories in particular will need to take decisions and ask themselves a number of questions. Priority will be the economic and personnel development in the laboratory and defining their future needs. This will unearth the optimization potential of some processes in the daily laboratory routines which can be improved by the integration of CAD/CAM technologies. The following article focuses on options for mastering the daily laboratory routines with the DEDICAM milling services.

The CAD/CAM field of "digital dentistry" covers a broad spectrum and offers numerous different options. The decision on how extensive CAD/CAM technology should be integrated in the laboratory should be subject to business and strategic aspects exclusively. A look at the development of dental technology,

today's status and where it might be in the future, can prove to be a useful decision-making tool. The much acclaimed digital workflow is involved in more and more individual work steps and offers technical and commercial options which, if applied properly, lead to improved results and optimized business perspectives. Although some interfaces for data transfer still need to be designed to provide an effective seamless process, the trend toward digitally designed implant and perio-prosthetics continues. According to industry opinion this will even accelerate over the next few years with the increasing use of intraoral scanners, DVT and 3D planning.

However, the machines for fabricating the semi-finished products with CAM methods are subject to continuous change with respect to new materials and their processing. Today, the milling and grinding of known materials such as titanium, zirconium oxide, plastics or NEM alloys is the applicable standard. High performance polymers can be machine-manufactured through pressure or other additive processes. It is the combination of these technologies which offers particularly interesting approaches. Investment in a CAD system can therefore be regarded as sustainable. Setting up one's own CAM fabrication is to be seen somewhat more critical in view of the technological changes.

The business criteria in terms of value creation are highly complex. Your business consultant will be able to inform you about the basic principles of cost-efficiency and investment regarding in-house CAM manufacturing, based on facts and without emotions. Prior to investment one needs to obtain a comprehensive quotation from the market, whereby one should consider the precision of reconstruction and the quality of machine manufacturing as well as handling a variety of different materials. Not every business is today ready or able to make large investments into the infrastructure for digital dentistry. As the numerous materials are machined for a broad spectrum of restoration options with different manufacturing technologies it is of advantage to outsource CAM production. The outsourcing of production steps frees capacities which can be used for other activities in the laboratory.



"DIGITAL DENTISTRY"