


This is



**Fig. 1:** The iSy Implant system with transgingival application. Both the gingiva former and the multifunctional cap (for impression taking and temporary restoration) are attached to the implant base.



## CHAIRSIDE OR LABORATORY – OPTIONS OF TEMPORARY RESTORATIONS WITH THE ISY IMPLANT

Dr. Jan Klenke, Hamburg

Conceived as a transgingival healing, reduced implant system, iSy was launched on the market three years ago to enable patients with limited financial means to have restorations with implants. In standard indications, transgingival healing reduces the surgical effort required and prosthetic follow-up is easy to implement. The option of submerged healing also exists if required. The following article describes the different temporary restoration options of the iSy Implant system with the components included in the set.

In our dental practice we employ iSy by CAMLOG as a transgingival healing implant system in line with the original idea. This concept has been established for many years and is well documented [1]. We regard a bone bed which requires no or only little augmentation as a precondition for transgingival healing [2]. Stable, sufficiently thick soft tissue in the region of the planned insertion site is at least equally important.

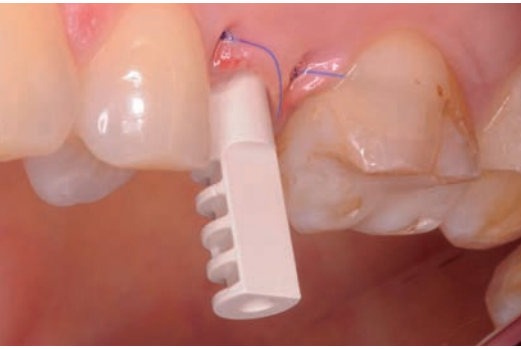
The surface of the iSy Implants is identical to the blasted and etched Promote® Surface of the CAMLOG® and CONELOG® Implants. In retrospective studies this has demonstrated a success rate [3]. A first iSy study from October 2015 showed excellent 1-year results following prosthetic restoration [4].

The iSy Implant is inserted in the jaw bone with the aid of the pre-mounted implant base on the implant. Following the concept, a PEEK gingiva former is generally mounted on the implant base for the period of healing (**Fig. 1**).

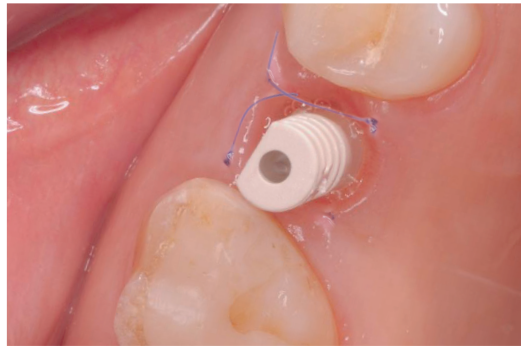
Transgingival healing not only saves the patient a second surgical procedure with associated costs, but allows immediate temporary restoration with the iSy implant. The multifunctional caps, which are also mounted on the implant base, act as framework for the temporary restoration (**Fig. 2**). These temporary restorations can be fabricated cost-effectively “chairside” with little time expenditure. In many cases, elaborate permanent or removable laboratory-fabricated temporary restorations are no longer necessary. Various fabrication

options are possible for fabricating the temporary restorations.

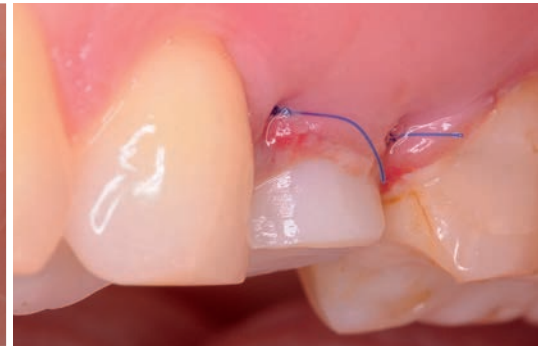Common to all options, is first shortening the multifunctional cap by grinding, so that there is sufficient space for the shape of the temporary restoration (**Fig. 3**). The chemical bond between the plastic of the temporary restoration and the PEEK multifunctional cap proved to be a problem for a longer period. A study by Starwarczyk et al [5] shows that only the following three adhesives are able to create a bond between PEEK and plastic: visio.link by Bredent, Signum PEEK by Heraeus Kulzer (test phase) and Monobond plus by Ivoclar Vivadent. After trimming the multifunctional cap, this needs to be conditioned with one of the above mentioned adhesives. Three of the many possible options



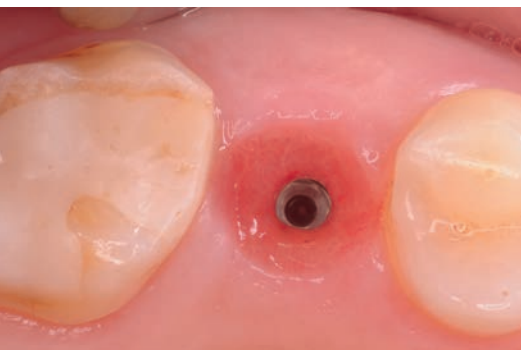**Fig. 2:** The multifunctional cap is placed on the implant base to prepare a chairside temporary restoration.



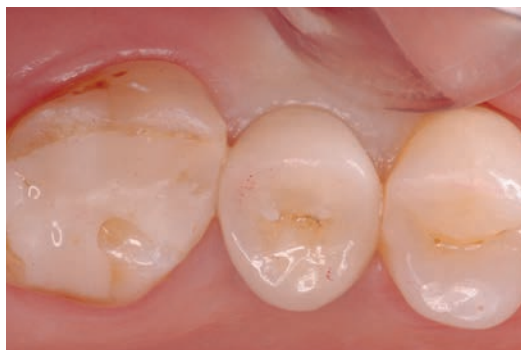**Fig. 3:** The occlusal view shows the exact positioning of the implant in the row of teeth.



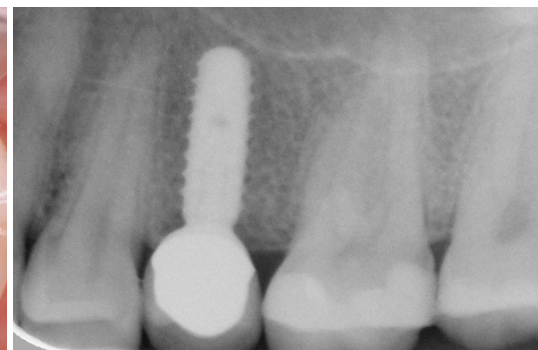**Fig. 4:** The immediate restoration is snapped onto the implant base immediately after insertion of the iSy Implant in regio 25.



**Fig. 5:** Emergence profile shaped by the immediate temporary restoration.



**Fig. 6:** The final crown is placed on a customized abutment.



**Fig. 7:** The x-ray checkup after placement of the final restoration shows a stable bone bed.

for immediate temporary restorations with iSy Implants are presented in this article.

### First option for fabricating a temporary restoration

The first variant for fabricating a chairside temporary restoration is similar to the procedure for temporary restorations for a crown restoration following preparation of the tooth. To this purpose, a pre-impresion of the tooth to be prepared and the adjacent teeth is taken prior to preparation of the tooth. As this impresion may need to be used several times and needs to be stable under storage, we use a silicone material for this impresion. Such a pre-impresion is taken for the temporary restoration with an iSy Implant prior to extraction of the tooth to be replaced or via a possibly removable temporary restoration, in as far as the tooth has already been extracted. After implantation and suturing, a multifunctional cap is prepared, conditioned and mounted on the implant base in the mouth.

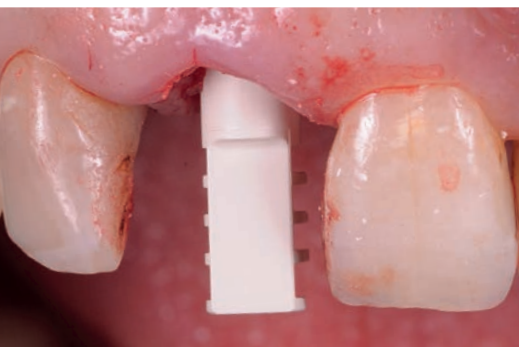The next step in creating a temporary restoration again corresponds to the proce-

dure of creating a temporary crown on a natural tooth. A self-hardening plastic for creating temporary restorations is applied into the pre-impresion and repositioned in the mouth. After the prescribed curing time of the temporary plastic, the impresion is taken from the mouth. The temporary plastic has now bonded mechanically with the PEEK of the multifunctional cap through the undercuts and chemically through conditioning. The original shape of the tooth has now been restored via the PEEK multifunctional cap. The temporary restoration is now removed from the implant base and finished extraorally. Attention should be paid to remove all occlusal and functional contacts here. After completion, the temporary restoration is snapped onto the implant base (**Fig. 4**). In our dental practice we refrain from cementing the temporary restoration. The first reason being that overlooked cement residue always represents a risk for osseointegration of the implants, the second reason being that the multifunctional cap is held sufficiently on the implant base to provide safe retention of the temporary restoration. With the aid of the tempo-

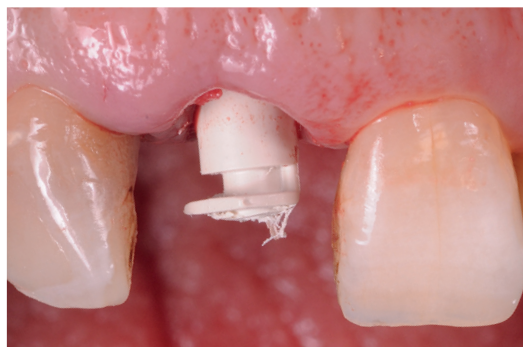rary restoration, an anatomical emergence profile can be shaped at the same time (**Fig. 5**). After the healing period, both the temporary restoration and the implant base are removed and a customized abutment and the final crown are placed (**Figs. 6 and 7**).

### Second option for fabricating a temporary restoration

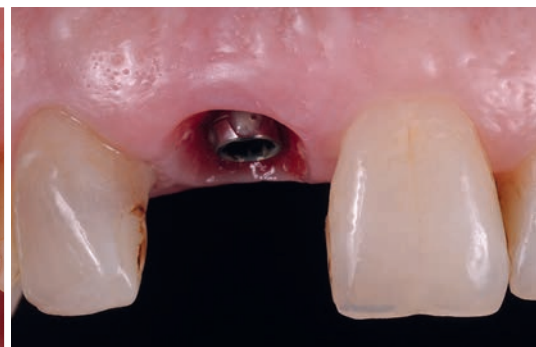A further option for preparing an immediate restoration on iSy implants is the use of pre-fabricated temporary shell restorations. In this case the multifunctional cap is trimmed after implantation such that a temporary shell restoration can be placed in the correct position over the multifunctional cap. Then the multifunctional cap is conditioned with one of the above mentioned adhesives. Now the temporary shell restoration is filled with just enough flow composite to connect the multifunctional cap with the temporary shell restoration. After light-curing of the composite, the bonded multifunctional cap and temporary shell restoration are removed from the implant base and the desired emergence



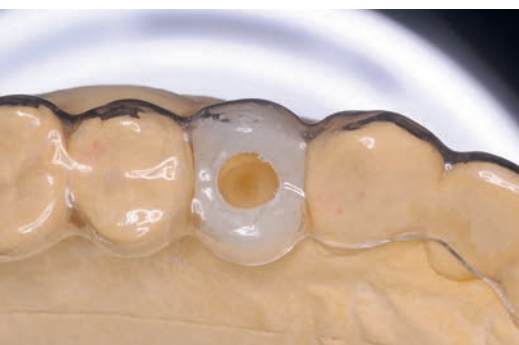**Fig. 8:** Multifunctional cap mounted on the implant base.



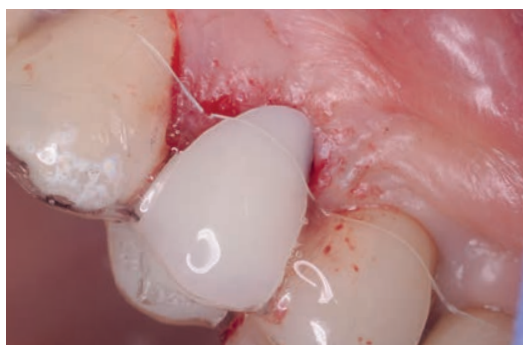**Fig. 9:** To fabricate a chairside temporary restoration, the same multifunctional cap is trimmed so that it fits underneath the temporary shell restoration.



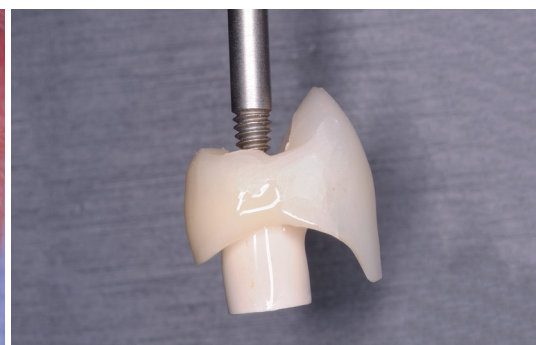**Fig. 10:** A stable soft tissue collar surrounds the iSy Implant and the pre-mounted implant base.



**Fig. 14:** Both the splint and the plastic tooth were trepanned to prepare the orientation template for insertion.



**Fig. 15:** Deep-drawn splint inserted in the mouth with basally ground plastic tooth.



**Fig. 16:** The temporary shell restoration is connected to the multifunctional cap in the mouth using flow composite.

profile is designed extraorally with composite (**Figs. 8 to 12**). To facilitate removing and inserting the temporary restoration, trepanation can be provided occlusally through the temporary shell restoration to the opening in the multifunctional cap. The intended instrument can now be screwed into this opening and allows insertion and removal of the temporary restoration (**see Figs. 14 and 15**).

### Third option for fabricating a temporary restoration

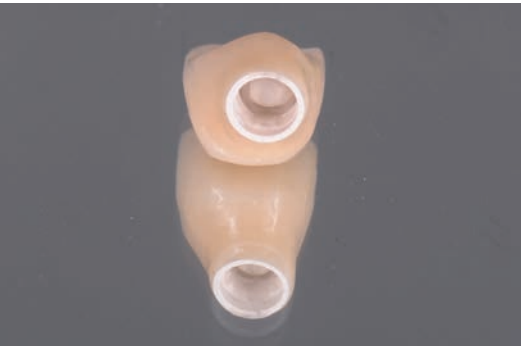The third variant for temporary restorations combines the use of a simple orientation template with the preparation of an immediate temporary restoration. In this case a deep-drawn splint is fabricated on a model for the template. Prior to deep-drawing the foil, a plastic tooth is placed in the position of the missing and to be implanted tooth (**Fig. 13**). Initially this tooth simulates the later prosthetic restoration. Based on this set-up, the implant position is planned (backward planning) and marked on the model. After deep-drawing of the foil, the

tooth is held by the deep-drawn splint. This is followed by drilling through the splint and the set up plastic tooth (**Fig. 14**). Then the splint with the tooth is removed from the model and tooth and splint are separated. The plastic tooth is ground basally and the shell is then replaced in the splint. The orientation template is inserted intra-operatively and pilot drilling with a diameter of 2.8 mm is performed through the opening in the template. The splint is removed for form drilling and the implant is then inserted. The further procedure corresponds to the above mentioned procedure for connecting a temporary shell restoration to the multifunctional cap. The difference being that the plastic tooth is inserted with the splint and thus brought precisely to the position previously planned on the model (**Fig. 15**). After curing the first portion of flow composite, the splint is removed from the mouth and then the multifunctional cap with the attached plastic tooth. After shaping the desired emergence profile with composite, the temporary restoration is mounted on the implant base (**Figs. 16 to 18**).

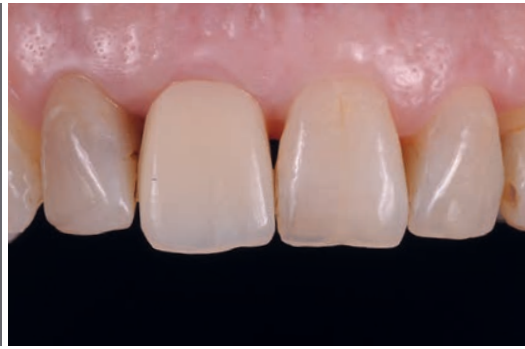An occlusal check is to be observed in general for all temporary restorations. Here, all occlusal and articulation contacts which could lead to loading must be removed (**Fig. 19**). The patients are given dietary recommendations and strict instructions not to load the temporary restored implant during the first 6 weeks.

### Conclusion

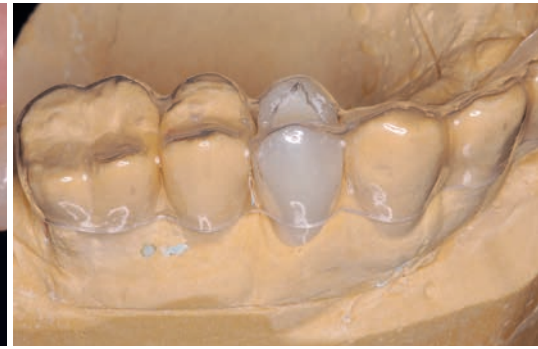Transgingival healing with a temporary immediate restoration offers enormous advantages in certain indications, as a number of studies have meanwhile confirmed. The pre-mounted iSy Implant base remains on the implant after insertion and acts as support framework for the gingiva former and the temporary restoration. The idea behind the iSy concept not only shortens the clinician's "chairside" time, but also reduces surgical effort and thus the costs for the restoration with implant-supported tooth replacement. Many patients with a limited budget can therefore gain simple and cost-reduced access to implant-supported prosthetics.



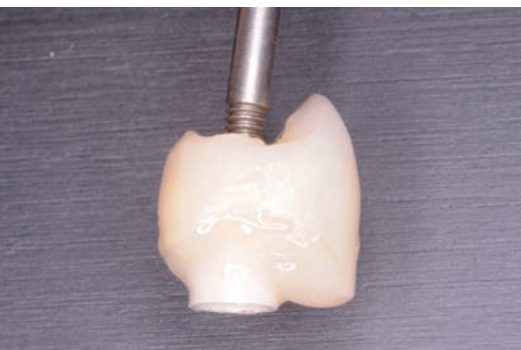**Fig. 11:** Viewed from basal, the anatomical shaping and the connection of the multifunctional cap and the temporary shell restoration with composite.



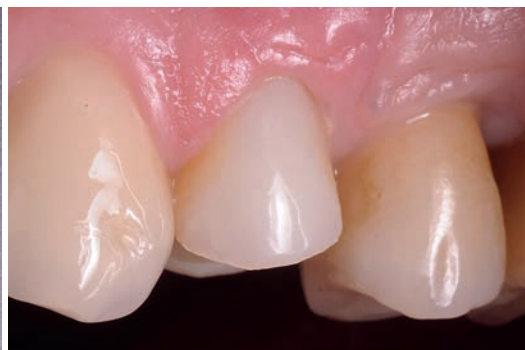**Fig. 12:** The finished and polished long-term temporary restoration was mounted on the iSy Implant base.



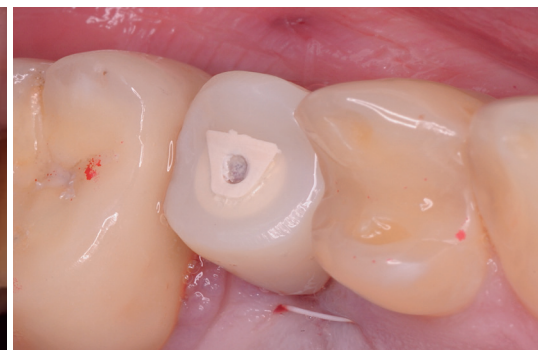**Fig. 13:** Plastic tooth set up on a model covered by deep-drawn plastic splint.



**Fig. 17:** The long-term temporary restoration was completed extraorally and the emergence profile created.



**Fig. 18:** Healed region 24 with mounted temporary restoration after 6 weeks.



**Fig. 19:** Occlusal view of a temporary restoration on an iSy Implant regio 25, contact points only exist on the adjacent teeth.

## LITERATURE

[1] Esposito M, Grusovin MG, Coulthard P, Worthington HV: Interventions for replacing missing teeth: 1- versus 2-stage implant placement, The Cochran Library, 2007, Issue 3.

[2] Cordaro L, Torsello F, Chen S, Ganeles J, Brägger U, Hämmerle C, Implant-supported single tooth restoration in the aesthetic zone: transmucosal and submerged healing provide similar outcome when simultaneous bone augmentation is needed. *Clin Oral Implants Res.* 2012 Oct; 24(10):1130-6.

[3] Franchini, I., Capelle, M., Fumagalli, L. Parenti, A. Testori, T., Multicenter retrospective analysis of 201 consecutively placed camlog dental implants. *Int j of perodontics Testorative Dent* 2011; 31(3):255-63.

[4] Ulrici St., Barth, Th., Klenke J., Wolf M.: Retrospektive Analyse von Patientenfällen mit iSy Implantaten in drei Privatpraxen: Ein-Jahres Daten, ZZI 2015.

[5] Stawarczyk B., Keul Ch., Beuer F., Roos M., Schmidlin P.: Tensile bond strength of veneering resins to PEEK: Impact of different adhesives, *Dental Materials Journal* 2013; 32(3):441-448.

## AUTHOR



### Contact details

**Joint practice**  
**Dr Jan Klenke & Christian Regel**

Große Bleichen 32  
20354 Hamburg

Phone.: +49 40 344499

Email: dr.klenke@t-online.de

### Dr Jan Klenke

Dr Jan Klenke completed his studies of dentistry in 1993 at the Free University Berlin and received his state examination. From 1993 to 1996 he worked as research assistant in the Department for Tooth Preservation and Periodontology. After two years in free practice he took over a dental practice in Hamburg in 1997 which he is managing jointly with Christian Regel since 2001. In 2005 he obtained his focus on implant dentistry from the BDIZ and completed a 2-year postgraduate study course on "Conscious sedation and pain management" at the Eastman Dental College in London. Since 2013 he is a certified expert for implantology of the DGOI and is a member of the associations DGZMK, DGP, DGZI, BDIZ, DGOI.