

Special Edition

logo

ISSUE 3 | 2012
CAMLOG Partner-Magazine



**4TH INTERNATIONAL
CAMLOG CONGRESS –
A REVIEW**



4TH INTERNATIONAL CAMLOG CONGRESS

The starting shot for congress activities was made on Thursday, May 3rd, a day before the actual 4th International CAMLOG Congress, with four German/English workshops, that were fully booked well in advance. These theoretical and practical events on the complex aspects of soft-tissue management were held at 2,100 meters above sea level on Mount Pilatus.

In addition to cutting-edge, first-hand scientific information from authoritative sources, the congress also offered a lot of practical information. As the concluding participant survey showed, the connection between the *scientific* content of the first morning of the congress and the *practical* topics of Friday afternoon and Saturday was viewed as particularly successful and highly informative.

Platform switching and implant/abutment connections

Ten-year results of CAMLOG® implants with Tube-in-Tube™ connection are definitively convincing with survival rates

of up to 98%. Nevertheless, the proven CAMLOG® system is being continuously developed including the new conical connection of the CONELOG® implants. Platform switching is possible with both implant systems and the horizontal displacement of the connection gap could be more important for tissue stability than the connection type.

Interim results of a study on bone level around CAMLOG® SCREW-LINE Promote plus implants with and without platform switching were presented by Prof Fernando Guerra (*University of Coimbra, Portugal*) and Prof Wilfried Wagner (*University of Mainz, Germany*). To that point, 70 patients were randomized

and reexamined over two years. There were significant differences statistically between the two groups with an average increase in bone level of 0.1 mm (distal) and 0.2 mm (mesial) around implants with platform switching. In contrast, moderate bone loss of 0.3 mm (mesial) and 0.2 mm (distal) was observed with flush implants. For a sound assessment, the results must be awaited for up to five years.

However, very good, long-term stable results can be obtained with flush abutments, too. Prof Wilfried Wagner and Prof Hendrik Terheyden presented outstanding ten-year survival and success rates from the university centers of Mainz (98.2% for CAMLOG® SCREW-LINE) and Kiel (96.2% for



CAMLOG® CYLINDER-LINE), which were achieved with even high-risk patients. Irrespective thereof, many speakers showed clinical examples of long-term tissue stability with traditional CAMLOG® implants also in terms of radiological bone level.

Soft-tissue thickness and practice

The clinical relevance of thick soft tissue around implants was confirmed by **Prof Giulio Rasperini** (*University of Milan, Italy*). While periodontists prefer thin tissue in the treatment of natural teeth, a thick layer of tissue around implants is always the aim. To maintain a broader keratinized gingiva, the apical sliding flap has proven most effective.

How important the topic of soft-tissue quality and emergence profile is for the daily practice was also demonstrated by established periodontist **Dr Paul Sipos** (*Amstelveen, Netherlands*). Based on impressive photos of erupting permanent teeth, he showed the vitality and esthetics of thick, well-perfused

tissue. The periodontal gingival height of only about one millimeter on average is usually not sufficient around implants and in many cases, would have to be increased. The aim must also be to maintain the supracrestal fiber structure to the extent possible.


Precision and biomechanics

Prof Jürgen Becker and various speakers in Lucerne referred to the simple, precision application of CONELOG® implants. In contrast to other systems, the conical abutment can be safely and easily removed from the implant and easily removed from the implant using the special disconnecter. As a further advantage of the CAMLOG® and CONELOG® Implant Systems, oral and maxillofacial surgeon **Prof Katja Nelson** (*University of Freiburg, Germany*) named the minimum fabrication tolerance of implant/abutment connections. This is of particular importance for the accurate transfer of implant positions in the laboratory and ultimately, the long-term success of the implant-retained restoration.

According to new studies conducted by K. Nelson's working group, the rotational deviation for both CAMLOG® Tube-in-Tube™ and CONELOG® implants is particularly low with 1.5 and 2.1 degrees respectively compared with important competitor systems. For CAMLOG® Tube-in-Tube™ implants, the vertical deviation significant for the occlusion was under 10 microns and thus in some cases, much less than those of well-known competitors.

Documentation is essential

Prof Thomas Taylor (*University of Connecticut, USA*) emphasized the value of a well-documented implant system. Based on scanning electron microscopic images, he demonstrated that macroscopically identical implants differ significantly qualitatively. This also applies to the precision of the implant/abutment connection. "Copied implants may work or may not work." According to Taylor, credible manufacturers must invest in research and carefully document their products accordingly.



Update on anchoring concepts

Oral and maxillofacial surgeon **Prof Gerald Krennmair** (*University of Vienna, Austria*) presented comprehensive guidance on anchoring concepts for implant-retained prostheses. According to Krennmair, there is no evidence clearly speaking for a specific anchoring concept. In a series of current studies, for example, Krennmair's working group found no differences in patient preference or prosthetic aftercare needs between ball abutment and Locator® attachments. When comparing ball abutment attachments with resilient mounted telescopic crowns, there was an initially higher prosthetic aftercare for telescopic crowns, which equalized after five years.

A comparison of bar- and telescope-supported full dentures led to the conclusion that telescopic restorations may be more difficult to manage for patients while oral hygiene is more difficult with bars. The surgical and prosthetic success rates were high for both concepts in this study. In two other studies, the Krennmair group found that

milled bars require less frequent repairs than prefabricated round bars. From all this, G. Krennmair concluded that when choosing one concept or another, preference and experience of the clinician must ultimately be the decisive factors.

Digital implant dentistry is economical

Dr Florian Beuer (*University of Munich, Germany*) outlined current possibilities of digital dentistry. Accordingly, we currently find ourselves in the phase in which the digital gaps of the (implant) prosthetic supply chain have been closed. According to Beuer, these still existing gaps are one of the reasons why CAD/CAM has been carried out mainly in the dental laboratory, until now. This could change if the intraoral situations were carefully transferred with intraoral scanning methods (CAI, Computer-Aided Impression) to the laboratory. There is still a need for development despite the correctness and accuracy of digital impressions, e.g., in edentulous arches or subgingival areas. There is also room for improvement in cast fabrication because stereolithographic processes

have not been accurate enough until now. For CAM-milled casts, the implant beds must still be drilled. Digital dentistry, however, should not be stopped and will fundamentally change the daily practice.

Digital implant dentistry: opportunities and limitations

Since 2000, the team around **Dr Axel Kirsch**, **Dr Karl-Ludwig Ackermann** and **ZTM Gerhard Neuendorff** (*Filderstadt, Germany*) has been working with CAD/CAM technologies. From the perspective of the dental technician, Neuendorff determined that much is possible, but numerous steps still require manual work and direct contact with the patient. These would include, for example, dental set-ups since small changes could have a major impact on the phonetics. These processes cannot be digitally represented as things stand today. Last but not least, the results of digital planning should be discussed with the patient and in the team. Neuendorff offered a number of practical and laboratory-related tips. He recommended trying in individual abutments on the patient to check the course of the gingival margin.



4TH INTERNATIONAL CAMLOG CONGRESS MAY 3RD - 5TH, 2012, LUCERNE

Meet the experts

"Meet the experts", moderated by Prof Gil Alcoforado (*Lisbon, Portugal*), Dr Karl-Ludwig Ackermann (*Filderstadt, Germany*) and Prof Axel Zöllner (*Witten, Germany*) represented a successful final chord to the 4th International CAMLOG Congress. Three dentists in private practice, Dr Ilaria Franchini (*Stuttgart, Germany*), Dr Arndt Happe (*Münster, Germany*) and Dr Jan Märkle (*Bad Wörishofen, Germany*), presented examples of problematic patients from their practice, which they had been able to successfully treat. They demonstrated how important, but time-consuming a thorough diagnosis is for treatment success.

"Let's rock the Alps"

And not to miss out on the social networking in a relaxed atmosphere, CAMLOG invited participants to two raving parties. Both on Friday and Saturday evening, happy congress participants and partygoers made certain

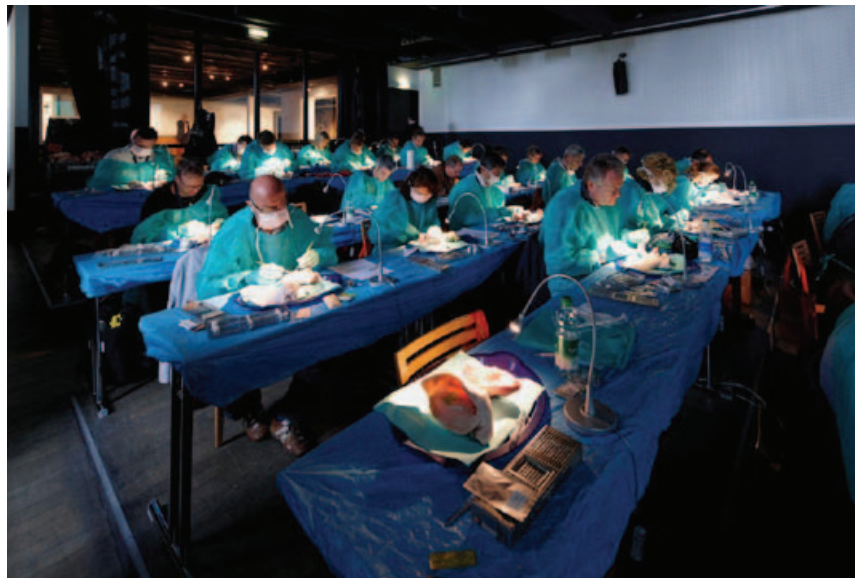that another memorable chapter was written on the "Rigi", Lucerne's "own" mountain, in the now legendary history of the CAMLOG Congress parties and this time in the Alps.

For all those who were in Lucerne or those who want to see what they missed, a number of impressions and a short video are available at www.camlogcongress.com.

Hasta la vista!

Prof Jürgen Becker, office-holding president of the CAMLOG Foundation, then thanked the participants, speakers and organizers of this again very successful CAMLOG Congress and already announced that the 5th International CAMLOG Congress 2014 will be held in Spain.



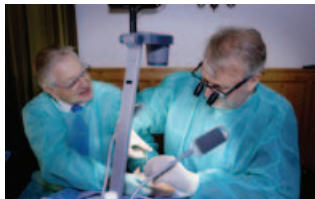

HIGH, HIGHER...: CONGRESS WORKSHOPS ON MOUNT "PILATUS"

WORKSHOP I

Various approaches in soft-tissue handling

Speakers: A. Kirsch, D. Hildebrand



WORKSHOP II

Soft-tissue management: tips & tricks & the latest trends


Speakers: C. Cacaci, P. Randelzhofer



WORKSHOP III

Conditions for optimal soft-tissue conditioning

Speakers: B. Wallkamm, P. Magnin



WORKSHOP IV

The mastery of soft-tissue management

Speakers: G. Iglhaut, M. Stimmelmayer



The surveys filled out by many of the 160 participants following the workshops sorted by "Theory", "Practical Exercises", "Timing" and "Overall Impression" gave us important feedback about how the quality of these hands-on events was classified and where we might improve.

97% of surveys submitted give the workshops a grade of "very good" or "good". Participants clearly emphasized the "high competence of the speakers", "practical application", "large number of case studies" and the handling of "critical cases and their resolution".

The "Pilatus" location visibly impressed and only travels to and from the venue were occasionally seen as "long".

We would like to thank all those who have made it possible for us to continuously improve by filling out the survey!

Images at www.camlogcongress.com



"THE FACT THAT WE HAVE THE SAME QUESTIONS BRINGS THE WORLD TOGETHER"

Interview with Prof Jürgen Becker, President of the CAMLOG Foundation

Dr Jan H. Koch for logo: The 4th International CAMLOG Congress was another great event at the highest professional level. What was particularly important to you when putting the program together?

Prof Becker: Our program team made sure that concrete clinical recommendations were presented in addition to relevant practical science, practical tips that can be implemented on the next Monday. Therefore, a number of dentists in private practices presented in Lucerne in addition to university professors. "Meet the experts" with patient cases was also a "clinical display of fireworks" of practical information.

Dr Koch for logo: Some speakers in private practices presented scientifically very interesting articles.

Prof Becker: Yes, these colleagues are also involved in research in addition to managing their own practices. This is an ideal combination, which advances implant dentistry as a whole.

Dr Koch for logo: You have been president of the CAMLOG Foundation since 2010. Why do you believe research in implant dentistry as supported by the Foundation to be so important?

Prof Becker: It is certainly surprising for many colleagues that there are no meaningful study results and long-term results specifically even today for very central clinical questions. For example, we do not know if a certain implant/abutment connection is more successful with respect to tissue integration, what significance partial augmentations have on peri-implant soft tissue or which retention elements are best suited for removable prostheses. There is a large international consensus that we need controlled clinical studies for many questions to care for our patients in a predictable manner. For this reason, the generous support by institutions like the CAMLOG Foundation is very helpful.

Dr Koch for logo: How big is the problem of peri-implantitis?

Prof Becker: Peri-implant inflammation occurs in all clinical studies after a certain functional period. The aim must be to identify patients with a higher risk and greater progression of bone loss at an early stage and to successfully treat the mucositis, which is reversible in principle, to minimize the progression of the peri-implantitis. There are still many open questions. However, they have little to do with the implant system used, but are much more about the patient.

Dr Koch for logo: How is the CAMLOG Foundation positioned worldwide?

Prof Becker: A large part of the funded research groups are in Europe. Today, we also support projects in Korea, China and Japan. The clinical questions and the product systems used are the same worldwide. Therefore, conversations with colleagues are immediate no matter the country. Implant dentistry brings the world together.

Dr Koch for logo: Is implant dentistry still a growth market?

Prof Becker: Yes, without question. In Germany, for example, I estimate the potential of further growth in the coming years as significant, perhaps even doubling today's numbers. This is also due to the extensive training offered by the professional associations, which have been and continue to be used by many colleagues. Furthermore, implant dentistry is being integrated in academic programs. Very helpful here, for example, are the concepts of the DGI (German Implantology Society) that elements of the curriculum can be completed during the course of one's studies. A good education is a key component in allowing as many patients as possible to benefit from implants. And the CAMLOG Foundation is active here with its national and international congresses.



THE CAMLOG FOUNDATION RESEARCH PRIZE 2010/2011 AWARD AND POSTER COMPETITION AT THE 4TH INTERNATIONAL CAMLOG CONGRESS

The CAMLOG Foundation Research Prize Award for 2010/2011 and the Poster Competition were two important events during the 4th International CAMLOG Congress. These two awards recognized the work of scientists and/or dental practitioners in the field of implant dentistry and related research. No less than ten publications had been registered for the Research Prize by participants coming from six countries [Austria (one), France (one), Germany (four), India (one) Iran (one), and Sweden (two)]. The submitted papers had been accepted by or published in prestigious journals such as *Clinical Oral Implant Research*, *Clinical Oral Investigations*, *Journal of Clinical Periodontology*, *Journal of Dental Research*, *Journal of Nanomedicine*, *Journal of Orthopedic Research*, and *Journal of Synchrotron Radiations*.

Twenty-seven posters were exhibited during the congress. Congress participants had the opportunity to meet the authors and discuss the results during the breaks.

CAMLOG Foundation Research Prize 2010/2011

The research prize is exclusively reserved for young professionals working in the field of implant dentistry. One of the aims of the CAMLOG Foundation is to encourage young scientists in their work. Therefore, the research prize is granted with a total amount of EUR 20,000 awarded as follows: EUR 10,000 for the first prize, EUR 6,000 for second prize and EUR 4,000 for third prize. Another distinction was that the winner had the occasion of presenting his/her work during the plenary session of Saturday afternoon. CAMLOG is pleased to introduce to you the work of three young scientists by presenting the summaries of their publications as available on *PubMed*.

1st prize


The winner DDr Arno Wutzl presented the paper:

Wutzl A, Rauner M, Seemann R, Millesi W, Krepler P, Pietschmann P, Ewers R. Bone morphogenetic proteins 2, 5, and 6 in combination stimulate osteoblasts but not osteoclasts in vitro. J Orthop Res. Nov. 2010;28(11):1431-9

Abstract:

Bone regeneration is required for fracture healing. Various procedures have been used to promote osteogenesis with bone morphogenetic proteins (BMPs). We assessed the effects of BMP-2, BMP-5, and BMP-6 in isolated and combined use on the generation of osteoblasts and osteoclasts by comparing the osteoclastic potency of each or a combination on osteoclasts of primary murine bone marrow cells. Subsequently, cells were stained for tartrate-resistant acid phosphatase, and real time PCR analysis of receptor activator of NK κ B ligand and osteoprotegerin was conducted. The same combination of BMPs was used to assess their potential to enhance osteoblasts, employing a mineralization assay and real-time PCR analysis of collagen type-1, runx2, and osterix. While BMP-2 alone and the combination of BMP-2 and BMP-5 significantly enhanced osteoclastogenesis, BMP-2,

BMP-5, and BMP-6 in combination did not have additional effects. However, the combined use of BMP-2, BMP-5, and BMP-6 had an additive effect on matrix mineralization and osterix expression in osteoblasts. Our study shows that the combination of BMP-2, BMP-5, and BMP-6 stimulates osteoblasts but not osteoclastogenesis. Thus, the synergistic use of various BMPs might improve effective bone regeneration in the clinical setting.



DDr Arno Wutzl

2nd prize

Harder S, Quabius ES, Ossenkop L, Kern M. Assessment of lipopolysaccharide microleakage at conical implant-abutment connections. *Clin Oral Investig* Dec. 2, 2011 [Epub ahead of print]

Abstract:

Objective: The aim of this in-vitro study was to assess lipopolysaccharide microleakage at conical implant-abutment connections of two-piece dental implants in terms of the expression levels of genes involved in lipopolysaccharide-mediated pro-inflammatory cytokine production.

Materials and methods: Two implant systems with conical implant-abutment connections were inoculated with lipopolysaccharide and submerged in human whole blood. Positive-control blood samples (without implants) were stimulated with 4 µg/ml, 2 µg/ml, 200 ng/ml, and 20 ng/ml lipopolysaccharide. Sampling was performed after 1, 8, and 24 h of incubation. Changes of gene

expression levels of Toll-like receptor 9, tumor necrosis factor- α , nuclear factor kappa light chain enhancer of activated B cells, interleukin-1 β , and interferon- γ were assessed by real-time quantitative PCR. In addition, protein expression levels of interleukin-6, tumor necrosis factor- α , interleukin-1 β , and interferon- γ were determined by immunoassay.

Results: Changes in cytokine expression at the genomic and proteomic levels indicated lipopolysaccharide leakage at the interfaces of both tested implant systems, although some implants showed no sign of microleakage. Any tested concentration of lipopolysaccharide stimulated similar gene expression.

Conclusion: Conical implant-abutment connections of two-piece dental implants do not prevent microleakage on a molecular level. Changes in lipopolysaccharide-induced proinflammatory cytokine gene expression facilitate the detection of lipopolysaccharide microleakage at implant-abutment interfaces.



Dr Sönke Harder

Clinical relevance: Small amounts of lipopolysaccharide released from intra-implant cavities can stimulate a detectable immunological response in human whole blood and may induce alveolar bone resorption via the osteoclast-activating pathway.

3rd prize

Schwarz F, Sahm N, Mihatovic I, Golubovic V, Becker J. Surgical therapy of advanced ligature-induced peri-implantitis defects: cone-beam computed tomographic and histological analysis. *J Clin Periodontol*. Oct. 2011;38(10):939-49.

Abstract:

Objective: To evaluate radiological bone level (RBL) (i.e., cone-beam computed tomography) and histological bone levels (HBL) as well as re-osseointegration [bone-to-implant contact (BIC)] after surgical resective (i.e., implantoplasty) and/or regenerative therapy of advanced ligature-induced peri-implantitis in dogs.

Materials and methods: At all defect sites (n=6 dogs, n=48 implants), the intrabony component was filled with

a particulate bovine-derived natural bone mineral (NBM). The supracrestal component was treated by either the application of an equine bone block (EB) or implantoplasty. In a split-mouth design, NBM and EB were soaked with recombinant human bone morphogenetic protein (rhBMP)-2 or sterile saline. All sites were covered by a native collagen membrane and left to heal in a covered position for 12 weeks.

Results: A premature wound exposure was observed at nine defect sites. Mean RBL and HBL values were lowest in the P+rhBMP-2 group, reaching statistical significance when compared with the EB group. Mean BIC values were comparable in all groups. Within-group comparisons commonly revealed a close correlation between RBL and HBL values.

Conclusion: It was concluded that (i) in all groups the investigations failed to predictably obtain complete defect resolution, (ii) the surgical procedure was associated with high exposure rates, and (iii) RBL was closely correlated with HBL.



Prof Frank Schwarz



Poster exhibition

A total of twenty-seven posters representing seven countries (Austria, Germany, Italy, Japan, Spain, Taiwan and Turkey) were exhibited. These posters could be classified into three different groups: basic research, clinical studies and case reports. The three selected posters received a total amount of CHF 4,500 divided as follows: CHF 2,000 for the first prize, CHF 1,500 and CHF 1,000 for the second and third prize, respectively.



Dr Arthur Hehn

First prize

The first Poster Prize was attributed to Dr Arthur Hehn (*private practice in Lauda, Germany*), who had examined the hypothesis whether thickening of the mucosa could reduce initial bone resorption. Ref: Hehn A, Schlee M. Does thickening of the mucosa avoid the initial bone resorption around implants? A prospective, randomized, controlled trial.

camlogfoundation



Second prize

Dr Thomas Ziebart (*Department of Maxillofacial Surgery, Johannes Gutenberg University, Mainz, Germany*) received the second prize. The group tested the hypothesis that on a titanium surface, osteoblasts can be positively influenced by endothelial progenitor cells (EPC).

Ref: Ziebart T, Boddin A, Pabst A, Klein MO, Al-Nawas B. Increased differentiation of osteoblasts by endothelial progenitor cells (EPC) on a titanium surface.



Dr Thomas Ziebart, Prof Fernando Guerra

Third prize

The third prize was awarded to Prof Yasmine Kulak-Özkan (*Faculty of Dentistry, Marmara University, Istanbul, Turkey*). The team evaluated the incidence of the most common technical problems in implant-supported fixed partial dentures (FPDs) and assessed the survival and success rates (event-free survival) after 5 to 10 years of function. Ref: Kulak-Özkan Y, Akoğlu B, Özkan Y. Prosthetic complications of implant-supported fixed partial dentures in partially edentulous cases after an observation period of 5 to 10 years.



Prof Yasmine Kulak-Özkan

After the award is before the award...

Poster exhibition: www.camlogfoundation.org/awards.

The invitation to participate in the CAMLOG Foundation Research Prize 2012/2013 is now open. Registration and conditions for participation are available at: www.camlogfoundation.org/awards. As a young scientist, do not miss this outstanding opportunity.

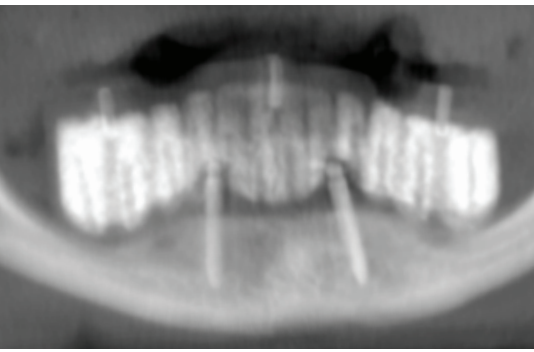


Fig. 1: Initial radiograph

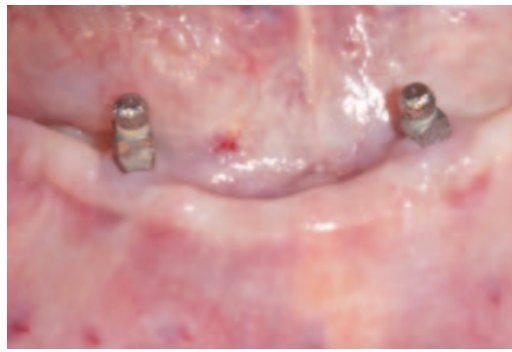

Fig. 2: Initial clinical situation

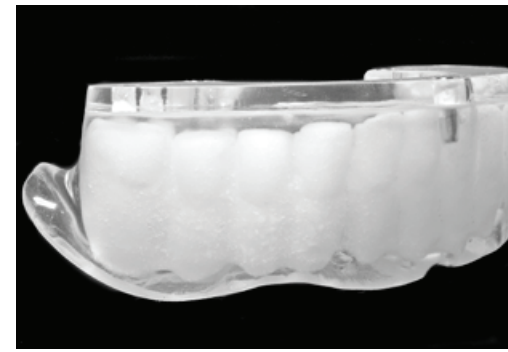

Fig. 3: Scanning template made from barium sulfate-added plastic



IMMEDIATE RESTORATION IN THE EDENTULOUS MANDIBLE ACCORDING TO THE MALÓ PROCEDURE USING THE CAMLOG® GUIDE SYSTEM AND VARIO SR ABUTMENTS

Dr Ferenc Steidl, Sömmerda and Bad Frankenhausen, and MDT Sebastian Schuldes, M.Sc., Eisenach

The Vario SR prosthetic components for fixation of implant-supported occlusally screw-retained restorations were used in this case report to treat neuropathic pressure-indicated facial pain. The 66-year-old patient came to our practice for the first time in May 2010 complaining of persistent pain in the right mandible. The pain intensified with the complete mandibular denture inserted. However, pronounced pain continued even after several days of not using the prosthesis. The intensity of the pain varied between 6 and 10 on the VAS scale (Visual Analog Scale).

The following diagnosis was made:

- Severe mandibular atrophy
- Crestal position, mental foramen bilateral
- Chronic neuralgiform facial pain in regions 43 to 45; trigger point indicates mental foramen region.

Case report

The patient was treated with two one-piece diameter-reduced implants in regions 33 and 43, as well as a complete mandibular denture anchored by ball abutments (Figs. 1 and 2).

After extensive counseling and discussion, we opted therapeutically for a temporary, fixed mandibular restoration on four implants with simultaneous explantation of the existing implants.

Benefits of the selected restoration concept:

- Explantation, implantation and immediate restoration in one sitting
- High level of safety thanks to three-dimensional implant planning
- Durable temporary restoration of CAD/CAM high-performance plastic
- Precision template-guided implantation with the CAMLOG® Guide System
- High patient satisfaction with fixed screw-retained immediate restoration.

Preimplantation planning

Because the existing denture satisfied the basic esthetic and functional requirements, the given situation was converted into barium sulfate-added plastic according to "backward planning". The prosthetic situation desired in the future was completed with clear plastic and the titanium reference pin for the scanning template (Fig. 3). To make the prosthetic tooth axis visible in the DVT data set, holes were drilled through the radiopaque teeth in this axis (Fig. 4).

The DICOM data was then read into the coDiagnostiX™ (Straumann) implant planning system. Computer-supported analysis offers the possibility of accurate diagnosis, as well as planning the implants in agreement with anatomical and prosthetic requirements (Figs. 5a and 5b). Positioning of the dorsal implants in an exact 30° angle is a crucial requirement for the success of this treatment concept (Figs. 6 and 7).

Fabrication of the drilling template and the immediate restoration

The position of the implant determined in 3D implant planning was transferred to the drilling template in the dental laboratory using the gonyX coordinate table. The guiding sleeves with depth stops belonging to the CAMLOG® Guide System were precisely bonded into the scanning template, thereby converting the scanning template into a drilling template (Fig. 8).

To fabricate the immediate restoration, a "model implantation" was required in a first step. Corresponding cavities were incorporated into the cast (Fig. 9). The CAMLOG® Guide insertion posts were then used to insert the lab analogs into

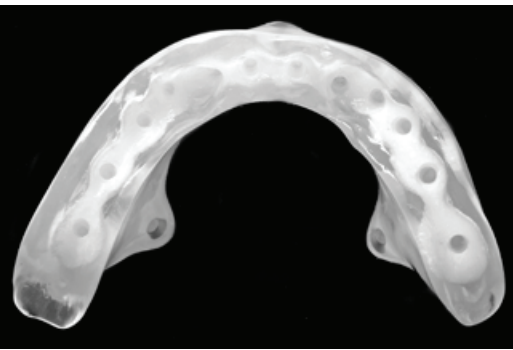


Fig. 4: Holes drilled through the radiopaque teeth according to the prosthetic tooth axis

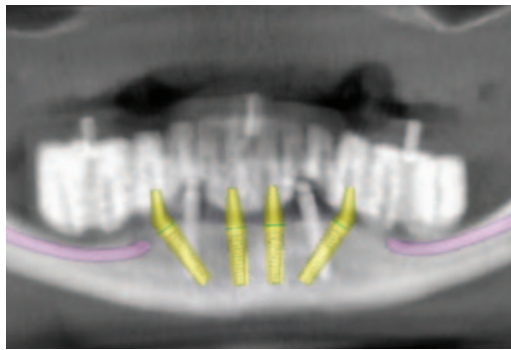


Fig. 5a: Diagnostics and planning of the implants ...

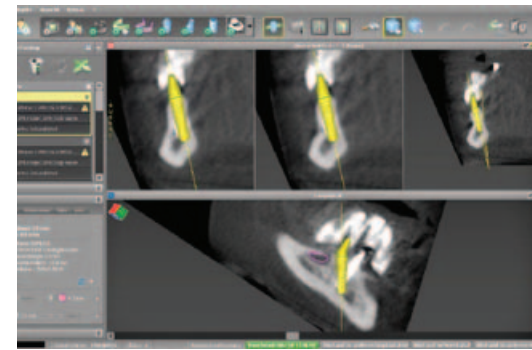


Fig. 5b: ...in the consensus of anatomical and prosthetic requirements

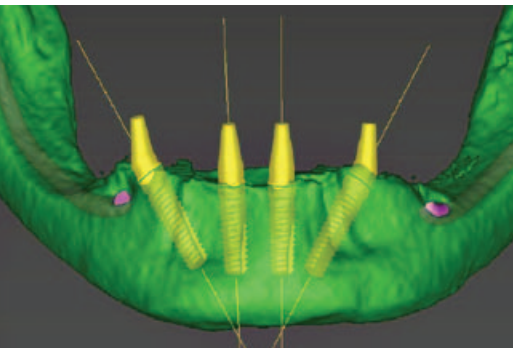


Fig. 6: Positioning of the dorsal implants in an exact 30° angle

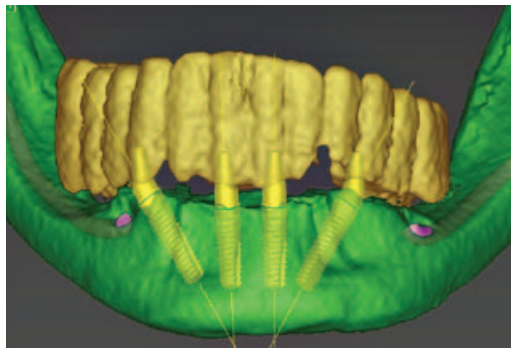


Fig. 7: View with the superimposed radiopaque parts

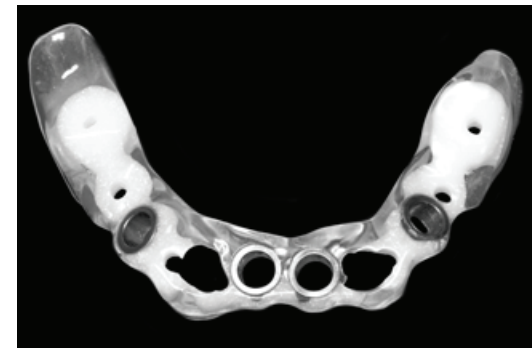

Fig. 8: The scanning template was converted into a drilling template.

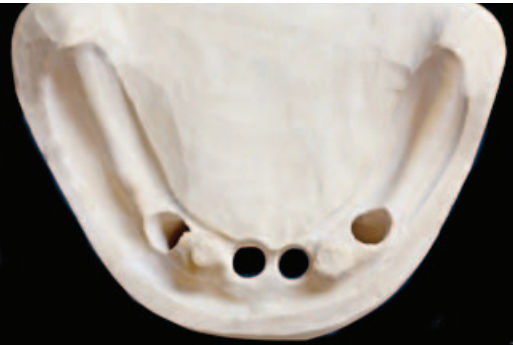

Fig. 9: Preparation of the cast for "model implantation"

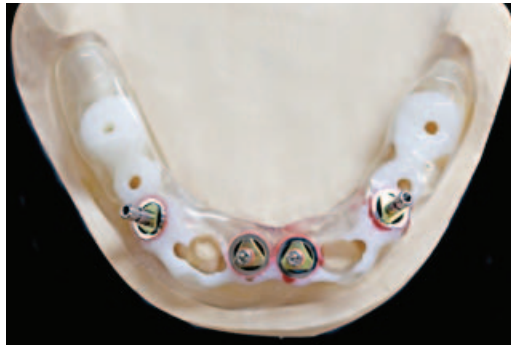

Fig. 10: The insertion posts in the required cam alignment with the screw-retained lab analogs

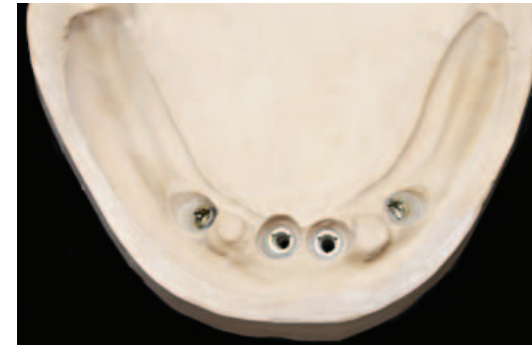

Fig. 11: Lab analogs placed in the cast

the cast (**Fig. 10**). It was important here to position the insertion posts with the screw-retained lab analogs according to the required cam alignment (**Fig. 11**).

Figs. 12 and 13 show the Vario SR abutments and Vario SR titanium caps on the cast.



Abb. 12: Cast with screw-retained straight Vario SR abutments



Fig. 13: The Vario SR abutments with the Vario SR titanium gaps




Fig. 14: Digitalized cast situation

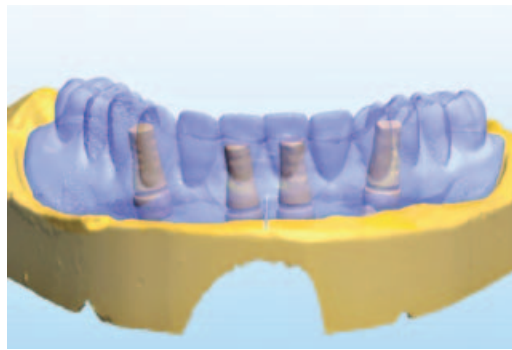


Fig. 15: Desired prosthetic situation matched with the cast situation

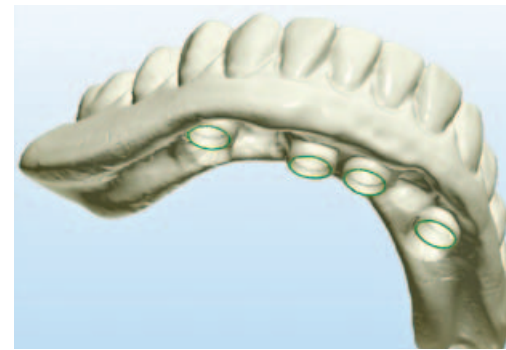


Fig. 16: CAD design created with Dental Designer™ (3shape)

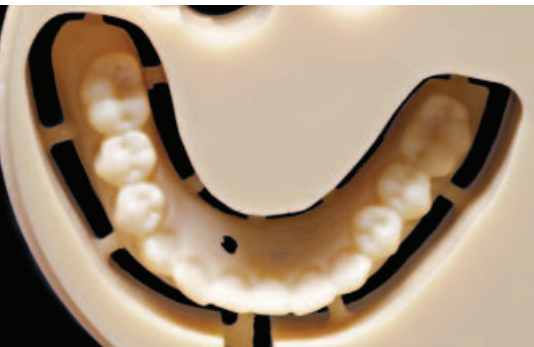

Fig. 20: Detailed preparation of the occlusal surfaces

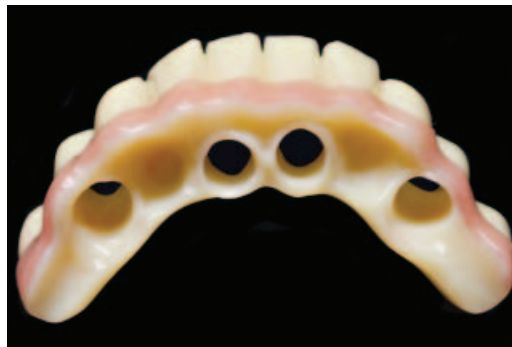


Fig. 21: Esthetic customization using gingiva-colored plastic from basal...

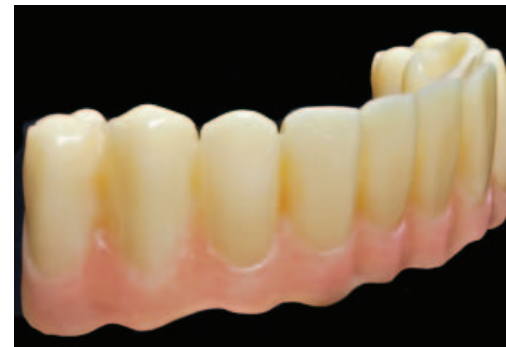

Fig. 22: ...and labial

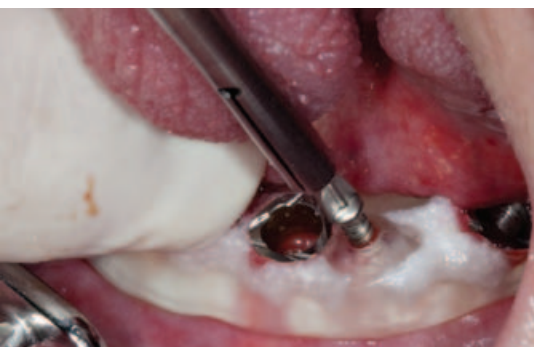

Fig. 26: Fixation of the drilling template using four osteosynthesis screws

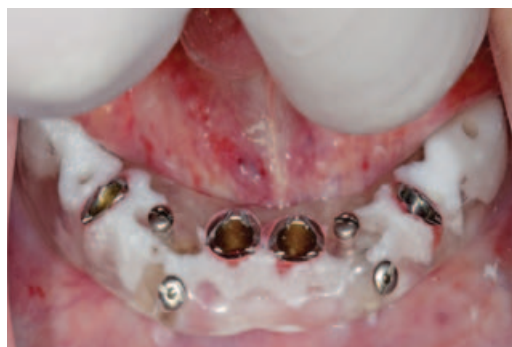

Fig. 27: Fixed drilling template

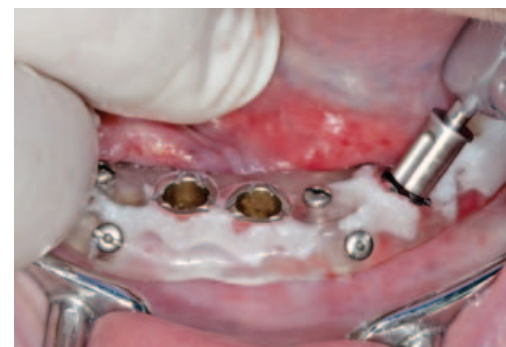

Fig. 28: Gingiva punching

A laser scanner was then used to digitalize this cast situation (**Fig. 14**). To simplify the CAD design of the immediate restoration, it makes sense to also scan the desired prosthetic situation defined by "backward planning" and to match that with the existing data set (**Fig. 15**). The CAD design was created with Dental Designer™ (3shape) (**Figs. 16 and 17**). After calculating a suitable milling strategy, the data was transferred to a 5-axis milling machine. A tooth-colored PMMA blank was used as the material of choice (**Figs. 18 to 20**).

In contrast to traditionally fabricated temporary solutions, CAM-fabricated immediate restorations distinguish themselves by their high resistance to fracture. This property is an important technical requirement for complication-free function of the restoration. To achieve pleasing esthetics, gingiva-colored plastic was additionally used (**Figs. 21 and 22**). To keep plaque deposits as low as possible, careful polishing is required. The bonding gap around the Vario SR titanium caps should be sized accordingly for tension-free intraoral bonding (**Fig. 23**).

Surgical procedure

The one-piece diameter-reduced implants were explanted (**Figs. 24 and 25**).

The drilling template was secured using four osteosynthesis screws (**Fig. 26**). These provided adequate stability and safety for guided implantation. To correctly align the insertion posts, corresponding markings were milled into the CAMLOG® Guide guiding sleeves in the laboratory (**Fig. 27**).

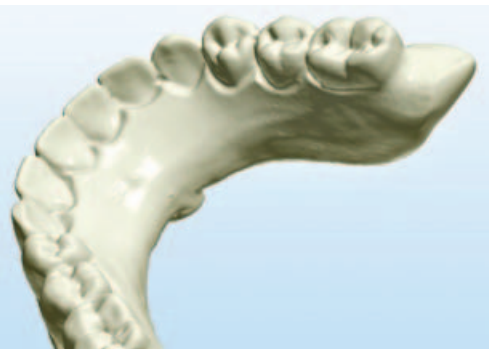

Fig. 17: The second molars were omitted



Figs. 18 to 20: CAM implementation...



Fig. 19: ... via a tooth-colored PMMA blank

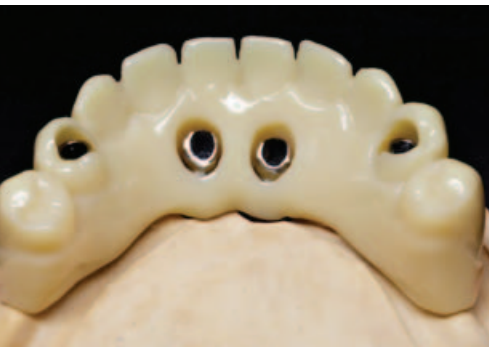

Fig. 23: Adequately sized bonding gap for intraoral bonding

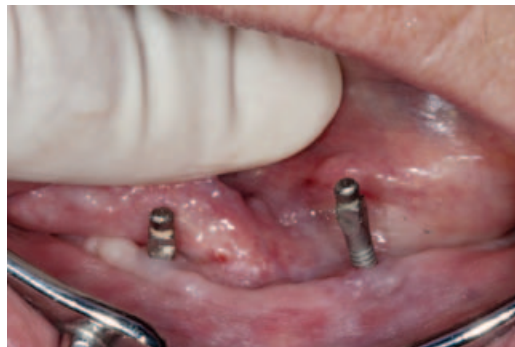

Fig. 24: Explantation of the one-piece diameter-reduced implants



Fig. 25: The explants

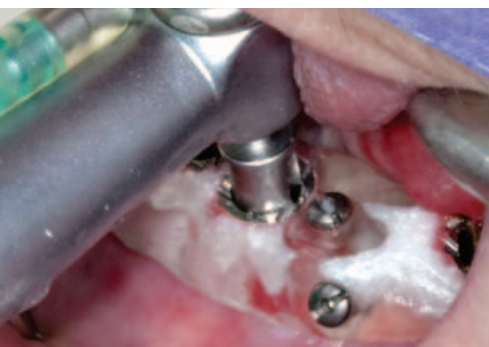

Fig. 29: Implant bed preparation with the CAMLOG® Guide form drill

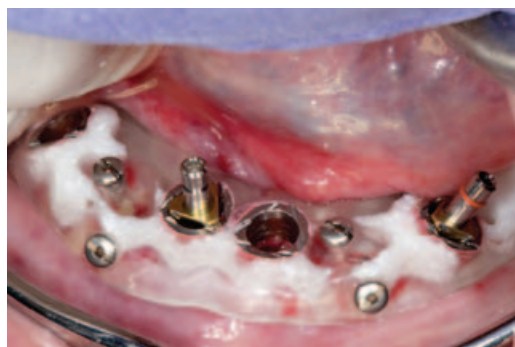
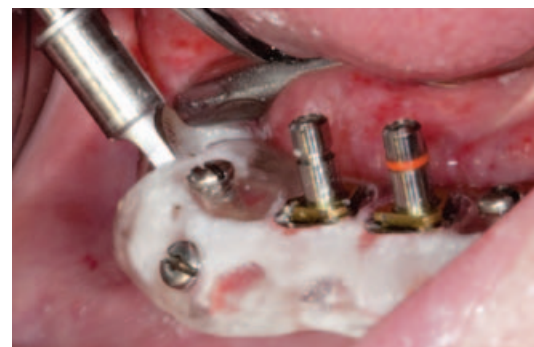
Fig. 30: Positioning of one center and one terminal implant



Figs. 31 and 32: Implant bed preparation and insertion of the fourth and final implant

Implantation was flapless using the CAMLOG® Guide System gingival punch (Fig. 28). The implant bed is accurately prepared with the CAMLOG® Guide System and depth referenced with drills of ascending lengths in an intermittent drilling technique (Fig. 29). After inserting a central implant, a terminal implant was inserted (Fig. 30). The second centrally positioned implant was then placed and then the second terminal implant (Figs. 31 to 34).

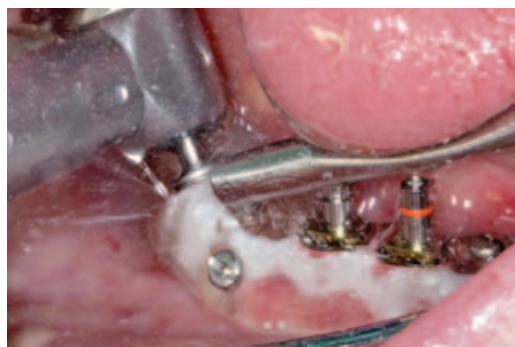

Fig. 32

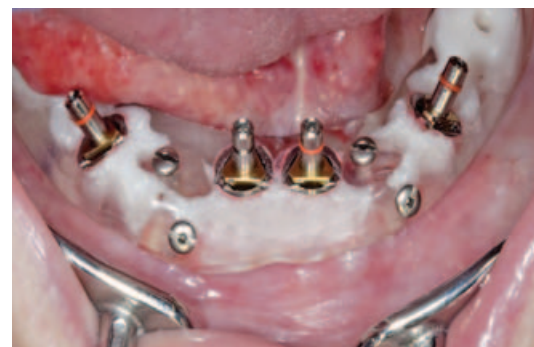

Fig. 33: All four SCREW-LINE implants CAMLOG® Guide in the defined final positions

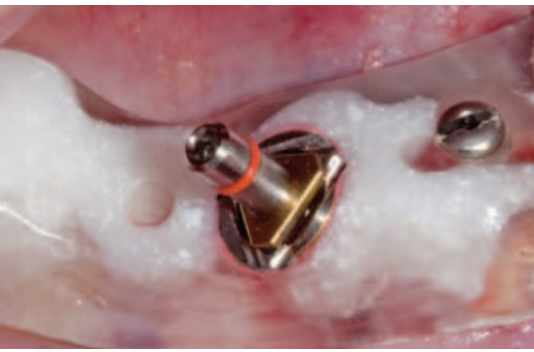

Fig. 34: Detailed view of the precisely maintained cam alignment

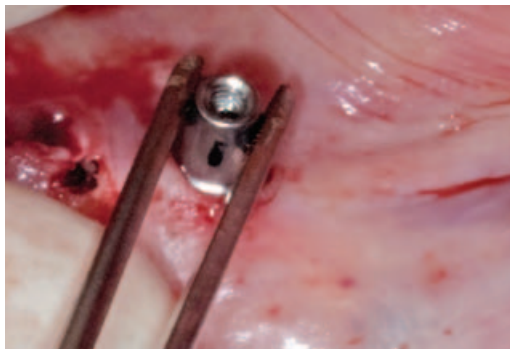


Fig. 35: The Vario SR abutments are inserted ...

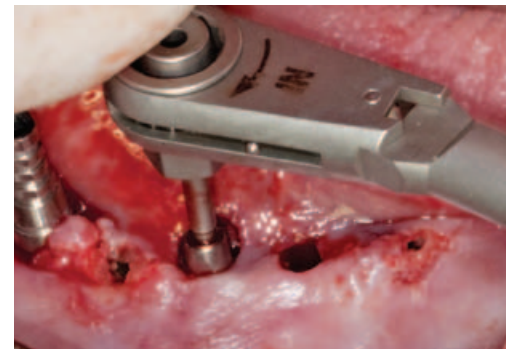


Fig. 36: ... and attached with 20 Ncm

Inserting the immediate restoration

After removing the CAMLOG® Guide Insertion posts, the Vario SR abutments were inserted and attached with 20 Ncm (**Figs. 35 and 36**). The Vario SR titanium caps were shortened to the required length and placed on the Vario SR abutments and mounted with the Vario SR prosthetic screw (**Fig. 37**). The pre-implantation fabricated immediate restoration could then be bonded in the mouth tension-free (**Figs. 38 to 41**).

Discussion

The procedure shown here that follows the All-on-4 procedure taught by Paulo Maló, Lisbon, led to a complete disappearance of the severe facial pain about two months postoperatively. The immediately fixed prosthetic restoration was highlighted in particular in the patient's evaluation. This resulted in an immediate improvement in mastication, speech function, food intake and quality of life. Remission of neuralgiform symptoms protracted over two months after insertion of the fixed prosthesis and corresponding load relief of the mental foramen.

This case illustrates the failure of a number-reduced implant treatment concept in the advanced atrophied mandible and the potential of purely implant-supported prostheses to avoid pressure-induced neuropathies.

In the meantime, the mandibular restoration was converted into a removable bar-retained superstructure (**Figs. 42 and 43**).

AUTHORS



Dr Ferenc Steidl:

1991 to 1996, study program in dentistry at FSU Jena. Subsequent specialist training in oral surgery in Bietigheim-Bissingen, Germany, and at Diakonie Hospital, Schwäbisch-Hall, Germany; has been practicing implant dentistry since 1997. 2001, Specialist in oral surgery at LZK Baden-Württemberg, Germany. Member of DGZMK, BDO, DGI, AG oral surgery, DGP, MVZI. 2008, Fellow of the European Board of Oral Surgery (European certification). Dental group practice for maxillofacial surgery in Sömmerda und Bad Frankenhausen, Germany.



MDT Sebastian Schuldes, M.Sc.:

1991 to 1995, dental technician training; 1998 to 1999, qualification for master dental technician. 1999 to 2000, continuing education for business administration in trade. 2004, organization of the CERCON Technology Center. 2006 to 2008, study program leading to a Master of Science, M.Sc.

FURTHER READING

- [1] Ackermann KL, Kirsch A, Nagel R, Neuendorff G. Mit Backward Planning zielsicherer Therapien. Teil 1: Implantat-prothetische Behandlungsbeispiele teamwork J Cont Dent Educ 2008; 466–484.
- [2] Agliardi E, Panigatti S, Clericó M, Villa C, Maló P. Immediate rehabilitation of the edentulous jaws with full fixed prostheses supported by four implants: interim results of a single cohort prospective study. Clin. Oral Impl. Res. 21, 2010; 459–465.
- [3] Franchini I, Daverio L, Castellaneta R, Rossi MC, Testori T, Tosini T. Immediate and delayed "All-on-Six" rehabilitation of the atrophic maxilla with tilted implants. EDI 2009;5:62–70.
- [4] Malo P, de Araújo Nobre M, Lopes A, Moss SM, Molin GJ. A longitudinal study of the survival of All-on-4 implants in the mandible with up to 10 years of follow-up. J Am Dent Assoc 2011;142(3):310–20.
- [5] Kirsch A, Nagel R, Neuendorff G, Fiderschek J, Ackermann KL. Backward Planning und dreidimensionale Diagnostik, Teil 2: Schablonengeführte Implantation nach CT-basierter 3D-Planung mit sofortiger Eingliederung des präfabrizierten Zahnersatzes – ein erweitertes Backward Planning-Konzept. teamwork J Cont Dent Educ 2008; 734–754.
- [6] Ranzelzhofer P, Cacaci C. Verschraubte Lösung – implantatgetragene Restauration im zahnlosen Oberkiefer. teamwork J Cont Dent Educ 2011; 294–300.

Contact information

Praxis Dr Ferenc Steidl
DRK Krankenhaus
An der Wipper 2
D-06567 Bad Frankenhausen, Germany
Tel.: +49 3634 317387
info@praxis-steidl.de
www.dr-steidl.de

Dental-Labor Schuldes
Johann-Sebastian-Bach-Straße 2
D-99817 Eisenach, Germany
Tel.: +49 3691 203950
info@zahn-neu.de
www.zahn-neu.de

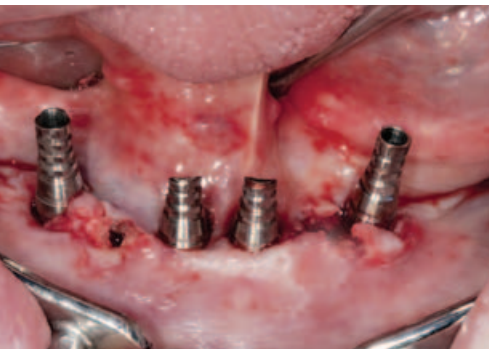


Abb. 37: The Vario SR titanium caps shortened according to the prosthetic unit

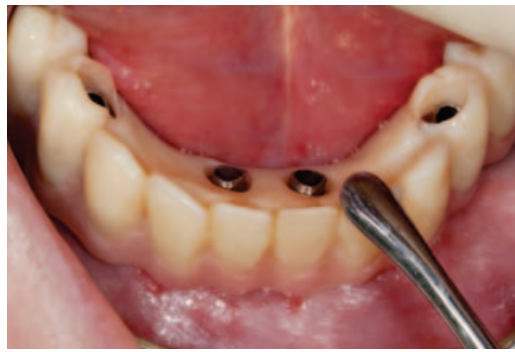

Fig. 38: Check of the tension-free seating of the immediate restoration on the Vario SR titanium caps

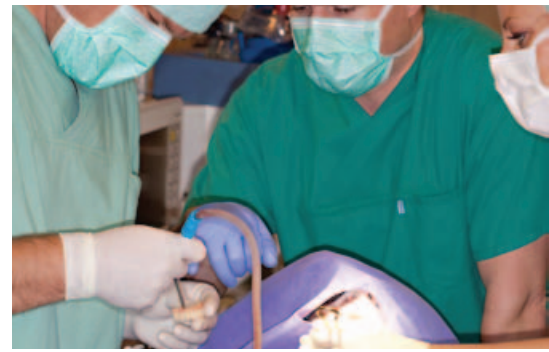

Fig. 39: The surgical procedure ran stress-free and controlled

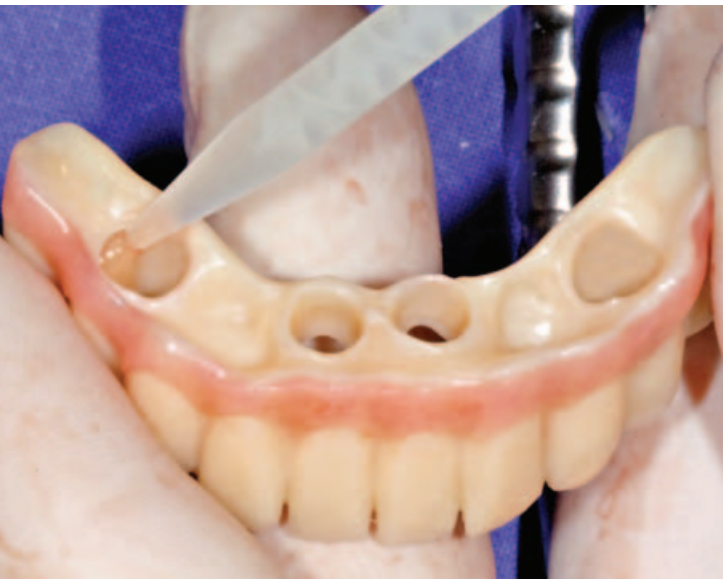

Fig. 40: A dual-hardening luting composite (combo.lign, Bredent) was used for intraoral bonding of the immediate restoration

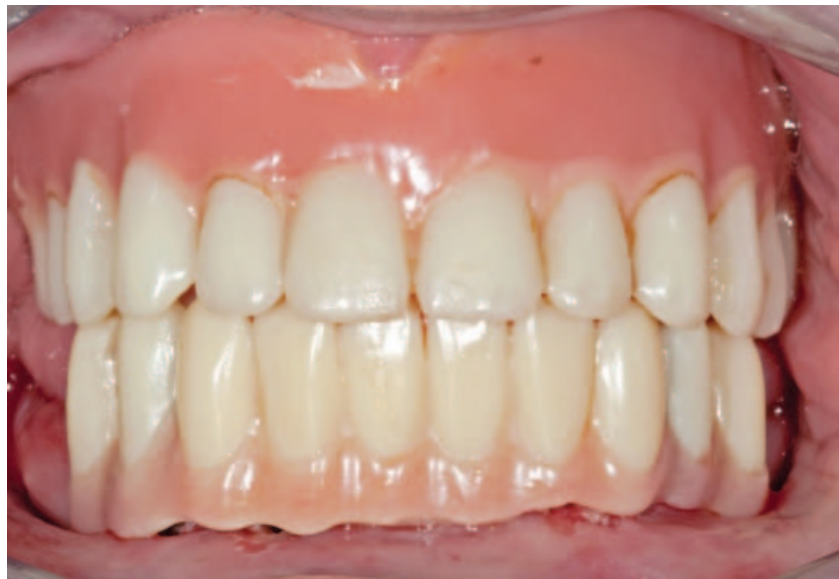

Fig. 41: Final photo of the immediate restoration in the mandible

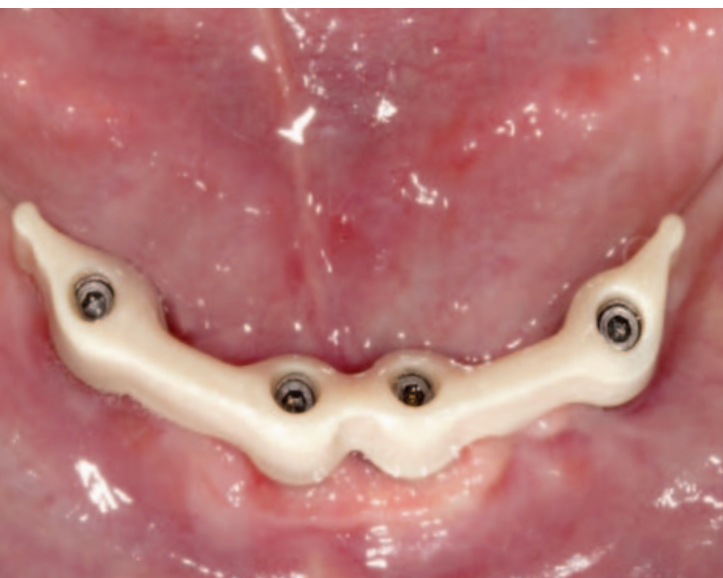
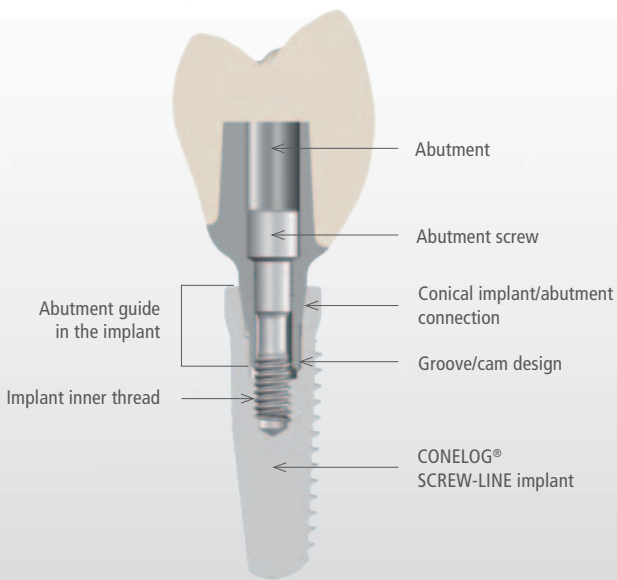


Fig. 42: The final restoration was carried out using a milled bar of zirconium oxide

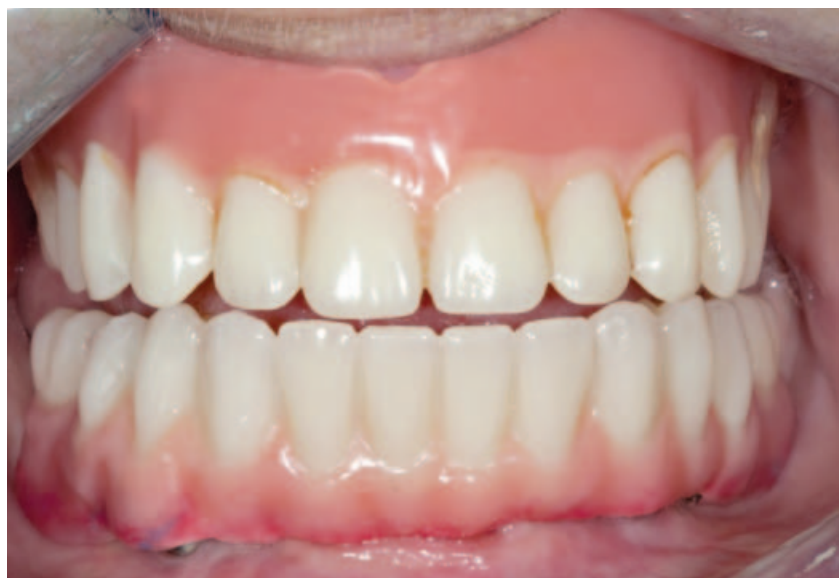

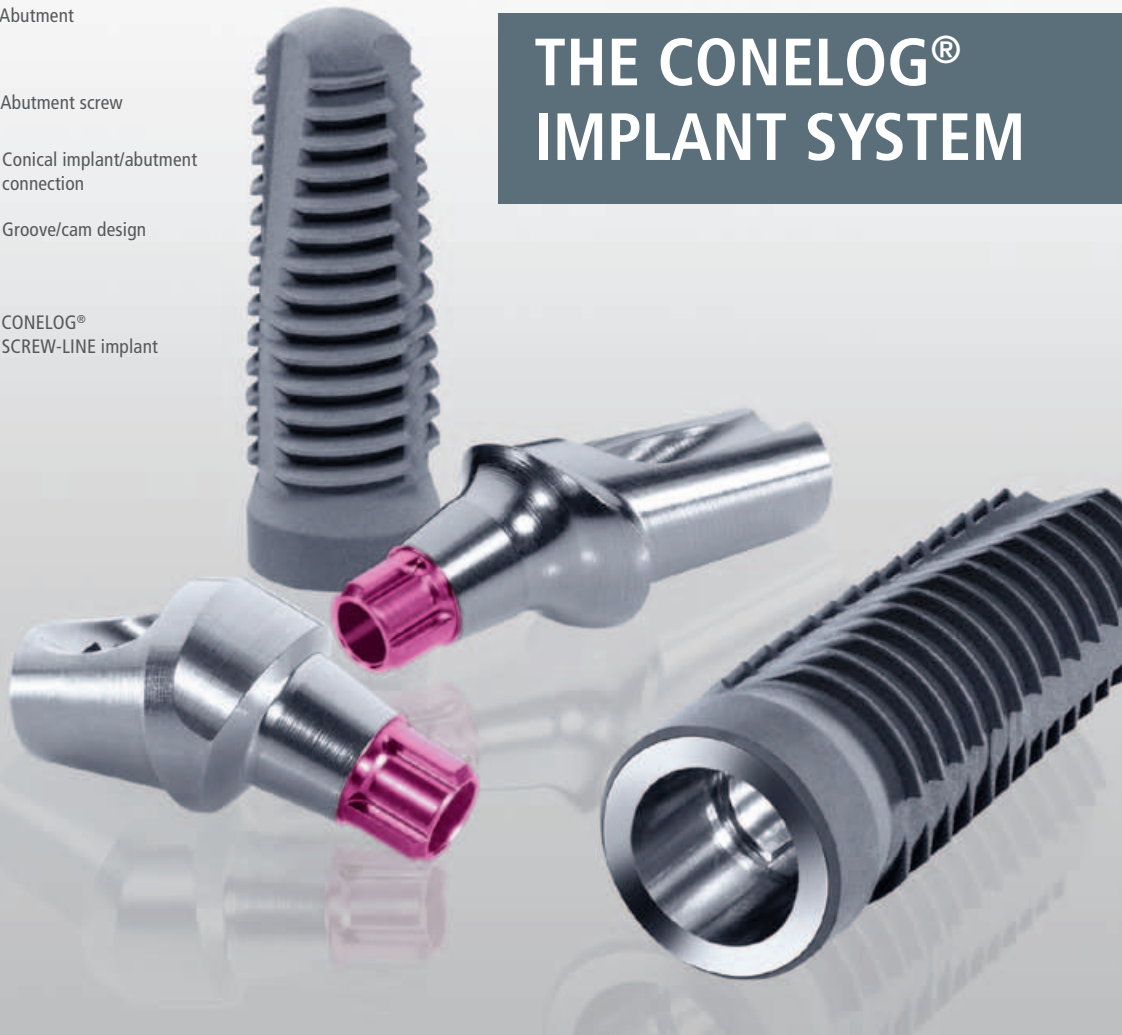Fig. 43: View of the final mandibular restoration



THE CONELOG® IMPLANT SYSTEM



FIVE PERSONAL OPINIONS ABOUT THE CONELOG® IMPLANT SYSTEM

After the successful market introduction of the CONELOG® Implant System at the International Dental Show 2011, CAMLOG was able to quickly determine that the "twin" of the proven CAMLOG® Implant System has panned out very well and has won over many supporters of conical implant/abutment connections. In recent months, the product portfolio of the CONELOG® Implant System has been continuously expanded. All prosthetic options from the highly esthetic single-tooth restoration using the titanium base CAD/CAM to the removable hybrid restoration with Locator® abutments are now available. With the system complete, a basis has been created to continue writing the young success story of the CONELOG® Implant System. Representative of all supporters of the CONELOG® Implant System, the "logo" editorial department has asked some pioneering users about their personal opinions, which we want to present here.

**Dr Georg Bayer and
Dr Steffen Kistler,**
Landsberg am Lech, Germany



"We were able to use the CONELOG® Implant System even before market introduction as part of a multicenter study and have regularly been using CONELOG® SCREW-LINE implants. Subcrestal implant positioning in conjunction with platform switching plays an important role in our concept. Our experience confirms that the crestal bone level is very well preserved and long-term stable conditions are to be expected. Because we are also working with the CAMLOG® Implant System, we are able to take advantage of a benefit: CAMLOG® SCREW-LINE implants and CONELOG® SCREW-LINE implants are inserted using the same surgery set. In other words, we can decide during surgery which of the two implant types to use. This option is effective when the implant bed is not so good in the bone due to a narrow alveolar ridge and the implant cannot be placed as deep as expected. In such cases, a CAMLOG® SCREW-LINE implant with a 1.4 mm machined neck portion can be used instead of a CONELOG® SCREW-LINE implant.

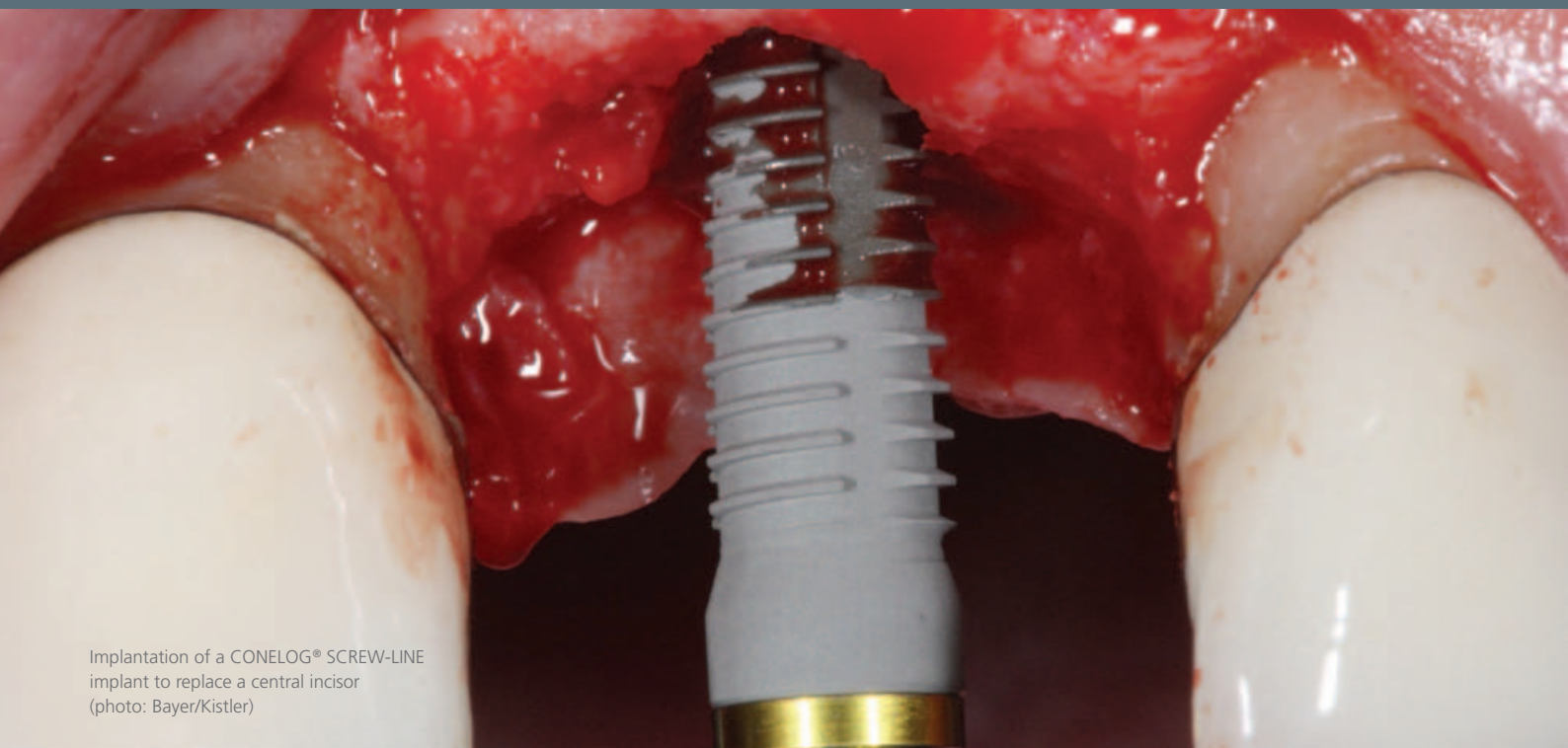
For single teeth, we most often use CONELOG® SCREW-LINE implants in the anterior tooth region because in this indication, the benefits of the system come into play most. Short implants

have also proven their value in our practice and we normally prefer them in the severely atrophied jaw to an iliac crest augmentation. In the past, the standard implant length was 13 mm, but is 11 mm or less today.

We also had good results throughout the prosthetic phase with the CONELOG® Implant System. Indexing typical of CAMLOG is very convenient to use. The transfer from the cast to the patient's mouth does not require the use of an insertion key. Our referring dentists also confirm the ease of handling in the prosthetic restoration.

Based on our experience, the price plays a role when a restoration is planned on several implants or when the patient has to be convinced of an implant treatment using cost-benefit arguments. The price-performance ratio of CAMLOG is unparalleled – in the mid-price range with high demands on quality. It is worth noting that the newly developed CONELOG® Implant System fits seamlessly into the price level of CAMLOG, that has remained consistent for years, and that cost increases are not passed on to the customer as is often the case. We appreciate this corporate philosophy very much."

For single teeth, we most often use CONELOG® SCREW-LINE implants in the anterior tooth region because in this indication, the benefits of the system come into play most (...) The price-performance ratio of CAMLOG is unparalleled – in the mid-price range with high demands on quality (...) We appreciate this corporate philosophy very much."



Implantation of a CONELOG® SCREW-LINE
implant to replace a central incisor
(photo: Bayer/Kistler)

**Dr Claudio Cacaci and
Dr Peter Ranzelzhofer, Munich**



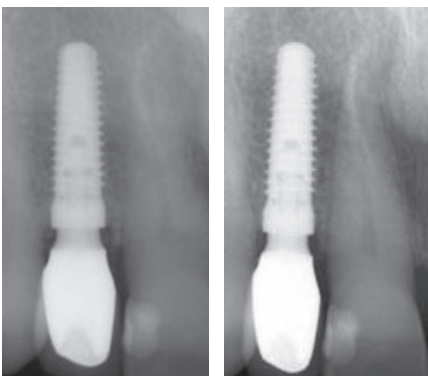
"In the prosthetic phase, we were very much surprised with the CONELOG® SCREW-LINE implant (...)
It is easier to handle than other conical systems – just "CAMLOG-like" (...) The bone level remains stable and speaks for a high-strength implant/abutment connection."

"In October 2010, the world's first CONELOG® SCREW-LINE implant was used on a patient in our practice as part of a multicenter study. Thanks to our experience with CAMLOG® SCREW-LINE implants, where the same surgical instruments are used, handling was immediately familiar to us. Due to the uniform SCREW-LINE outer geometry, the surgical procedure is identical for both systems. The only exceptions are the different insertion depths. In contrast to the CAMLOG® implants, the CONELOG® SCREW-LINE implants have no machined neck portion. The Promote® surface extends up to the implant shoulder. Accordingly, the CONELOG® SCREW-LINE implant must be positioned epicrestally or slightly subcrestally. In any case, the rough implant surface must be covered by the bone. Especially buccally, GBR techniques must be used to compensate for deficient areas.

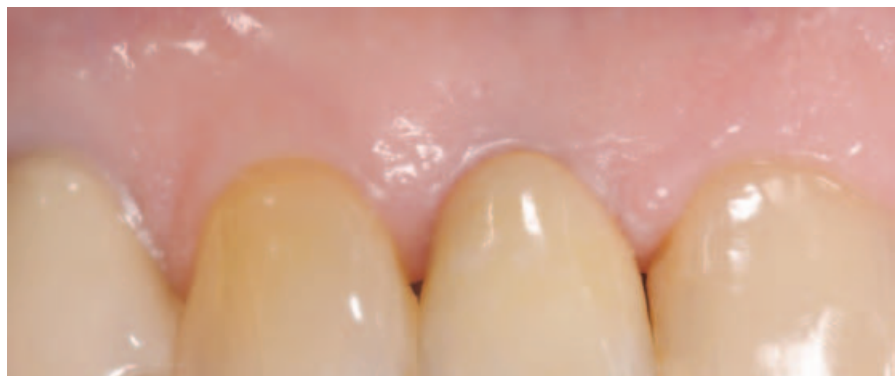In the prosthetic phase, we were very much surprised at the CONELOG® SCREW-LINE implant after we had already had experience with other conical implant/abutment connections. It was many times easier to handle than we were used to in the past, just "CAMLOG-like".

Noteworthy for a conical implant/abutment connection is the fact that the impression is taken on the implant shoulder and thus with no vertical offset.

Of course, the interesting question is whether the bone can stay in place due to the stable conical implant/abutment connection in the clinical load phase. At the present time, we can confirm this without exception in the cases we have observed. The bone level remains stable and speaks for a high-strength implant/abutment connection."



X-ray image directly after prosthetic restoration X-ray image one year after prosthetic restoration



The clinical outcome one year after prosthetic restoration (photos: Cacaci/Ranzelzhofer)

**Dr Martin Hackenberg,
Schömburg**



"As a surgical practice, we cooperate with general dentists in a close network. I am personally a supporter of implant systems with conical implant/abutment connections. I am aware, however, that the precision and tightness in terms of fabrication cannot always be given for all cones as suggested by some manufacturers. However, I believe that a conical connection is more stable and exhibits less micro-movement than a butt-joint connection, particularly when we find a relatively steep taper as is the case with the CONELOG® Implant System with 7.5° cone angle. One more

reason in favor of a conical connection is that exposure can be less invasive. We position all implants slightly subcrestal. Nonetheless, the soft tissues are suppressed and protected when inserting secondary components. For butt-joint connections, the implant shoulder must be fully exposed to ensure that there is no pinching. This aspect of a conical connection is also viewed very positively for the restorative dentist.

The CONELOG® Implant System in particular has advantages, which make clear that CAMLOG has learned from other conical systems. For example,

there is the trick with the disconnecter, that attaches to the abutment by means of milled thread and lifts it out, as well as handling advantages because the healing caps and impression posts sit on the implant shoulder and do not catch hold in the cone, which causes a simple release. The proven simple positioning of the impression posts and abutments using three grooves and cams plays into the hands of the prosthodontist. The feedback from our referring colleagues is correspondingly positive.

Despite all these prosthetic aspects, we have a genuine cone with the advantages of conical implant/abutment connections as mentioned above.

With CAMLOG, there are the excellent, fast delivery service, which we rate as one of the best compared to other companies, fair prices and good feeling of working together with a reputable manufacturer, who provides us, our colleagues in dentistry and our patients with the necessary safety of well-documented and scientifically proven products."

"The CONELOG® Implant System in particular has advantages, which make clear that CAMLOG has learned from other conical systems (...) The feedback of our referring dentists is correspondingly positive."

**Dr Ulrich Konter and
Dr Jan Klenke, Hamburg**



"Our experience with the CONELOG® Implant System is very good, on par with the CAMLOG® Implant System in the clinical outcome. The CONELOG® SCREW-LINE positioned slightly subcrestal offers advantages in many cases. If the contour of the alveolar ridge is sloped with higher approximal bone level, it can be set more favorably biologically: approximal under bone level and buccal at bone level. This 'bone level' positioning creates more space vertically for shaping an emergence profile similar to nature. The integrated platform switching and cervically narrow abutments offer advantages. There is more space for soft tissue between implants, and the CONELOG® SCREW-LINE implants can be placed more precisely prosthetically because the biologically necessary distances between implants may be somewhat smaller. When exposed again, less bone must be exposed circularly on the implant shoulder than with the CAMLOG® implant. In addition, we find there to be somewhat less pressure on the soft tissue when screwing in the Esthomic® abutments after shaping the soft tissue with the wide body healing caps.

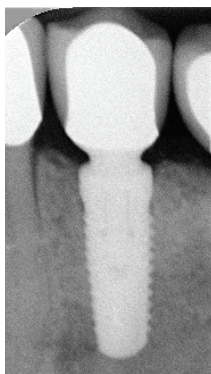
These biological aspects are advantageous for long-term esthetic results.

With the CONELOG® Implant System, the familiar, clearly arranged and color-coded surgery set from the CAMLOG® Implant System as well as the same prosthetic instrumentation are used. Thus, no investment is needed and no change in the surgical and prosthetic process. The proven color-coding for the different diameters and markings for implant alignment remain unchanged. The impression posts and abutments perceivably snap into the three implant grooves. In addition, the prosthetic components are safely guided through the cone.

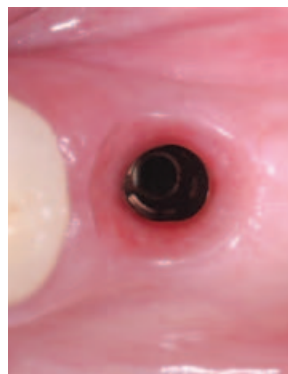
In prosthetics, the corresponding system components are available for all treatment forms. The titanium bases are suitable for fabricating individual zirconium oxide abutments in a CAD/CAM process. In addition, we often use them as bases for screw-retained, esthetic and high-quality temporary solutions."

"Our experience with the CONELOG® Implant System is very good, on par with the CAMLOG® Implant System in the clinical outcome. The CONELOG® SCREW-LINE positioned slightly subcrestal offers advantages in many cases."

(Photos: Konter/Klenke)



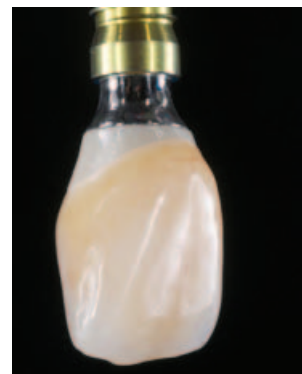Slightly subcrestal CONELOG® SCREW-LINE implant



Soft-tissue cuff around a CONELOG® SCREW-LINE implant



Screw-retained long-term temporary restoration



Esthetic zirconium oxide restoration on a CONELOG® titanium base CAD/CAM

Dr Markus Schlee,
Forchheim



"Always when a new product comes on the market, the question arises as to whether it meets the high expectations and provides the user with added value. In the case of the CONELOG® Implant System, we were involved in the development and part of a clinical multicenter study from early on in the trials. We were able to contribute our experience.

The relationship to the CAMLOG® Implant System is clearly reflected in the design and handling of the CONELOG® connection. In particular, the initial crestal remodeling appears to be minimal here. One can discuss the reason for that. The evidence is weak and what is happening at the crown margin is multifactorial. I am convinced myself that an implant with stable conical inner configuration and platform switching favors stability. We even measure a degree of thickening of the soft tissue without augmentation."

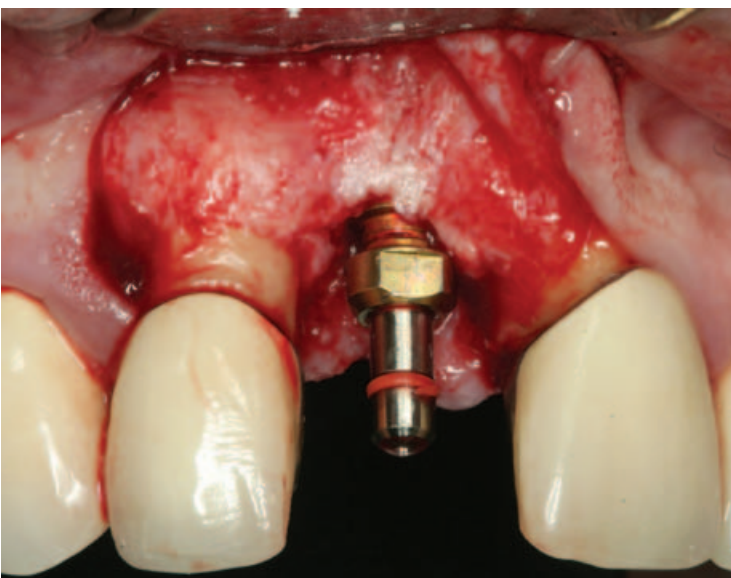
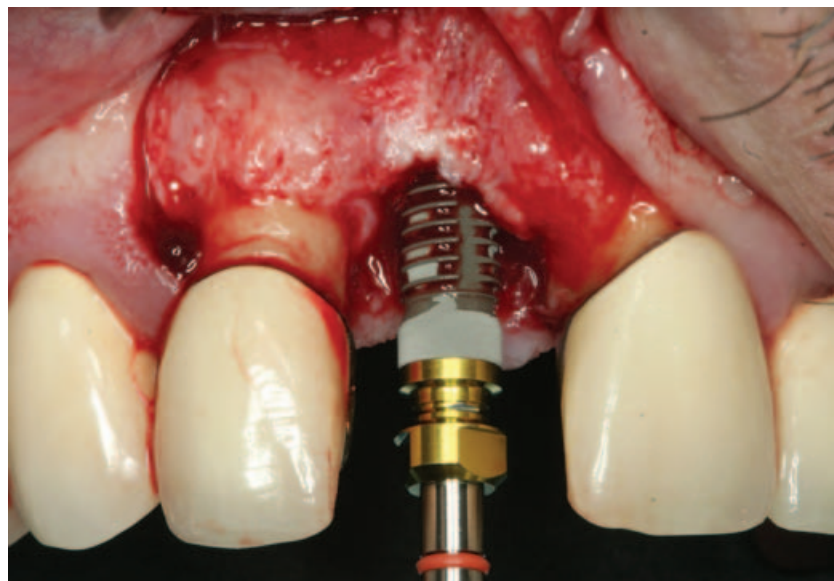
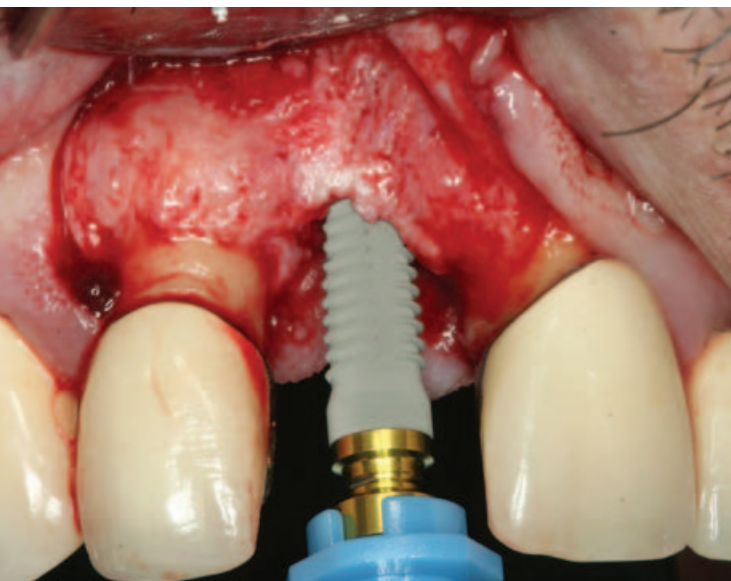
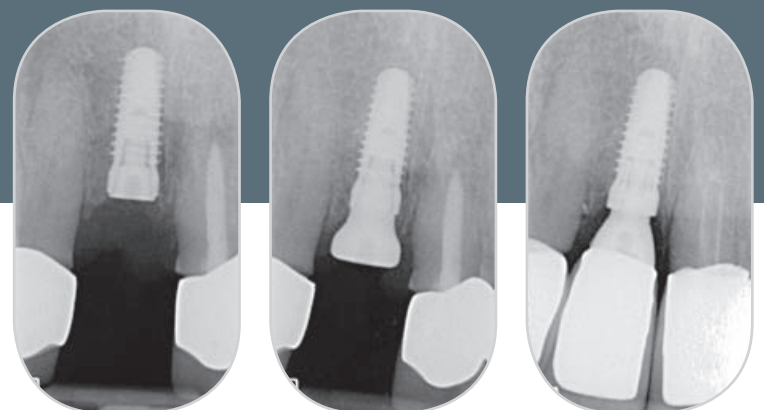


Photo sequence of an anterior tooth reconstruction using a CONELOG® SCREW-LINE implant (photos: Schlee)

"(...) the relationship to the CAMLOG® Implant System is clearly reflected in the CONELOG® connection. In particular, the initial crestal remodeling appears to be minimal here (...) I am convinced myself that an implant with stable conical inner configuration and platform switching favors stability."





MODELING AIDS FOR THE CAMLOG® AND CONELOG® TITANIUM BASES CAD/CAM



Insertable modeling aids for the CAMLOG® titanium base CAD/CAM and the CONELOG® titanium base CAD/CAM are available, now.

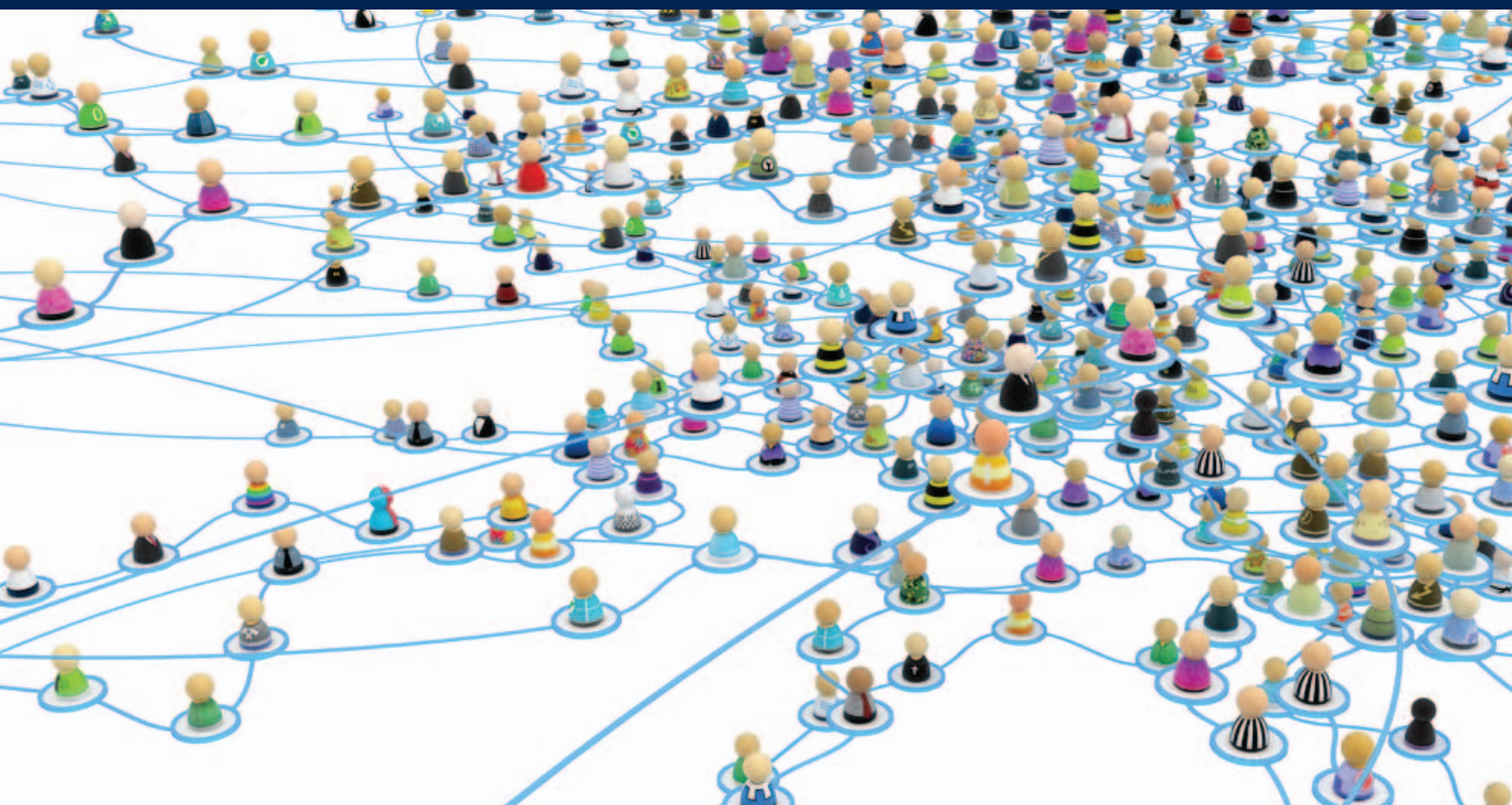
The modeling aid is a tool for the simplified fabrication of mesostructures and crown frameworks on the CAMLOG® or CONELOG® titanium base CAD/CAM. A wax-up is created from an adhesive wax or plastic construction, that can be digitally scanned and imported into dental CAD software as a three-dimensional data record for further processing. Alternatively, casting technique can be used to transfer the wax-up to cast metal abutments or molding techniques to transfer the wax-up to pressed oxide ceramic abutments.

Modeling aids are non-sterile, burn residue free, can be shortened individually and are available color-coded by implant diameter. Together with the system-related scanbodies and bonding aids, CAMLOG rounds off the product portfolio with the modeling aids for fabrication of individual hybrid abutments with the titanium base CAD/CAM.

All advantages at a glance:

- ✓ Easy fabrication of a wax-up and a cast or pressed abutment on the CAMLOG® or CONELOG® titanium base CAD/CAM
- ✓ Inner design takes the optimal bonding gap into account for titanium base CAD/CAM for casting or pressing techniques
- ✓ Extended design of the cervical edge and retention allow for good modeling
- ✓ Self-retaining on the titanium base CAD/CAM
- ✓ Clearly identifiable and perceptible antirotational mechanism for the titanium base CAD/CAM





JOIN THE CAMLOG COMMUNITY ONLINE



CamlogConnect, the website where CAMLOG users can ask questions and learn about CAMLOG products and their application, has enjoyed ever more popularity since its launch in January 2012. Numerous CAMLOG users have already registered and make extensive use of the offering on this successful Internet platform: by CAMLOG users, for CAMLOG users.


The community has rapidly grown since CamlogConnect was launched. More than 1,300 CAMLOG users from 35 countries have already registered on CamlogConnect and regularly use the website as an information and educational medium. CamlogConnect participation in the 4th ICC in Lucerne in May was a true catalyst in introducing the user portal to the world. Many of the congress guests took the opportunity to personally meet the founder of CamlogConnect, Dr Peter Hunt. The CamlogConnect team was ready to introduce the new online platform and to help guests register for the site at the booth in the Congress Center.

Advantages of online communities

Experienced dentists, surgeons and dental technicians, as well as beginners and students use the wide-ranging CamlogConnect site free of charge for professional exchange and targeted training. Especially popular are the videos of live procedures and case reports in which CAMLOG users document their treatment cases and demonstrate their approach. More than half of all users view the videos and presentations. Users are also looking for the tutorials in which Dr Peter Hunt vividly describes the application and uses of the CAMLOG® implants and instruments. The advantages of Internet-based interactive continuing education are obvious:

- No practice downtimes, self-determined time management.
- Virtually no cost because there are no travel costs for continuing education in one's own practice or at home.
- Increase in the competence of all practice staff through joint training and with the dental laboratory. This strengthens the sense of community and improves collaboration.
- Access to a worldwide network of experts and colleagues, with whom you can discuss your own practice-relevant questions.





The uncomplicated and direct exchange with experts, who are confronted daily with the same or similar issues and diagnoses, is one of the special advantages of online communities.

Exchange in a networked community facilitates work

Dr Peter Hunt, who has used CAMLOG implants in his practice in Philadelphia for many years, founded the user-oriented CamlogConnect platform with the goal of encouraging and expanding exchange between CAMLOG fans. CamlogConnect follows the approach of "by CAMLOG users, for CAMLOG users". The forum makes this hands-on exchange possible over all distances. Members ask questions about their own current treatment cases and mutually support and advise each other in treatment planning. And it does not have to be just about knowledge transfer. Communities also offer excellent opportunities to make new contacts and make your own expertise and that of the team known in professional circles and to attract new partners for collaboration. CamlogConnect offers comprehensive support, e.g., in the editorial process

and in the translation of texts, as well as in preparation of the submitted image material.

The knowledge of many is greater than the knowledge of one – using the knowledge of the community

The opportunity for professional exchange is usually limited for individual practitioners in particular. By registering on www.camlogconnect.com, such "lone warriors" gain immediate access free of charge to all information and training opportunities and access to a global professional network in implant dentistry. A tip: If you want to include your practice or laboratory team, you should create a common practice or laboratory account with a password for anyone involved. Get online regularly, watch the videos and read the case reports. After reading the diagnosis, ask yourself, "How would I plan this treatment?" Then explore the chosen course of treatment. Would your solution have been similar? Or, would you have gone a different direction? Discuss the suggested treatments with your team. Use the illustrative material

and tutorials to regularly refresh your and your team's knowledge, to train new employees and to promote the skills of your team. Ask medical, technical or product-specific questions in the forum and share your knowledge with other members of the CAMLOG community. Make a name for yourself in your area of expertise and introduce your own treatment cases. Document a complete treatment case together with your dental technician. The CamlogConnect Team is happy to offer advice and support. We look forward to reading something from you soon!

Learn, share & enjoy!!

camlogconnect
By Camlog Users – For Camlog Users