

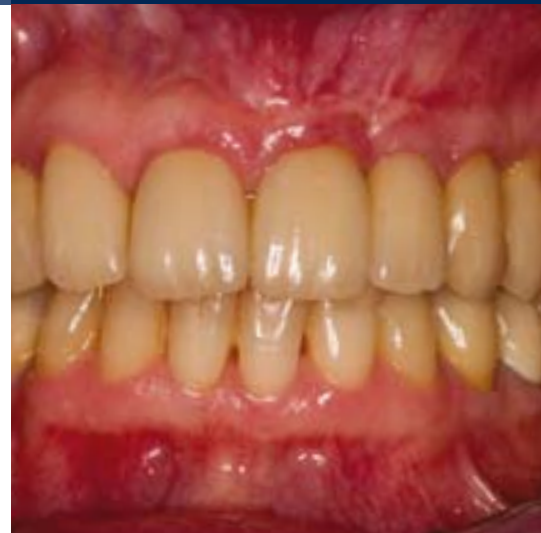THE ESTHETIC ZONE

REHABILITATION OF AN EDENTULOUS SPACE IN AN UPPER JAW FRONT WITH PRONOUNCED TRANSVERSAL ATROPHY OF THE ALVEOLAR PROCESS USING SINGLE CROWNS ON CAMLOG® IMPLANTS

a perfect fit™



Dr Karl-Ludwig Ackermann, Rainer Nagel DDS
Filderstadt, Germany



Dr Karl-Ludwig Ackermann is an oral surgeon and has been engaged in the field of oromaxillofacial implant dentistry since 1980. He is a recognized specialist in periodontics of the EDA (European Dental Association) and practices together with Dr Axel Kirsch in Filderstadt, Germany, where his comprehensive clinical knowledge contributed to the development of the CAMLOG® Implant System.

His primary areas of practice are oral rehabilitation, periodontics, preprosthetic surgery and implant dentistry. Dr Ackermann is a member of the executive board of the German Implantology Society (DGI) and associate lecturer at the Academy for Practice and Science (APW) within the German Society of Dental and Oral Medicine (DGZMK). He is engaged at various universities as a visiting professor or lecturer both domestically and abroad. Dr Ackermann is an author of international publications and known internationally as a consultant.

Rainer Nagel DDS studied at the University of Kiel, Germany (exams 1985). 1983–1985 part time employment at the Heinrich-Hammer-Institut, Kiel. 1985 assistant in the prosthetic department (Prof KH Körber). 1986/87 training assistant at the practice Drs Kirsch/Ackermann, Filderstadt, Germany. 1987 establishment of his own practice in Bremen, Germany. Since 1985, a freelancer in the areas of documentation, lecture support, and data processing. Author in the field of implant dentistry and of application manuals.

IMPLANTS USED

Tooth	18	17	16	15	14	13	12	11	21	22	23	24	25	26	27	28
Impl. type									SL	SL	SL					
Impl. length									13	13	13					
Impl. Ø									4.3	3.8	3.8					
Impl. surface									PP	PP	PP					

Impl. type: ROOT-LINE (RL) / SCREW-LINE (SL) Impl. surface: Promote (P) / Promote Plus (PP)

PROSTHETICS

- standard
 - platform switching
 - removable
 - fixed
 - crown
 - bridge
 - cement-retained
 - screw-retained
 - partially edentulous
 - edentulous
 - other
-
- Universal abutment
 - Esthomic® abutment
 - Telescope abutment
 - Gold-plastic abutment
 - Ceramic abutment
 - Individual zirconium abutment on titanium base
 - PEEK abutment
 - Logfit® abutment
 - Locator® abutment
 - Ball abutment
 - Bar abutment
 - Vario SR abutment
 - other

INFORMATION ABOUT PATIENT AND TREATMENT

The 61-year-old patient introduced herself to the practice with the desire for a rehabilitation. Her case history showed multiple apicectomies to 21 until loss. The teeth in the maxilla and mandible posterior area had been treated with crowns and bridges. All crowns showed protruding crown margins with corresponding periodontal consequences. The patient requested cost-effective, uncomplicated rehabilitation if possible. Because augmentation was required for a periodontal implant-supported restoration, the patient was fully informed about the course of the therapy and the treatment duration.

The hard- and soft-tissue situation presented itself as follows: The edentulous areas were moderately reduced vertically, the transversal reduction was moderate, significant in area 21. To design an adequate implant bed, a mixed method was selected: in area 21, a vestibular block augmentation and in areas 22–23, interposition of a bone block after bone splitting. In addition, a connective tissue graft was inserted in the vestibule.

Initial situation

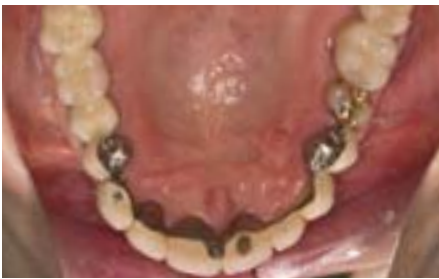

Fig. 1: Occlusal view of the maxilla. All anterior teeth are crowned or replaced by bridge members. The appliance is divided by a "stress breaker" attachment at 11/21.

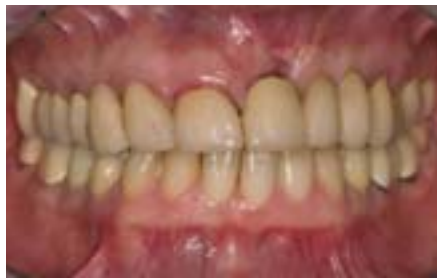

Fig. 2: Frontal view. The transversal atrophy is clearly to see in area 21–23. The mucogingival line is distorted.

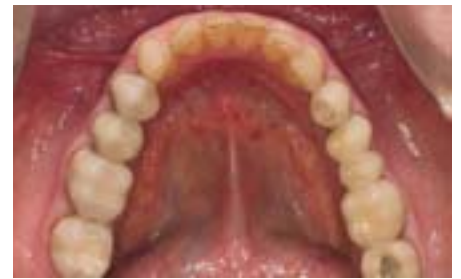

Fig. 3: Occlusal view of the mandible.

Therapeutic discussion

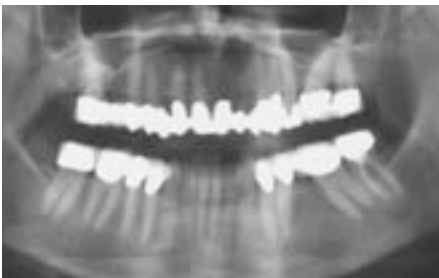

Fig. 4: Orthopantomogram of the initial situation. The periodontal reductions of the alveolar processes can be clearly identified.

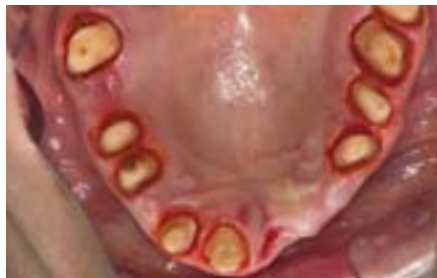

Fig. 5: Initial clinical situation in the maxilla. The transversal retraction in area 21 is clearly to see.

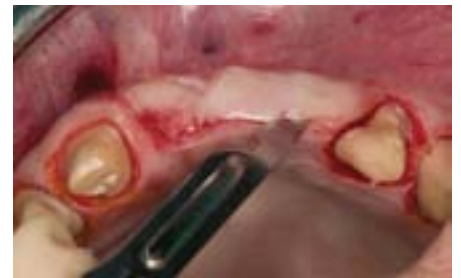

Fig. 6: The incision line was first made from the alveolar ridge as a mucosal flap well into the vestibule. The papilla on 11 was left.

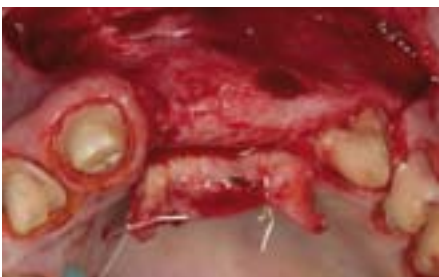

Fig. 7: In area 21, the periosteum was elevated vestibularly to receive a bone block. For a better overview, a narrow mucosal flap was lifted palatally.

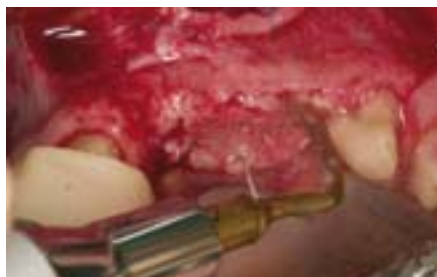

Fig. 8: A piezotome was used to split the bone in area 22–23.

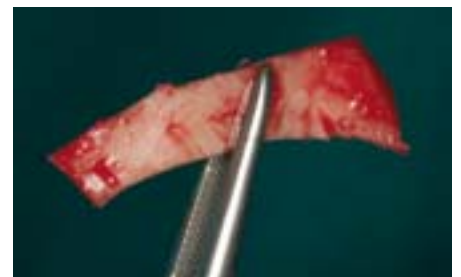

Fig. 9: Monocortical bone graft from the right retromolar area of the mandible.

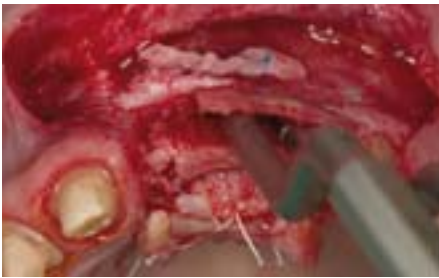

Fig. 10: The area of the bone splitting was carefully widened with a chisel.

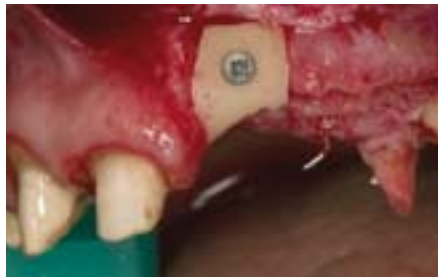

Fig. 11: First, an MCBB onlay was used to carefully augment area 21.

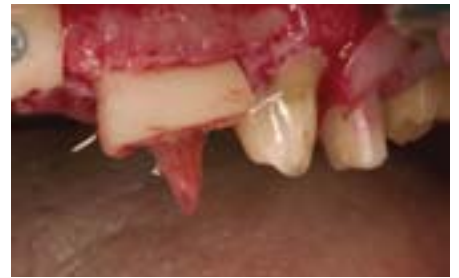

Fig. 12: A bone wedge was tapped into the split area.

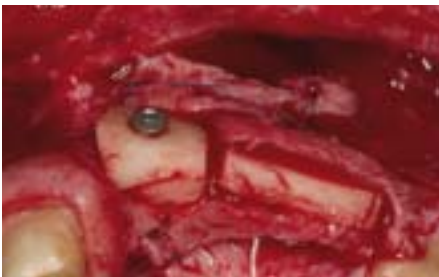

Fig. 13: Occlusal view of the area of the augmentation. The transversal gain is clearly visible.

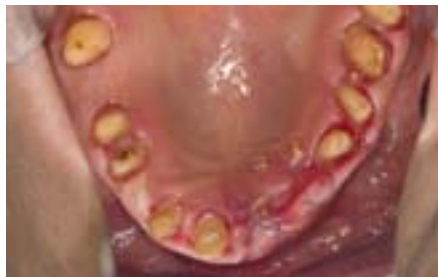

Fig. 14: Condition one week postoperatively at suture removal.

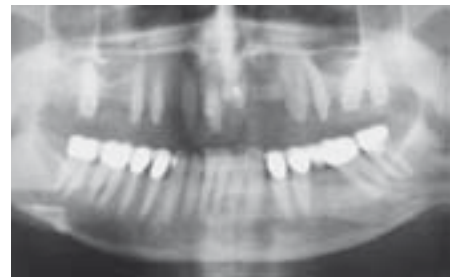

Fig. 15: Postoperative orthopantomogram. The augmentations are clearly visible.

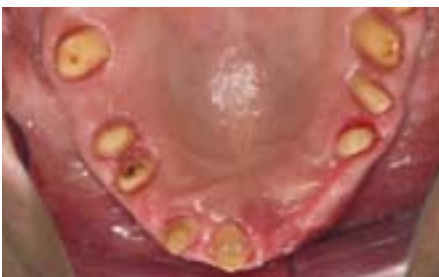

Fig. 16: Condition three weeks postoperatively when inserting the therapeutic intermediate dental prosthesis.

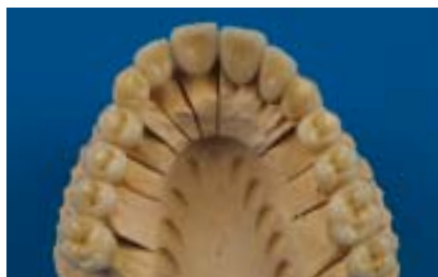

Fig. 17: Laboratory-fabricated therapeutic intermediate dental prosthesis for stabilization of the occlusion and healing of the soft tissue.

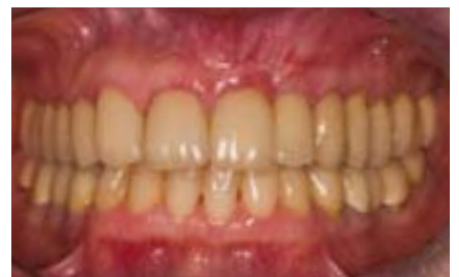

Fig. 18: Frontal view.

Implantation

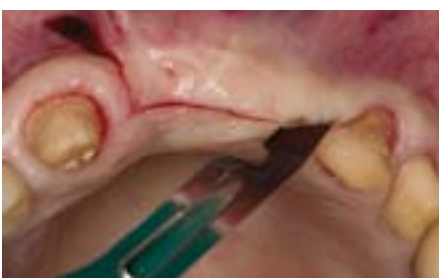

Fig. 19: Implantation took place three months after augmentation. A split-thickness preparation along the original incision lines was selected as the flap design.

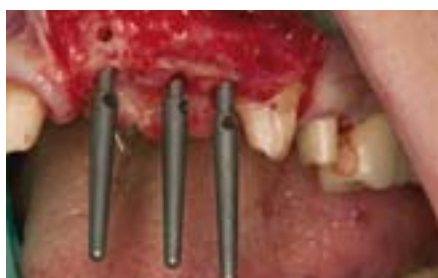

Fig. 20: With the help of a transfer template, the implant positions were determined three-dimensionally and checked using paralleling pins.

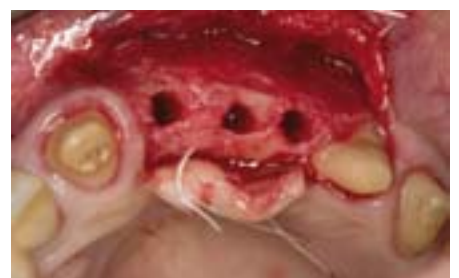

Fig. 21: Protocol-compliant preparation until the planned implant diameter was reached.

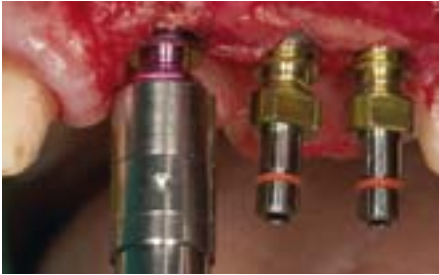

Fig. 22: The implants were placed using the cardanic driver. Thread tapping was not required with D2/D3 bones.

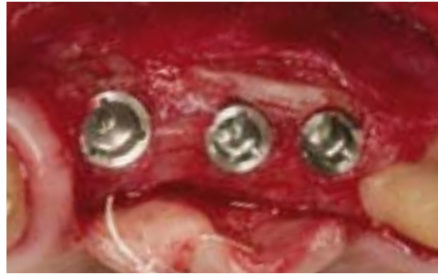

Fig. 23: After removing the insertion posts, the implant-internal threads were cleaned. The vestibular positioning of one groove is clearly to see.

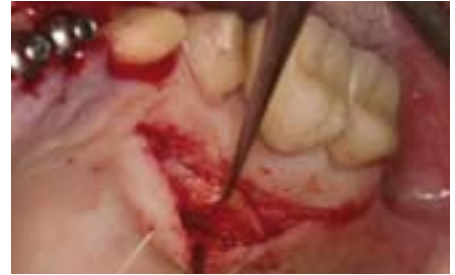

Fig. 24: Removal of a free connective tissue graft from the right palate.

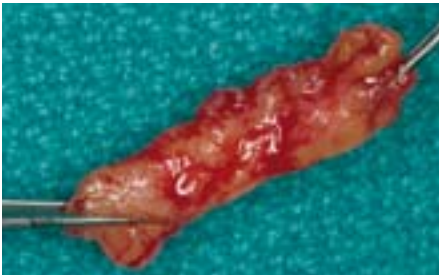

Fig. 25: Free connective tissue graft.

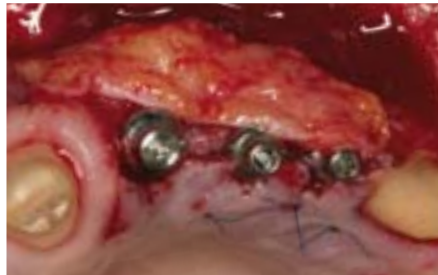

Fig. 26: To improve the soft-tissue contour and thickness, a transplant was fixed vestibularly with resorbable sutures.

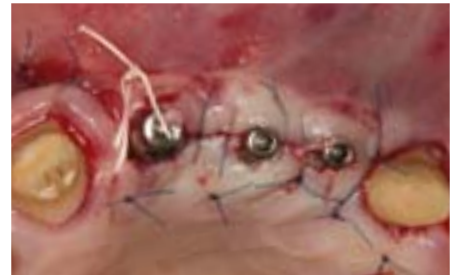

Fig. 27: A multi-layer closure completed the intervention.

Fabrication of the prosthesis

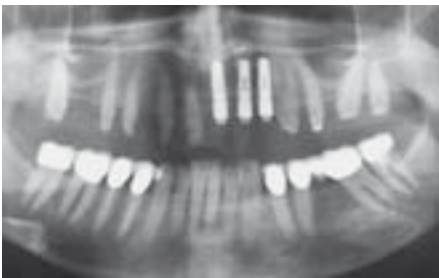

Fig. 28: Control orthopantomogram after implantation.

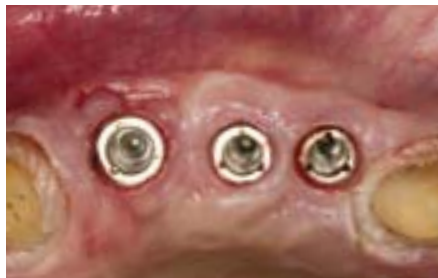

Fig. 29: After about a three-month healing period, the impression was taken for the final restoration.

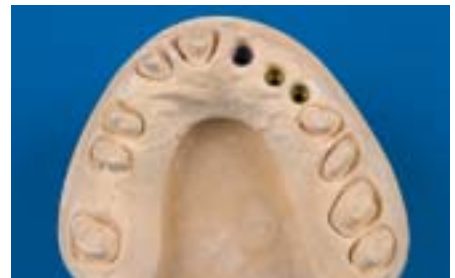

Fig. 30: Master cast.

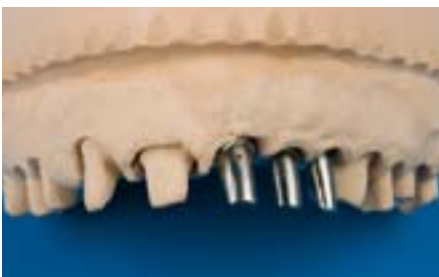

Fig. 31: Customized universal abutments.

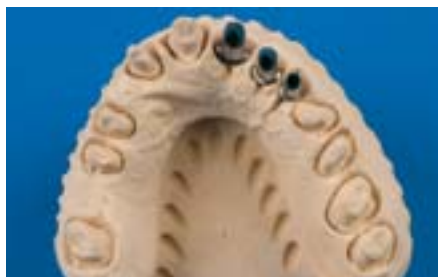

Fig. 32: Occlusal view.

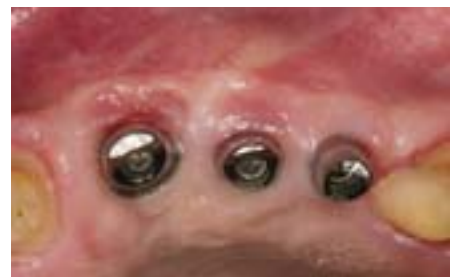

Fig. 33: Intraoral control of the abutments, particularly the position of the shoulder.

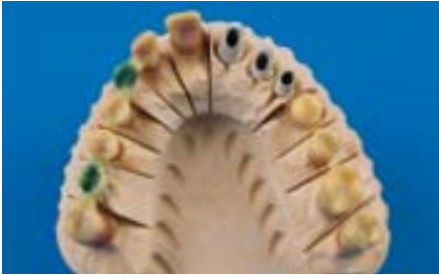


Fig. 34: Before a wax-up of the crown frameworks, the abutments were made opaque to prevent the titanium from showing through.

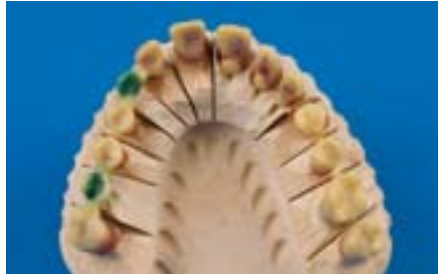

Fig. 35: Fully waxed-up crown and bridge frameworks.

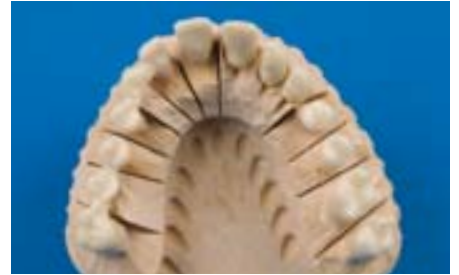

Fig. 36: Implementation in zirconium (LAVA).

Insertion

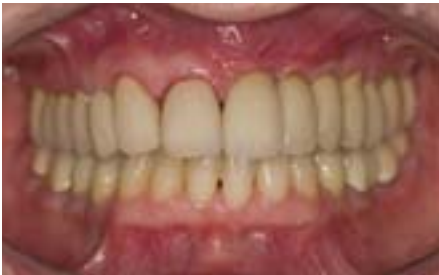

Fig. 37: First bake try-in for final control of occlusion, form, color and esthetics.

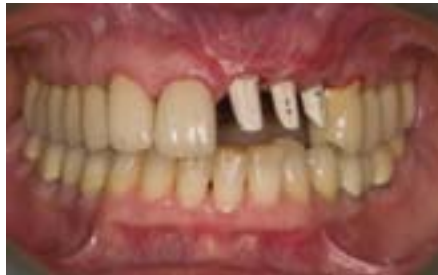

Fig. 38: For final insertion, the cleaned implants were filled with a disinfectant gel. The abutments were then inserted and the abutment screws tightened according to protocol.

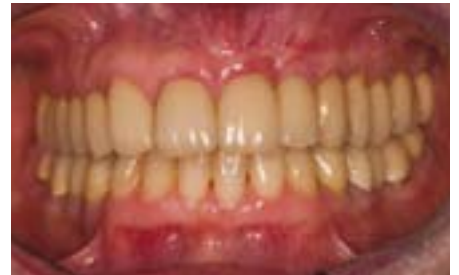

Fig. 39: Front view of the restoration.

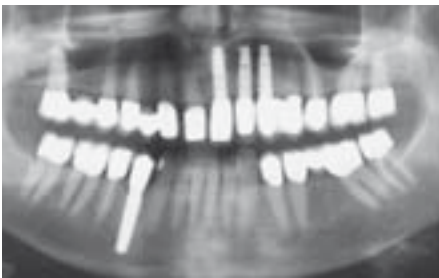


Fig. 40: Control orthopantomogram after insertion of the prosthesis.

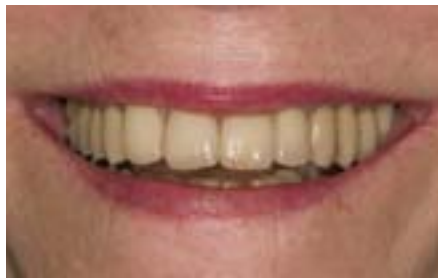

Fig. 41: View of the lips.

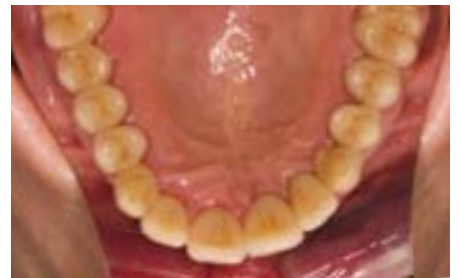

Fig. 42: Occlusal view (mirror) of the restoration.

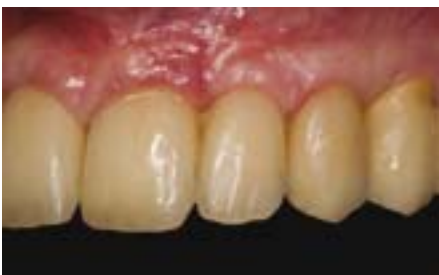

Fig. 43: Detailed image of the implant crowns.

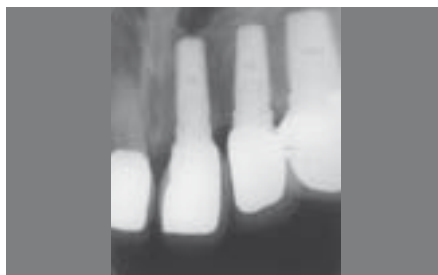


Fig. 44: Dental x-ray to assess bone height.

CONCLUSIONS

Comparison of the initial situation with the treatment result shows significant improvement of the intraoral esthetics and harmony. The patient was treated in several stages and the "backward planning" principle was strictly adhered to.

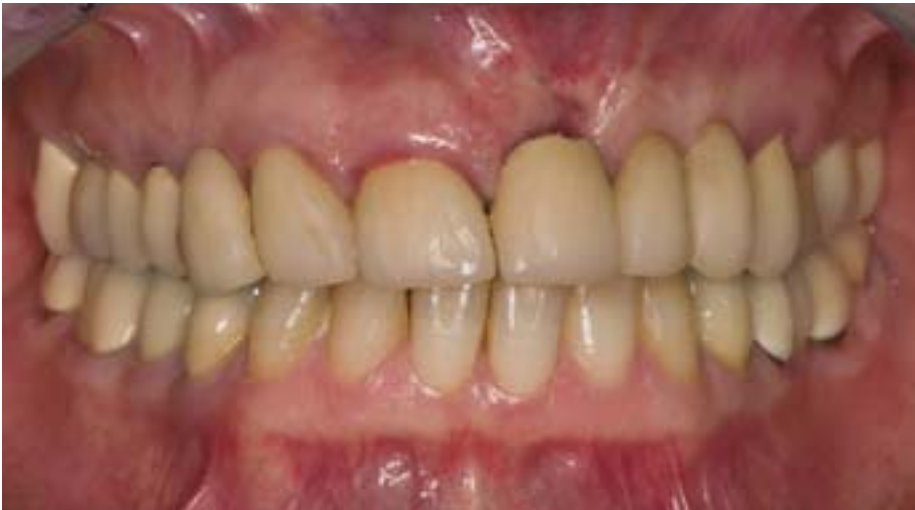Particularly noteworthy is the combined augmentation technique. Because bone splitting was not possible in area 21 due to severe transversal atrophy, a bone block was attached. A bone wedge was placed temporarily more distally after bone splitting. This procedure required a special flap design. In the area of the support, the periosteum was separated (mucoperiosteal flap) and in the area of the interposition, the periosteum was left (split-thickness flap).

The distorted mucogingival line was corrected with the implantation, supported by inserting a connective tissue graft.

Adequate healing periods between treatment phases were required. Healing and maturation of the soft tissue was ensured by a therapeutic intermediate dental prosthesis.

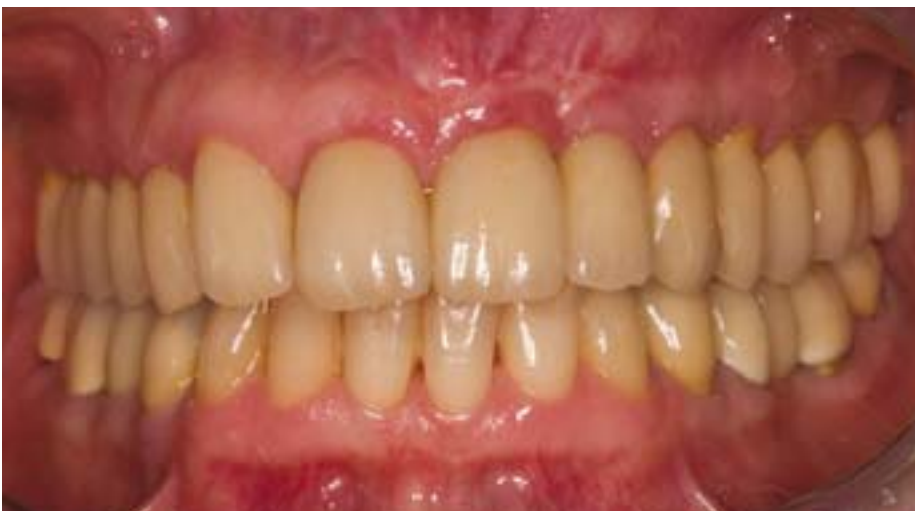The single-crown restoration made physiological loading of the implant site possible and thus long-term stability of the hard- and soft-tissue situation.

Initial situation



Front view. The transversal atrophy is clearly to see in area 21–23. The mucogingival line is distorted.
(OPG initial findings, see Fig. 4)

Final restoration



Front view of the restoration.
(OPG after insertion of the prosthesis, see Fig. 40)

CONTACT

Dr Karl-Ludwig Ackermann

Talstrasse 23

D-70794 Filderstadt

Tel: +49 711 70881 66 (office)

Email: kl.ackermann@kirschackermann.de

HEADQUARTERS

CAMLOG Biotechnologies AG | Margarethenstrasse 38 | CH-4053 Basel | Switzerland
Phone +41 61 565 41 00 | Fax +41 61 565 41 01 | info@camlog.com | www.camlog.com

camlog