

REPLACEMENT OF A SINGLE FRONT TOOTH

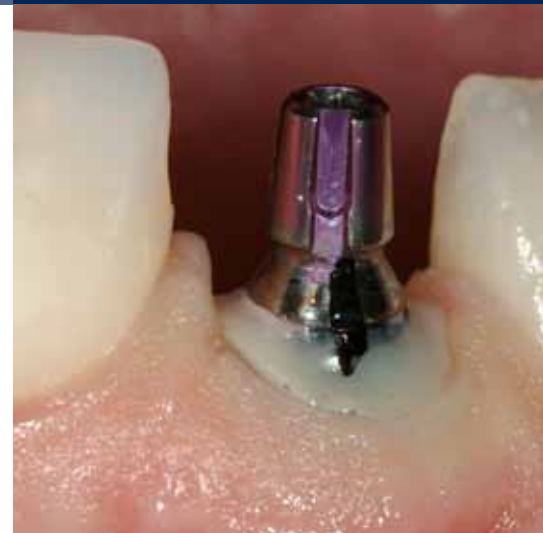SURGICAL PROCEDURE AND THREE-YEAR RESULTS

a perfect fit™



Dr Peter Randelzhofer
Munich, Germany

Dr Peter Randelzhofer studied dentistry in Munich, Germany, and received his training in prosthetics and implant dentistry at the university of Freiburg, Germany. In 2001, he became assistant director at the centre of implants and periodontology in Amstelveen (NL), (director Dr Gert de Lange). In 2002, he received his certification as an implantologist from the NvOI (Dutch Association for Oral Implantology). From 2005–2009, he worked in the Centre for Implantology and Periodontology, a private practice in Amstelveen, together with Dr de Lange and Dr Sipos. In 2009, he founded the Group Practice for Implantology and Periodontology in Munich, Germany, together with Dr Claudio Cacaci. Dr Randelzhofer is author of numerous publications and he is an internationally renowned speaker. He is active as a trainer and teacher at various institutions in the Netherlands and Germany, and he is a member of several national and international study groups.



IMPLANTS USED

Tooth	18	17	16	15	14	13	12	11	21	22	23	24	25	26	27	28
Implant type								SL								
Implant length								13.0								
Implant Ø								4.3								
Implant surface								PP								

Tooth	48	47	46	45	44	43	42	41	31	32	33	34	35	36	37	38
Implant type																
Implant length																
Implant Ø																
Implant surface																

Implant type: ROOT-LINE (RL) / SCREW-LINE (SL) Implant surface: Promote® (P) / Promote® Plus (PP)

PROSTHETICS

- standard
 - platform switching
 - removable
 - fixed
 - crown
 - bridge
 - cement-retained
 - screw-retained
 - partially edentulous
 - fully edentulous
 - other
-
- Universal abutment
 - Esthomic® abutment
 - Telescope abutment
 - Gold-plastic abutment
 - Ceramic abutment
 - Custom zirconium on titanium base
 - PEEK abutment
 - Logfit® abutment
 - Locator® abutment
 - Ball abutment
 - Bar abutment
 - Vario SR abutment
 - other

INFORMATION ON PATIENT AND TREATMENT

At the age of 14, the 42-year-old female patient, had experienced a trauma at tooth 11 leading to luxation and tooth mobility. An endodontic treatment had been carried out in order to esthetically correct a discoloration of that tooth, that had begun 15 years previous to that intervention. About 10 years after that endodontic treatment, an apex resection had been necessary to handle a periapical infection.

Because of pulsating pain and the previous endodontic treatment, the tooth was considered as hopeless with regard to an optimal long-term outcome and was planned for extraction.

The X-ray examination confirmed a chronic infection around the apex. The soft tissue was intact with a satisfactory attachment level to the neighboring

teeth. The quality of the rather thick gingiva was good. Caused by the incision for the apex resection, the scar tissue at the junction of the keratinized and non-keratinized gingiva appeared esthetically unpleasant. Tooth 21 was filled with a 4-side composite filling at the mesial side.

Since the expectations of the patient regarding the esthetic outcome were very high, we decided for immediate implant placement with a CAMLOG® SCREW-LINE implant after extraction of tooth 11. The soft- and hard-tissue structures were preserved as far as possible. Bone augmentation was planned at the time of implantation to treat the bone defect. The prosthetic treatment was planned to take place 3–6 months post-op, depending on the size of defect.

Initial presentation

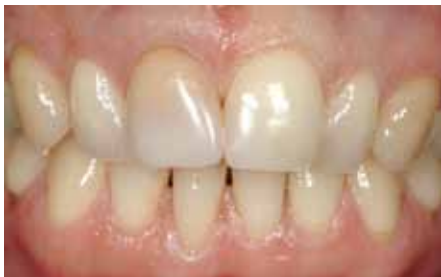

Fig. 1: Patient with high smile line. Incisor 11 discolored and with poor prognosis. Thick gingiva, high scalloped morphology of the interdental papillae.

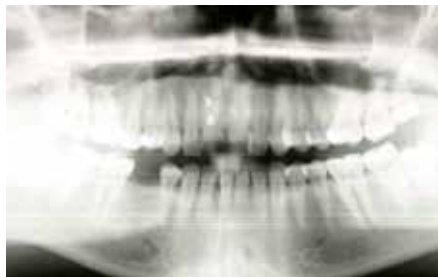

Fig. 2: Radiograph showing endodontic infection of tooth 11.

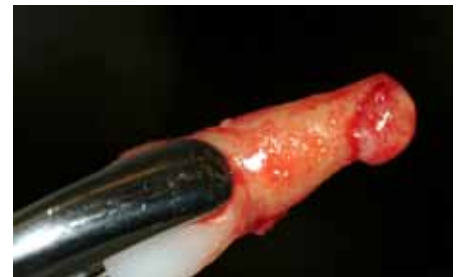

Fig. 3: Careful extraction of tooth 11.

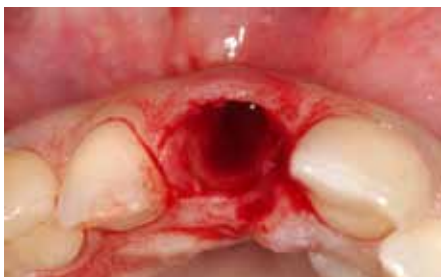

Fig. 4: Good preservation of the marginal hard and soft tissue.

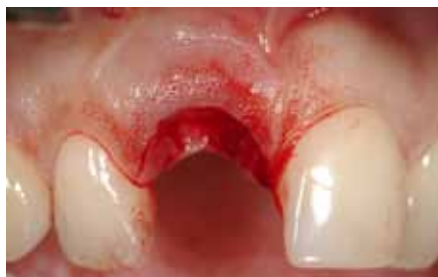

Fig. 5: Intact coronal buccal bone plate. Note the thin interdental papillae. The remaining scar tissue of the former apex resection is clearly visible.

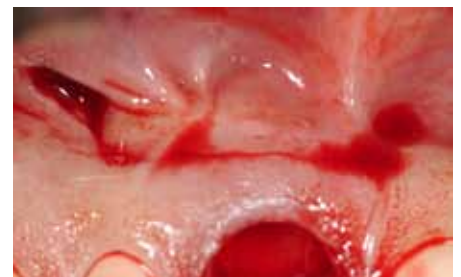

Fig. 6: After a vestibular half-circle incision in the apical part of the keratinized gingiva, a flap is deflected downwards.

Implant placement

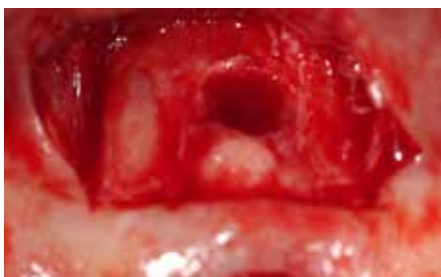

Fig. 7: The apical bone defect becomes visible. Granuloma tissue and endodontic material is accurately removed with the help of a magnifying glass.

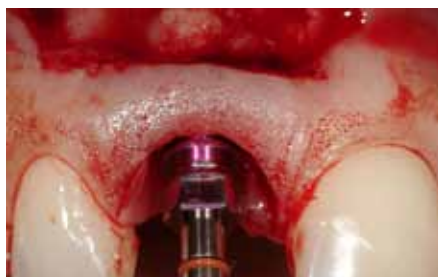

Fig. 8: Three-dimensionally correct 3D placement of a 4.3 mm-diameter implant.

The implant depth is 2 mm below the gingival sulcus and is dependent on the sulcus of tooth 21. To achieve a primary stability of a minimum of 35 Ncm, the final drill was not used to its maximum depth.

Bone augmentation

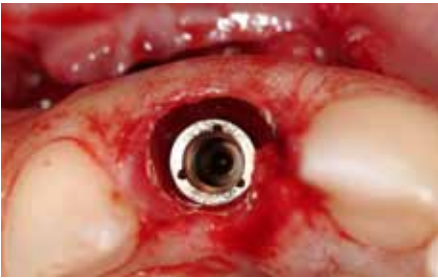

Fig. 9: The implant is inserted with palatinal orientation and a minimum distance of 2 mm to the buccal bone plate in order to prevent its resorption.

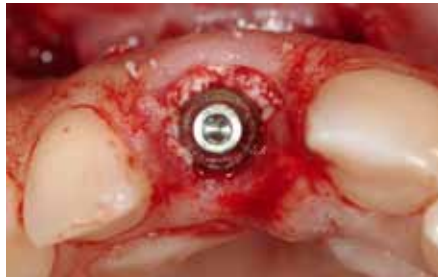

Fig. 10: Augmentation of the remaining spaces between the 4 mm bottleneck healing abutment and the buccal bone plate with Bio-Oss® particles.

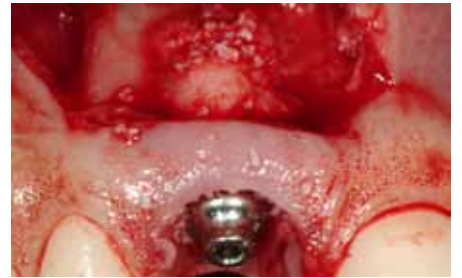

Fig. 11: Additional augmentation of the apical bone plate with grafting material. Use of a membrane is not necessary because of the anatomical shape of the defect.

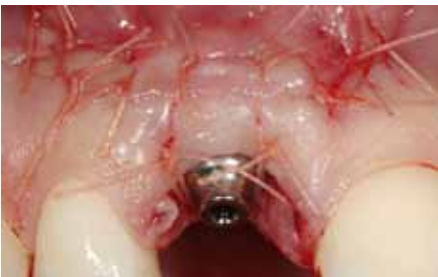

Fig. 12: Primary wound closure with resorbable vicryl sutures 5.0. The apical flap is closed conventionally.

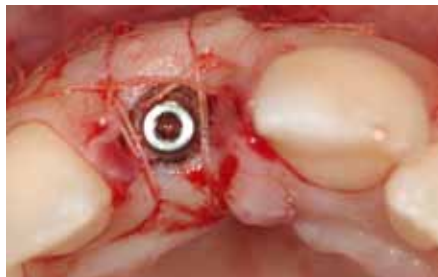

Fig. 13: The bottleneck design of the transmucosal abutment enables a tensionless wound closure.

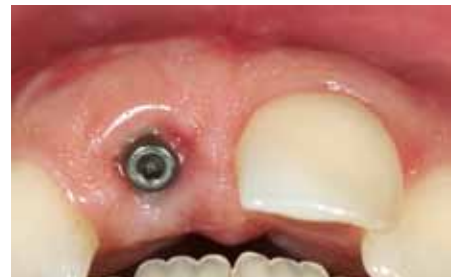

Fig. 14: Four weeks post-op: good soft-tissue healing and gingival adaptation around the bottleneck abutment.

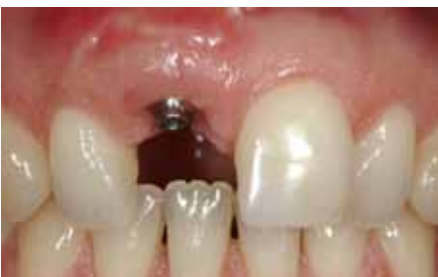

Fig. 15: Stable papillae, nicely preserved soft-tissue volume. The temporary crown is supposed to create the image of a natural sulcus around an implant crown.

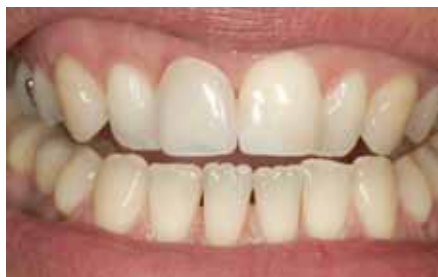

Fig. 16: The removable provisional, used by the patient for the 4-month healing period, shows enough gingival height for a functionally and esthetically acceptable result.

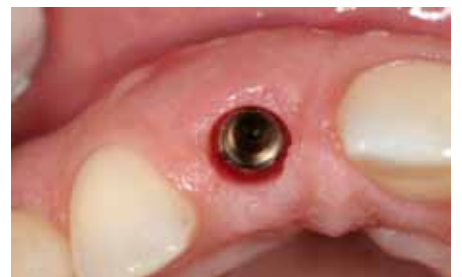

Fig. 17: Nicely healed and healthy soft tissue around a well-integrated implant replacing tooth 11. The absence of scar tissue thanks to the flap design is obvious.

Soft-tissue management

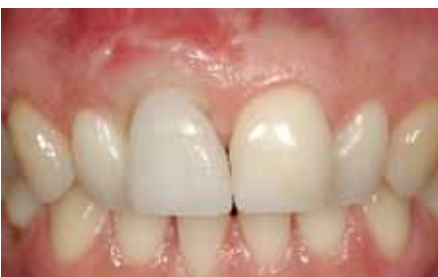

Fig. 18: Placement of a temporary crown with soft-tissue management for a natural looking emergence profile. The submerged part of the occlusal screw-retained crown (concave tulip-like design) supports the subgingival soft tissue.

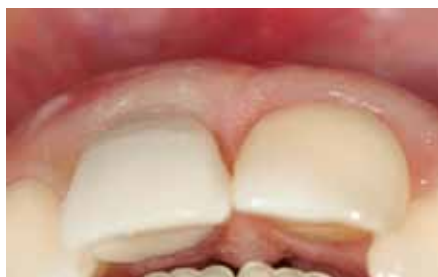

Fig. 19: The screw channel (perforating the labial part of the crown) is covered with a composite inlay. Further apically, the persisting scar tissue can easily be detached from the earlier apex resection.

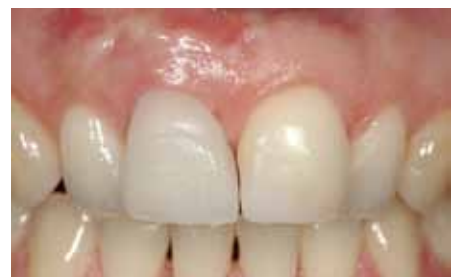

Fig. 20: Natural looking emergence profile. The mesial part needs to be built up a little more.

Impression-taking and prosthetic reconstruction

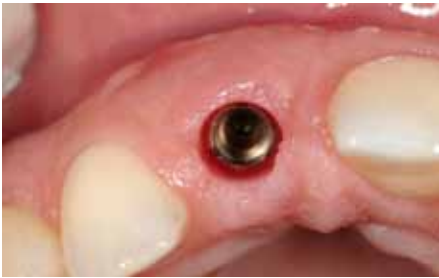

Fig. 21: Clinical situation before impression-taking.

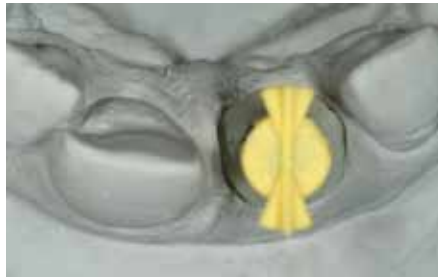


Fig. 22: The ideal emergence profile of the prototype crown is copied with an individual impression post and reproduced onto the master model.



Fig. 23: Individual impression post.

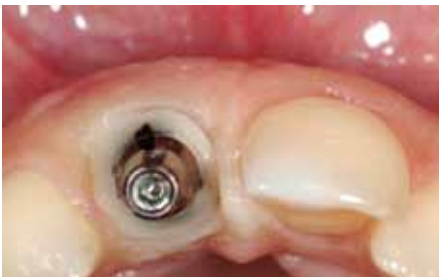

Fig. 24: Individual impression post placed on the implant and the opening of the sulcular structures.

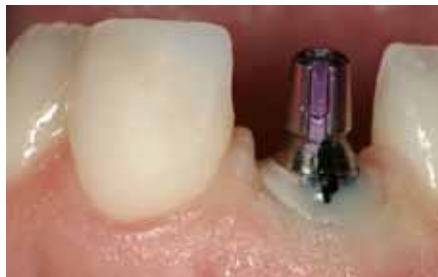

Fig. 25: Lateral view of the implant with impression post.

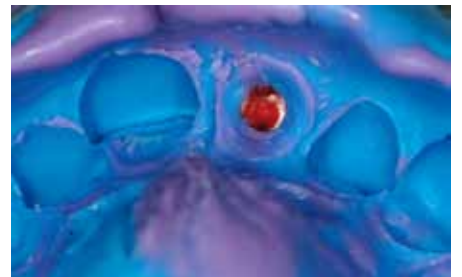

Fig. 26: Impression tray containing the individual information of the crown-gingiva interface.



Fig. 27: Master model with temporary abutment and silicon index showing the preservation of the backward planning information.

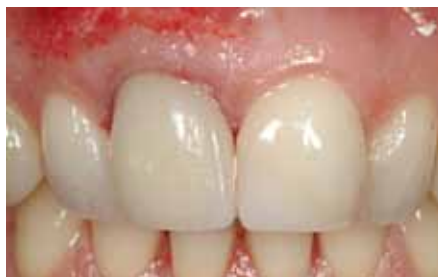

Fig. 28: E-max® crown immediately after definitive placement on individualized ceramic abutment with Panavia® cement. The apical scar tissue was shaped with a diamant drill for a smoother gingival outcome.

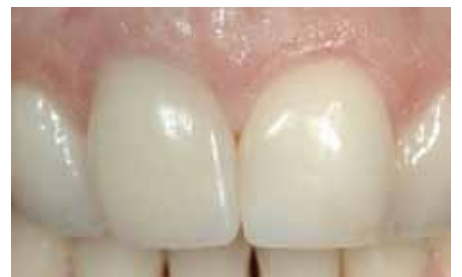

Fig. 29: Final result one year after implant placement. The soft tissue shows a stable and near-perfect interface with the implant crown.

Result after one year

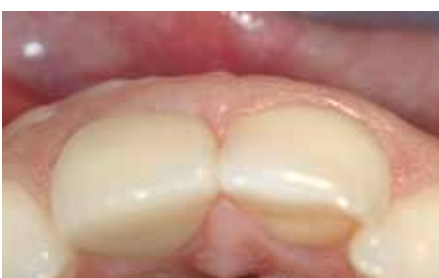

Fig. 30: Optimal tissue contour.

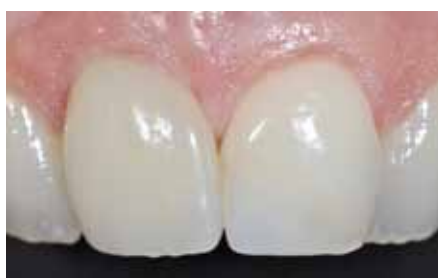

Fig. 31: Stable soft-tissue result showing no resorption at the implant-crown interface or gingival sulcus.

Results after 3 years

CONCLUSIONS

Implant-borne reconstruction of missing front teeth is challenging, especially in fresh extraction sockets. For a functionally and esthetically stable outcome, a sufficient amount and volume of hard- and soft-tissue is needed. Care has to be taken to preserve the previous tissue structures. Vertical and horizontal bone losses taking place after insertion of the implant into the oval environment due to remodeling processes have to be taken into account.

In the present case, the patient had high expectations regarding the esthetic outcome. An alternative treatment of this case would have been a bridge solution combined with augmentation of the pontic area. Such a solution would bear less risks and allow to obtain a more predictable soft-tissue situation. The patient was informed of the risks and alternatives. However, she decided in favor of the implant reconstruction.

We aimed to preserve the soft- and hard-tissue structures to achieve an adequate level of marginal gingiva together with an adequate interdental bone peak. Therefore, we decided for immediate implant placement after extraction of tooth 11, creating optimal soft- and hard-tissue structures around the implant at the time of implant placement. The coronal tissue remained untouched and the crestal aperture was closed with a transmucosal abutment. The flap preparation was performed in the apical region, only. This technique was chosen to provide the best possible interface between crown and gingiva.

We were able to achieve an ideal three-dimensional positioning of the implant and an optimal esthetic result, that was still stable after three years.

Initial situation

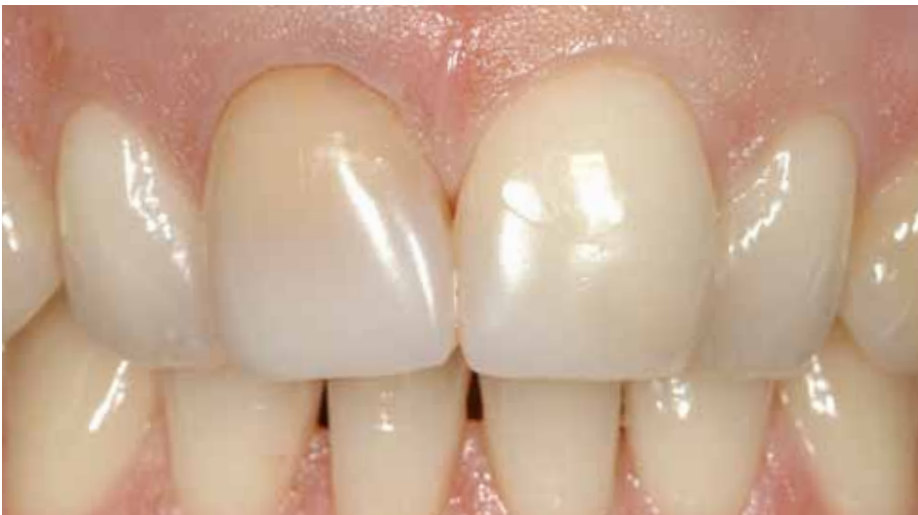

Fig. 32: Initial situation before extraction.

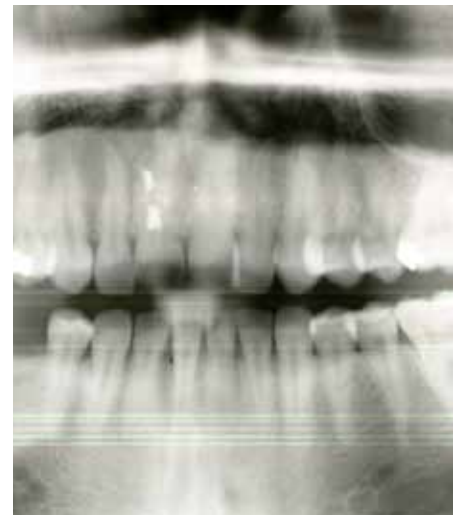

Fig. 33: Initial situation with non preservable tooth 11.

Final restoration

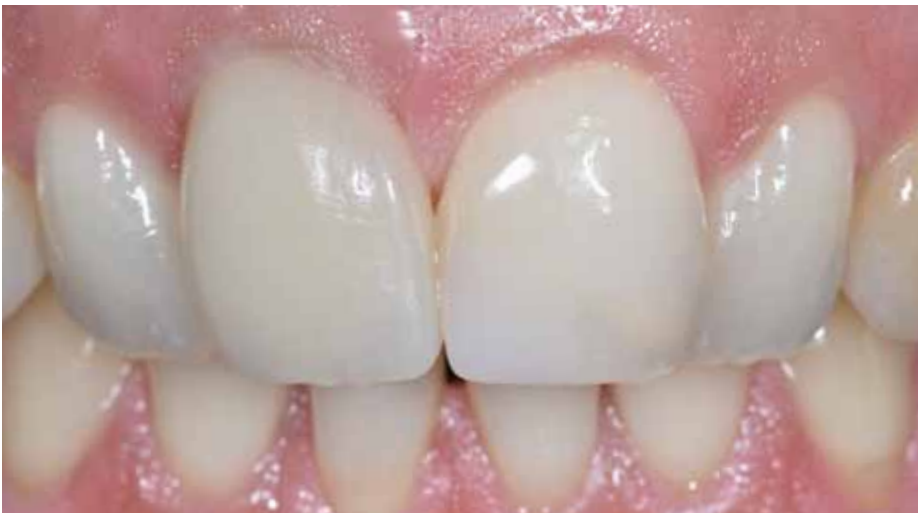

Fig. 34: Clinical situation three years after implantation.

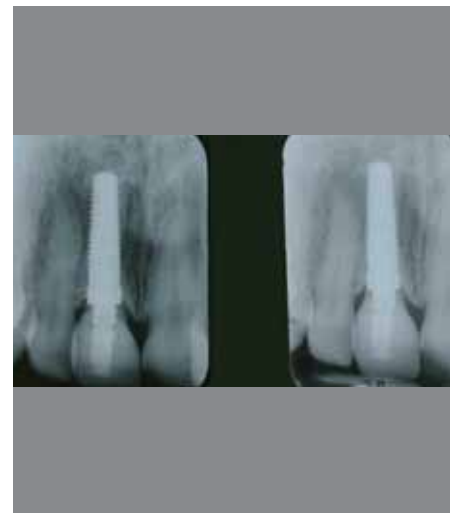

Fig. 35: Final x-ray after one and three years.

REFERENCES

BECKER J, FERRARI D, HERTEN M, KIRSCH A, SCHAER A, SCHWARZ F

Influence of platform switching on crestal bone changes at non-submerged titanium implants: a histomorphometrical study in dogs. *J. Clin Periodontol* **2009**; 36: 532-539

JUNG YC, HAN CH, LEE KW

A 1-year radiographic evaluation of marginal bone around dental implants. *Int J Oral Maxillofac Implants* **1996**; 11: 811-818.

SMITH DE, ZARB GA

Criteria for success of osseointegrated endosseous implants. *J Prosthetic Dent* **1989**; 62: 567-572.

ADELL R, LEKHOLM U, ROCKLER B, BRANEMARK PI

A 15-year study of osseointegrated implants in the treatment of the edentulous jaw. *Int J Oral Surg* **1981**; 10: 387-416

CONTACT

Implantat Competence Centrum in München
Dr. med. dent. Claudio Cacaci & Dr. med. dent. Peter Randelzhofer
Weinstraße 4
D-80333 München
Tel. +49 (0)89 242399111

DENTAL TECHNICIAN

aldente Dentaldesign
Hardi Mink
Schondorferstraße 6
D-70734 Fellbach
Tel. +49 (0)711 5782385

The case was first published in:
Mairoana C., Beretta M. *Manual of Oral Implantology*. Italia Press 2010.
(Reprinted with kind permission of the publisher)

HEADQUARTERS

CAMLOG Biotechnologies AG | Margarethenstrasse 38 | CH-4053 Basel | Switzerland
Tel +41 61 565 41 00 | Fax +41 61 565 41 01 | info@camlog.com | www.camlog.com

camlog