

# MINIMALLY INVASIVE IMMEDIATE IMPLANTATION IN REGION 22 USING A COMBINED SOFT-TISSUE GRAFT

a perfect fit™



Dr Gerhard Iglhaut  
Memmingen, Germany

Dr Iglhaut studied dentistry from 1977 to 1982 at Justus Liebig University in Gießen, Germany. He then spent three years as a research associate in the Department of Oral Surgery at Gießen University under the direction of Prof H. Kirschner and attained the additional designation of an oral surgeon, later of an implantology specialist, German Implantology Society (DGI) and specialist in periodontics, European Dental Association (EDA). He has been in independent practice in Memmingen, Germany since 1987. Dr Iglhaut lectures nationally and internationally in the fields of implant dentistry, periodontics, periodontal plastic surgery and periodontal microsurgery, and is among the faculty of the Academy on Practice and Science (APW)/DGI as part of the curricula implantology, esthetic dentistry and restorative dentistry. He is a member of numerous dental organizations including the American Academy of Esthetic Dentistry, the American Academy of Restorative Dentistry and many others. In 2004, he was elected to the executive board of the DGI and is currently its Vice President. He has been a lecturer at Steinbeis University Berlin since 2005 in cooperation with the DGI for the Master of Science in Implantology course of studies and a lecturer at the University of Göttingen, Germany.

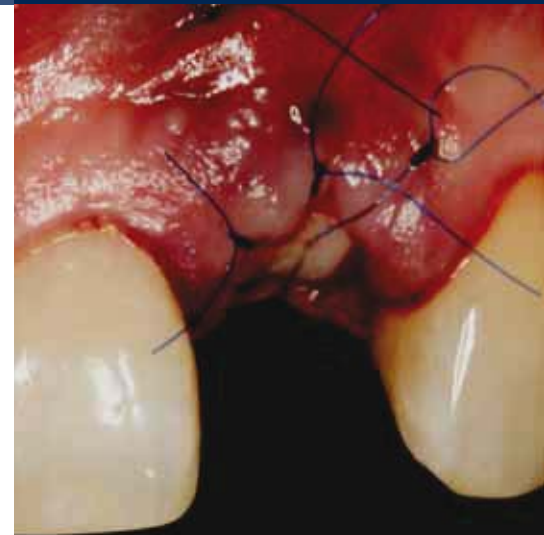
## IMPLANTS USED

| Tooth         | 18 | 17 | 16 | 15 | 14 | 13 | 12 | 11 | 21 | 22   | 23 | 24 | 25 | 26 | 27 | 28 |
|---------------|----|----|----|----|----|----|----|----|----|------|----|----|----|----|----|----|
| Impl. type    |    |    |    |    |    |    |    |    |    | SL   |    |    |    |    |    |    |
| Impl. length  |    |    |    |    |    |    |    |    |    | 13.0 |    |    |    |    |    |    |
| Impl. Ø       |    |    |    |    |    |    |    |    |    | 3.8  |    |    |    |    |    |    |
| Impl. surface |    |    |    |    |    |    |    |    |    | PP   |    |    |    |    |    |    |

| Tooth         | 48 | 47 | 46 | 45 | 44 | 43 | 42 | 41 | 31 | 32 | 33 | 34 | 35 | 36 | 37 | 38 |
|---------------|----|----|----|----|----|----|----|----|----|----|----|----|----|----|----|----|
| Impl. type    |    |    |    |    |    |    |    |    |    |    |    |    |    |    |    |    |
| Impl. length  |    |    |    |    |    |    |    |    |    |    |    |    |    |    |    |    |
| Impl. Ø       |    |    |    |    |    |    |    |    |    |    |    |    |    |    |    |    |
| Impl. surface |    |    |    |    |    |    |    |    |    |    |    |    |    |    |    |    |

Impl. type: ROOT-LINE (RL) / SCREW-LINE (SL) Impl. surface: Promote (P) / Promote Plus (PP)



## PROSTHETICS

- standard
  - platform switching
  - removable
  - fixed
  - crown
  - bridge
  - cement-retained
  - screw-retained
  - partially edentulous
  - edentulous
  - other
- 
- Universal abutment
  - Esthomic® abutment
  - Telescope abutment
  - Gold-plastic abutment
  - Ceramic abutment
  - Individual zirconium abutment on titanium base
  - Logfit® abutment
  - Locator® abutment
  - Ball abutment
  - Bar abutment
  - Vario SR abutment
  - other

## INFORMATION ABOUT PATIENT AND TREATMENT

The generally healthy 38-year-old female patient came to our practice for the first time in February 2007 with a desire for an implant treatment in region 22 (longitudinal root fracture of the tooth). On March 19, 2007 after carefully removing tooth 22, a CAMLOG® SCREW-LINE implant (Ø 3.8 mm, length 13 mm) was immediately implanted with intact buccal wall. In adequate 3D position, a space was made between the buccal implant shoulder and crestal alveolar wall ("jumping distance") of 2 mm and filled with bone substitute material (Geistlich Bio-Oss® small granules). A combined soft-tissue graft taken from the palate was used to close the alveolus while at the same time thickening the vestibular soft tissue. After uneventful

healing, the implant was exposed 4 months later with a roll flap technique and six weeks later, the implant impression taken for the prosthetic restoration. As single-tooth prosthesis, a customized zirconium abutment was attached to the titanium base using the Cerec 3D System and an all-ceramic crown fabricated that was inserted in September 2007. Clinical and radiographic follow-ups over a period of 32 months showed a stable, esthetically pleasing result.

### Initial situation

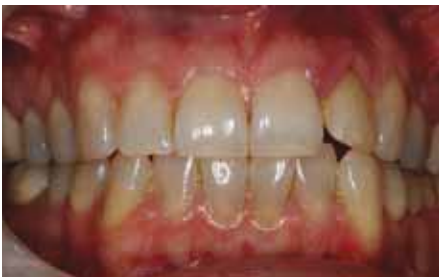

Fig. 1: High smile line.

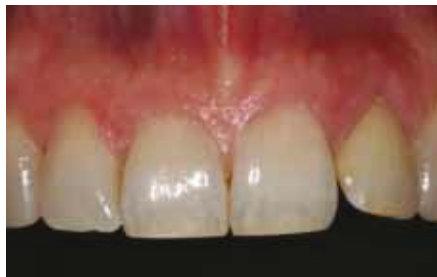

Fig. 2: Photograph of the upper jaw front.

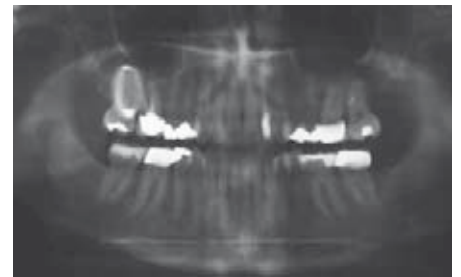


Fig. 3: OPG preimplantation.

### Surgical procedure

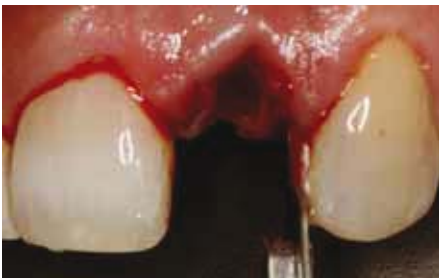

Fig. 4: Gentle removal of the root with 15c blade and periosteum acc. to Schulte.

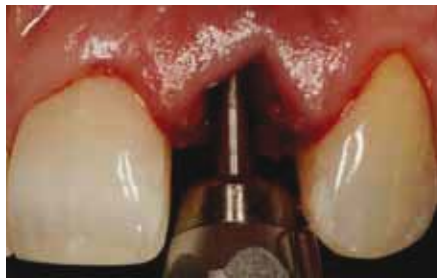

Fig. 5: Preparation of a palatal platform with ball reamer.

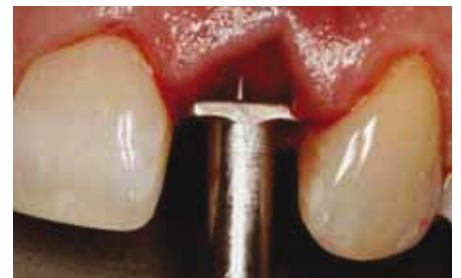

Fig. 6: 3D positioning of the implant.

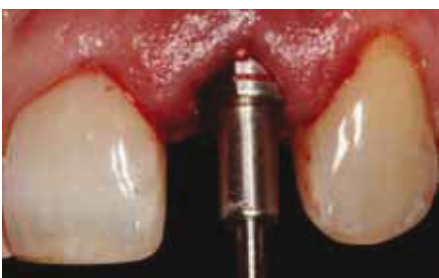

Fig. 7: Setting of the buccal gap ("jumping distance") of 2 mm.

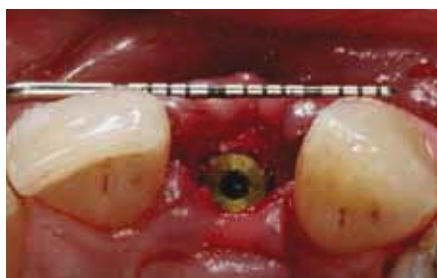

Fig. 8: Correct sagittal position after filling the gap with bovine KEM (Bio-Oss® small granules).

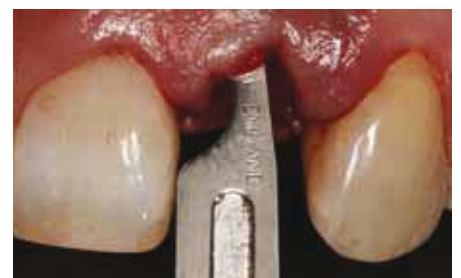

Fig. 9: Suprapariosteal buccal tunnel preparation to receive the connective tissue component of the combined graft.

### Postoperative situation (1 day)

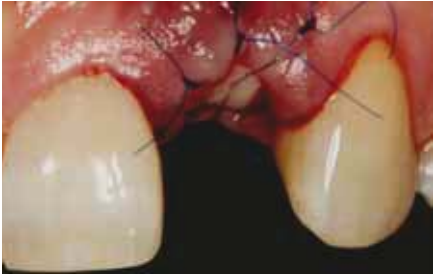

Fig. 10: Condition after alveolar closing with combined graft – vestibular view.

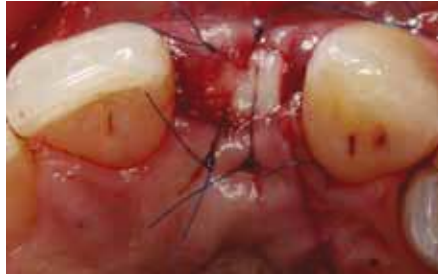

Fig. 11: Palatal view.

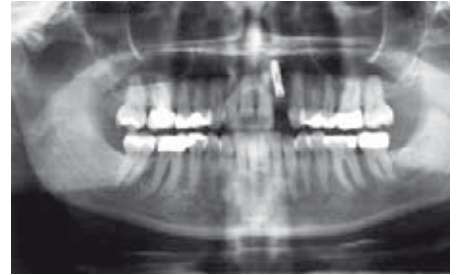

Fig. 12: OPG scan post operative.

### Situation exposure during subgingival healing

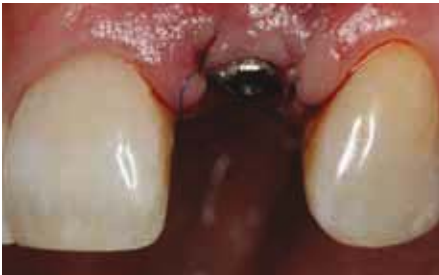

Fig. 13: Condition after exposure with roll flap – vestibular view.

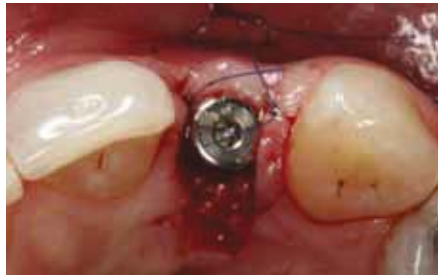

Fig. 14: Palatal view.

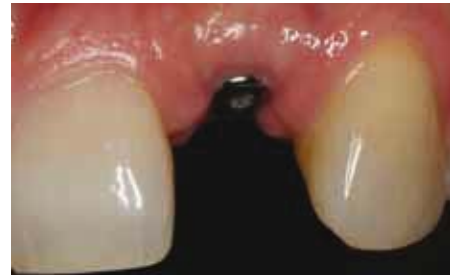

Fig. 15: Situation at impression-taking – vestibular view.

### Impression-taking situation

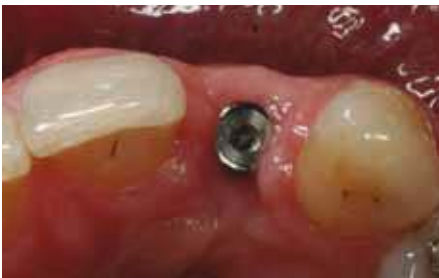

Fig. 16: Palatal view.

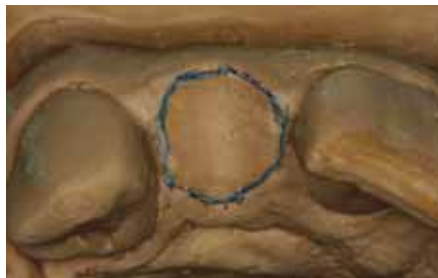


Fig. 17: Depiction of the emergence profile of contralateral tooth 12 after model etching.

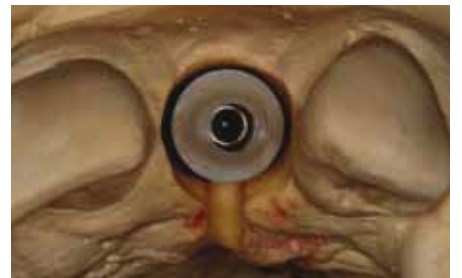

Fig. 18: Palatal view of the customized zirconium abutment, approx. 15–20% reduction of the diameter.

### Prosthetic restoration

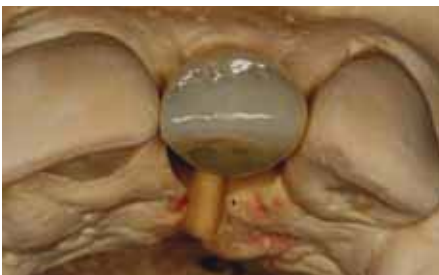

Fig. 19: Palatal view of the all-ceramic crown with zirconium coping (Cerec 3D System).

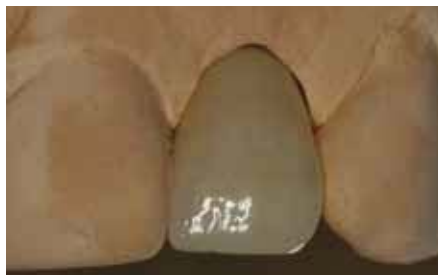

Fig. 20: Vestibular view.

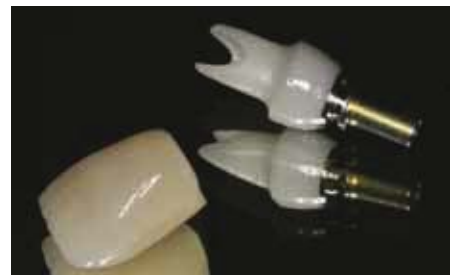

Fig. 21: All-ceramic crown and customized zirconium abutment (Cerec 3D System) on titanium platform.

### Situation insertion of the final restoration

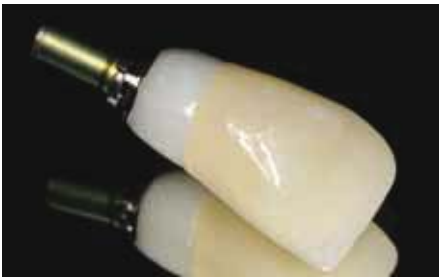

Fig. 22: All-ceramic crown and customized zirconium abutment (Cerec 3D System) on titanium platform.

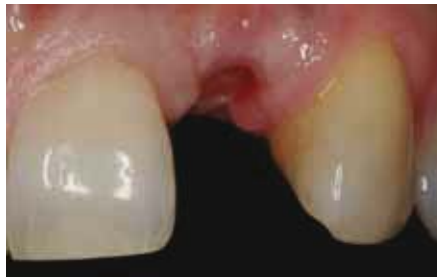

Fig. 23: Vestibular view before insertion of the final restoration.

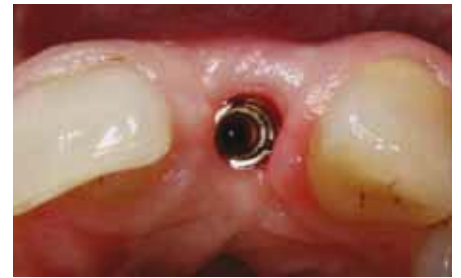

Fig. 24: Palatinal view.

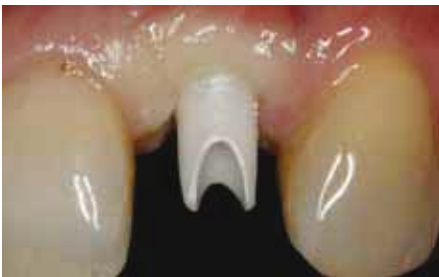

Fig. 25: Condition after insertion of the ceramic abutment – slight anemia of the peri-implant mucosa.

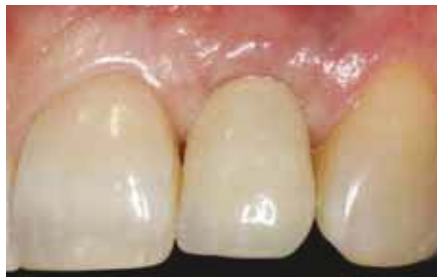

Fig. 26: Clinical condition after insertion of the all-ceramic crown.

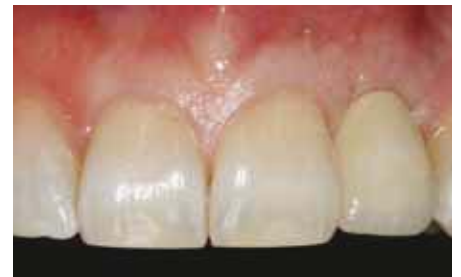

Fig. 27: Upper jaw front after insertion of superstructure 22.

### Situation 6 months after implantation

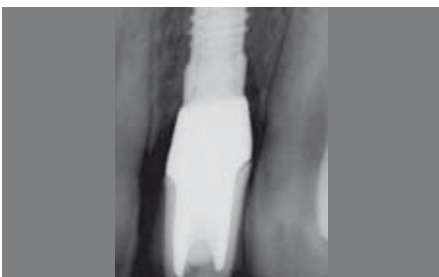

Fig. 28: Radiographic control scan (dental film) after inserting the superstructure.

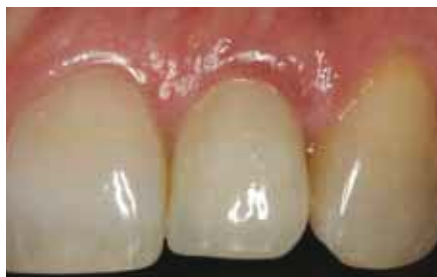

Fig. 29: Clinical condition in region 22, 6 months after final restoration.

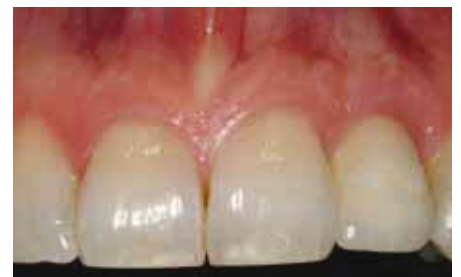

Fig. 30: Photograph of the upper jaw front 6 months after final restoration.

### Situation 32 months after implantation

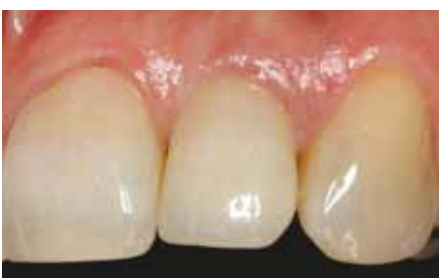

Fig. 31: Clinical condition in region 22, 32 months after final restoration.

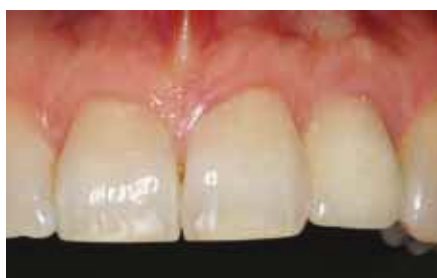

Fig. 32: Photograph of the upper jaw front, 32 months after final restoration.

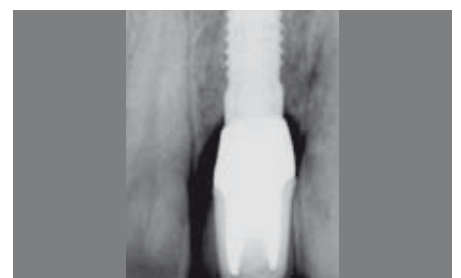

Fig. 33: Radiographic control scan (dental film), 32 months after final restoration.

## CONCLUSIONS

The depicted implantological restoration in the esthetically challenging region represents a minimally invasive procedure of the immediate restoration using combined soft-tissue grafts. The adequate 3D implant position is regarded as an important parameter for the peri-implant tissue retention, by which a 2-mm gap is created between the implant neck and vestibular alveolar wall, that is filled with slowly resorbable bone substitute material for tissue stabilization. The goal is a closed, safe healing and the buildup of approx. 2 mm of peri-implant bone tissue in the implant shoulder

area, which can ensure long-term stable results. The combined soft-tissue grafts are suitable due to their probability of success (approx. 98%) and their capacity to thicken the vestibular mucosa. By exposing the implant with a roll flap technique, further thickening of the soft tissues and thus long-term tissue stability can be achieved. By using an all-ceramic abutment on a titanium base and an all-ceramic crown, the highest standards of esthetics and biocompatibility are met. The follow-ups confirm the stable result satisfying high esthetic standards.

### Initial situation

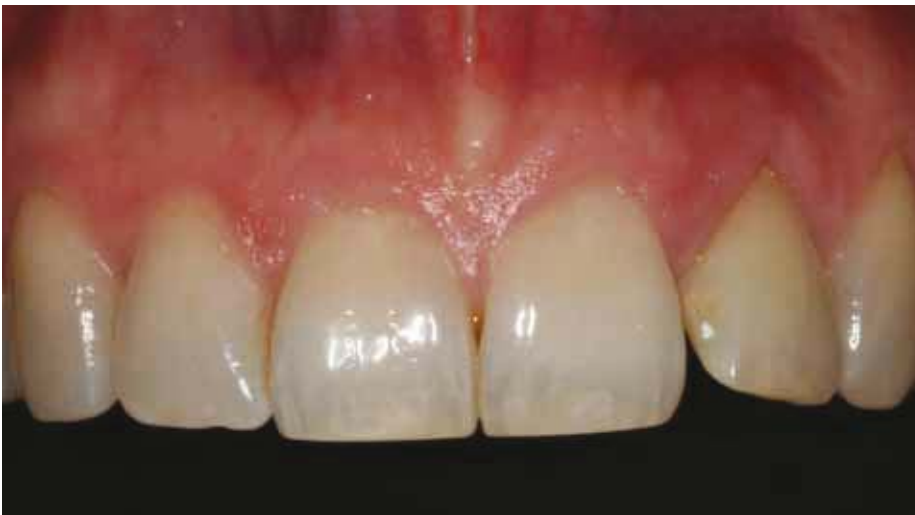

Fig. 34: Photograph of the upper jaw front before implantation.

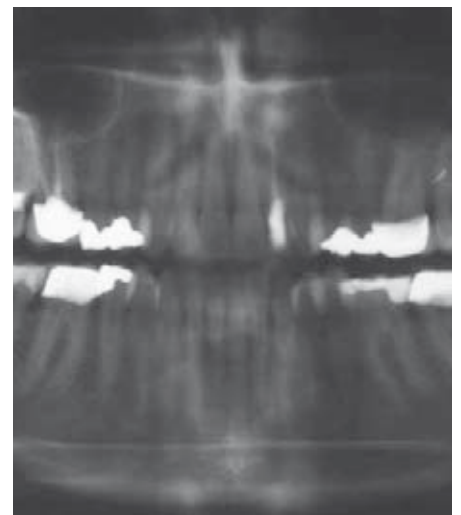

Fig. 35: OPG before implantation.

### Situation 32 months after implantation

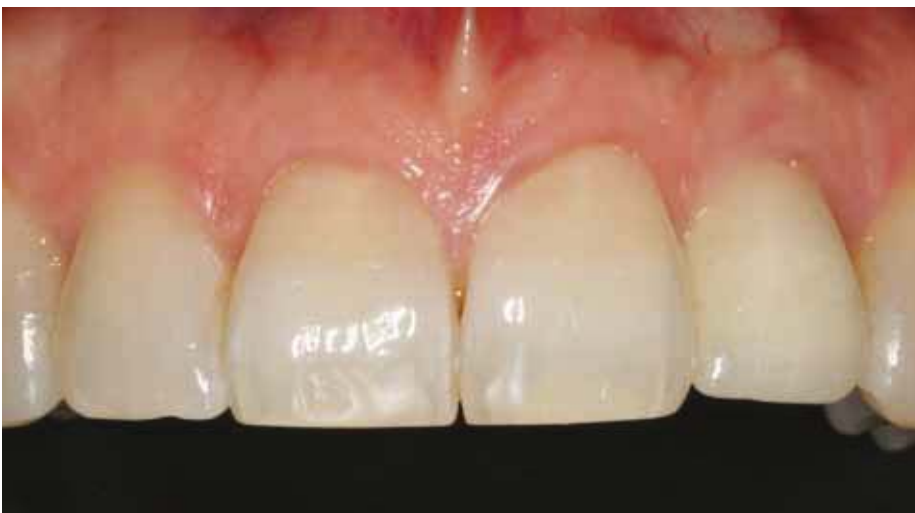

Fig. 36: Upper jaw front view 32 months after final restoration.

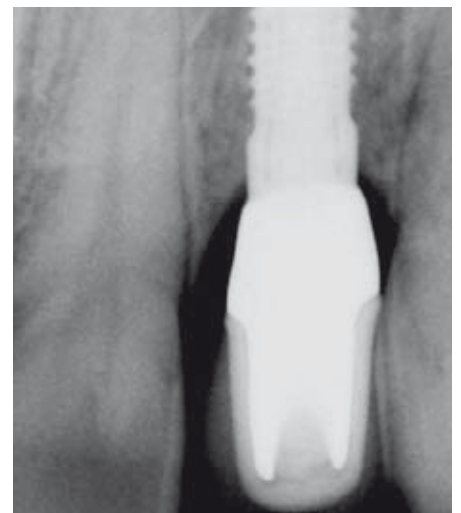


Fig. 37: Radiographic control scan (dental film) 32 months after final restoration.



**SUPPLIER****SURGICAL INSTRUMENT SETS**

KLS Martin, Gebrüder Martin GmbH & Co.KG  
Ludwigstaler Straße 132  
D-78532 Tuttlingen

**BONE SUBSTITUTE MATERIAL GEISTLICH BIO-OSS® SMALL GRANULES**

Geistlich Biomaterials  
Schneidweg 5  
D-76534 Baden-Baden

**EXTRACTION OF AUTOLOGOUS BONE K SYSTEM**

American Dental Systems  
Johann-Sebastian-Bach Straße 42  
D-85591 Vaterstetten

**6-0 SERALENE SUTURE MATERIAL**

Serag-Wiessner  
Zum Kugelfang 8 – 12  
D-95119 Naila

**CEREC 3D SYSTEM**

Sirona  
Fabrikstraße 31  
D-64625 Bensheim

**CONTACT**

Dr. Gerhard Iglhaut  
Bahnhofstr. 20  
D-87700 Memmingen  
Phone: +49 8331 2864  
Fax: +49 8331 4528  
E-mail: [dr.iglhaut@t-online.de](mailto:dr.iglhaut@t-online.de)  
[www.dr-iglhaut-praxis.de](http://www.dr-iglhaut-praxis.de)

**HEADQUARTERS**

CAMLOG Biotechnologies AG | Margarethenstrasse 38 | CH-4053 Basel | Switzerland  
Phone +41 61 565 41 00 | Fax +41 61 565 41 01 | [info@camlog.com](mailto:info@camlog.com) | [www.camlog.com](http://www.camlog.com)

**camlog**