

INTERDISCIPLINARY TREATMENT PLANNING

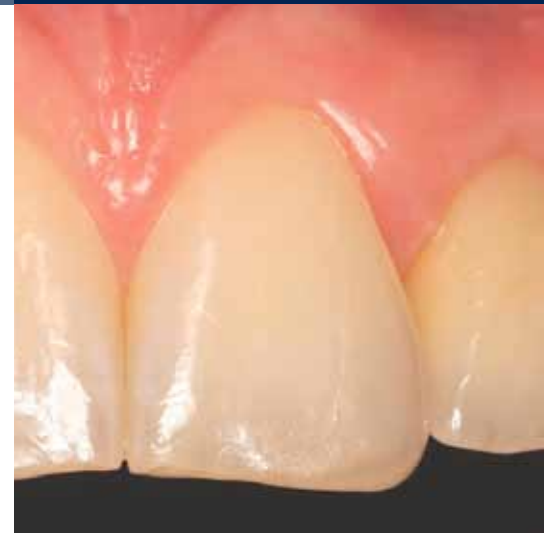SINGLE-TOOTH RESTORATIONS IN THE ESTHETIC ZONE

a perfect fit™



Piero Simeone,
Rome, Italy

Prof Piero Simeone worked as a dental technician under Prof Mashiro Kuwata in Tokyo and in various dental laboratories of national reputation before he graduated at the University of Rome in dentistry. He continued his studies in the department of Prof Mario Martignoni in Rome and at the Kanagawa Dental College, Yokusuka, Japan (Prof Sadao Sato). At the University of Krems in Austria (Prof Rudolf Slavicek), he received his Master of Science in "Function and Dysfunction of the Masticatory System". He continued his education with a postgraduate advanced course in orthodontics in craniofacial dysfunction. Piero Simeone is author of numerous international scientific publications. He is a speaker at numerous congresses and courses in prosthetic dentistry. Today, he has a private practice in Rome and is a visiting professor at the University of Rome in the department of perio prosthetics.



IMPLANTS USED

Tooth	18	17	16	15	14	13	12	11	21	22	23	24	25	26	27	28
Implant type							RL			RL						
Implant length							13.0			9.0						
Implant Ø							4.3			3.8						
Implant surface							P			P						

Tooth	48	47	46	45	44	43	42	41	31	32	33	34	35	36	37	38
Implant type																
Implant length																
Implant Ø																
Implant surface																

Implant type: ROOT-LINE (RL) / SCREW-LINE (SL) Implant surface: Promote (P) / Promote Plus (PP)

PROSTHETICS

- standard
 - platform switching
 - removable
 - fixed
 - crown
 - bridge
 - cement-retained
 - screw-retained
 - partially edentulous
 - fully edentulous
 - other
-
- Universal abutment
 - Esthomic® abutment
 - Telescope abutment
 - Gold-plastic abutment
 - Ceramic abutment
 - Custom zirconia on titanium base
 - PEEK abutment
 - Logfit® abutment
 - Locator® abutment
 - Bar abutment
 - Ball abutment
 - Vario SR abutment
 - other

INFORMATION ON PATIENT AND TREATMENT

The 24-year-old female patient presented with congenitally missing lateral incisors, that had previously been orthodontically treated for a Class II malocclusion. The first examination revealed an inverse position between the upper right canine and first premolar. Additionally, there was a root convergence preventing implant placement in the lateral incisor sites.

Minor orthodontic treatment was necessary to create the space for implant placement. Once the fixtures were inserted and the temporary abutments connected to the implants, the provisionals were relined using an index matrix

taken from the wax-up. From the diagnostic wax-up, it was decided that, in order to attain a satisfying final esthetic outcome, it was necessary to also restore the distal aspect of the central incisors and the right first premolar for anatomical and functional reasons. Finally, after having screwed the abutments on the implants, inducing a torque of 20 Ncm, the metal-ceramic restorations were cemented with temporary cement. The patient was recalled at two, four and 12 weeks for check-ups and every four months for professional hygiene.

Pre-surgical orthodontic phase

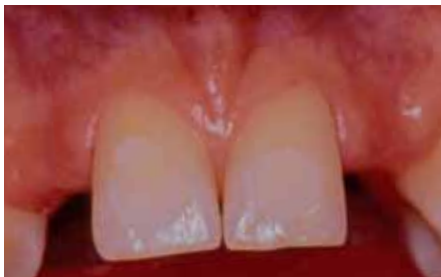

Fig. 1: Clinical view before starting orthodontic treatment.

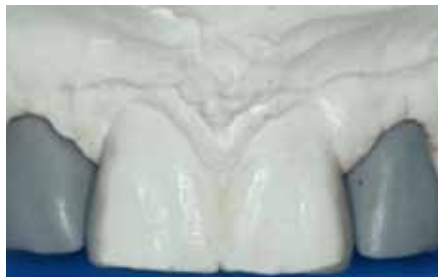

Fig. 2: Wax-up to anatomically plan the case. A wax-up is the quickest and most reliable guide for determining the necessary space.

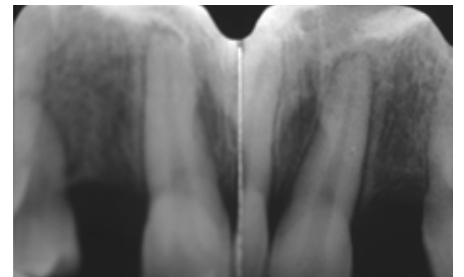


Fig. 3: Initial phase of the orthodontic treatment to create space for the implants. Note the shifting of the incisor roots and the remodeling of the periodontal support.

Implant placement

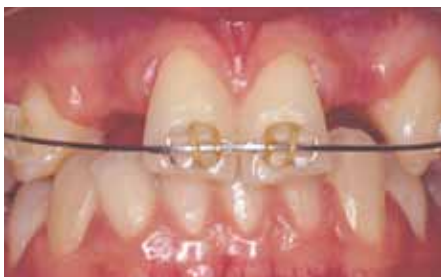

Fig. 4: Pre-surgical view with the root axes relocated mesially.

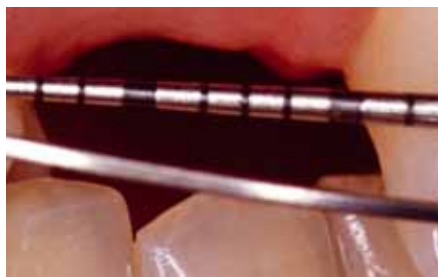

Fig. 5: Clinical evaluation of the mesiodistal space.

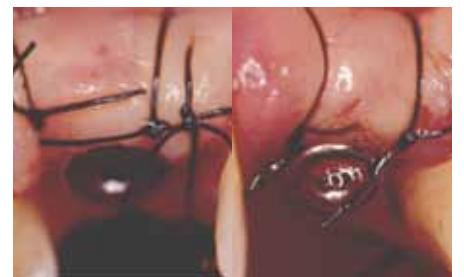

Fig. 6: Implants in place and flaps sutured.

Healing with provisionals

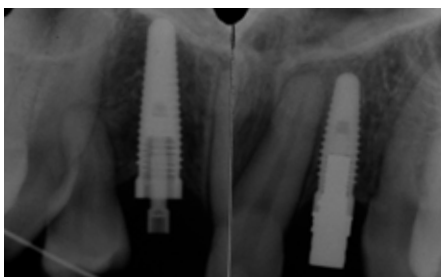

Fig. 7: The fixtures are connected to the temporary abutments. The provisionals are relined using an index matrix in the predetermined position using the diagnostic wax-up.

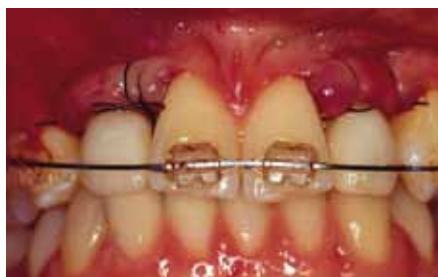

Fig. 8: Implants in place and provisional restorations repositioned without functional loading.

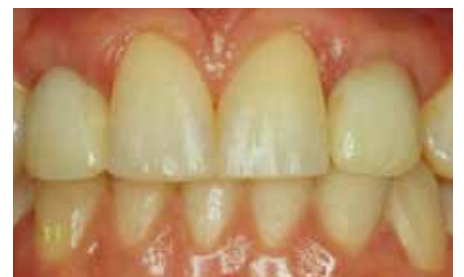

Fig. 9: Ten weeks postoperatively. The soft tissues are conditioned with the help of the provisional restorations to generate scalloped contours.

Impression-taking

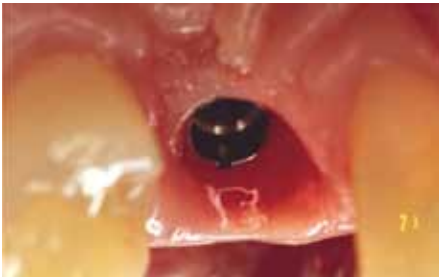

Fig. 10: Healthy soft tissues.

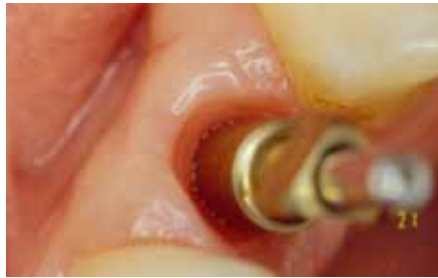

Fig. 11: Note the different geometry between the gingiva and the transfer coping.

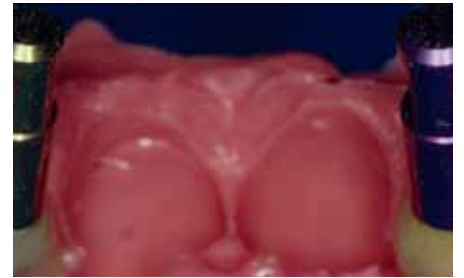


Fig. 12: Preliminary impression of the provisionals with analogs engaged for preliminary cast.

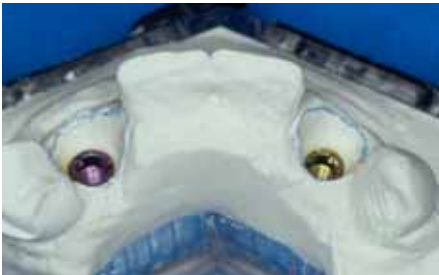

Fig. 13: The preliminary cast mimics the architecture of the soft tissues around the implants.

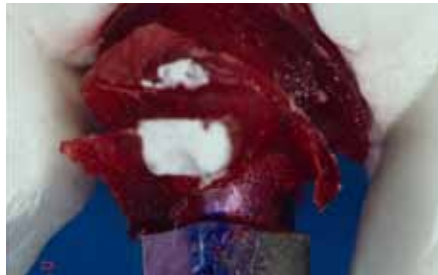

Fig. 14: Application of acrylic resin to the transfer coping will assure the conservation of the soft-tissue profile (starting from a correct preliminary cast, see figure 13).

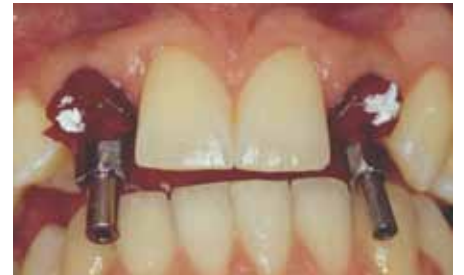

Fig. 15: Use of the customized coping maintains the previously obtained soft-tissue profile.

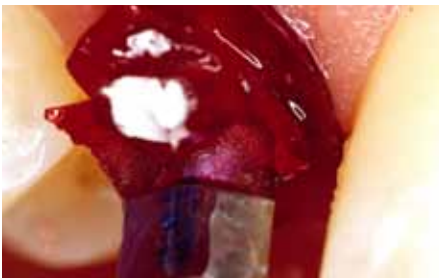

Fig. 16: Detailed view.



Fig. 17: Impression made. Note that the new-generation copings (pick-up) for the internal connections are very short.




Fig. 18: Electroplated impression phase. The cast is constructed using an electrodeposited metal and a highly stable epoxy resin able to reproduce details with an accuracy of $0.2 \mu\text{m}$.

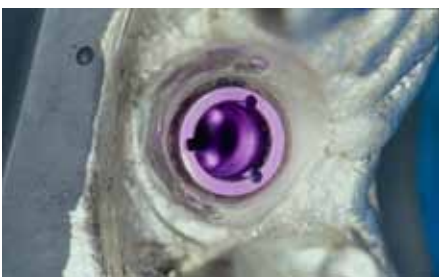


Fig. 19: The geometry of the soft tissues around the implants is the same as that of the preliminary cast (see figure 13).

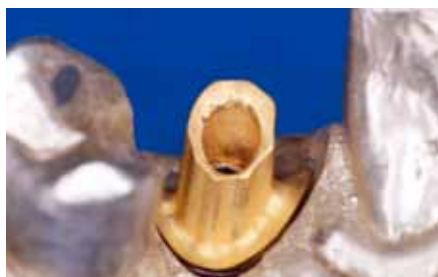

Fig. 20: Final abutment: parallel walls (0°) were created by the dental technician for correct cement-retained restoration approach.

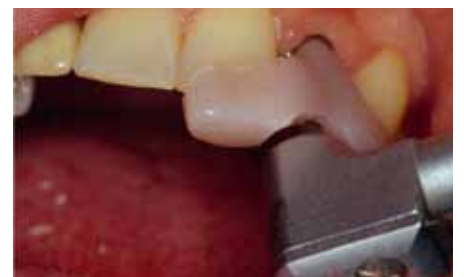

Fig. 21: An antirotational abutment positioning key is fabricated from acrylic resin, and a 20 Ncm torque is applied to reduce spatial inconsistencies.

Laboratory phase

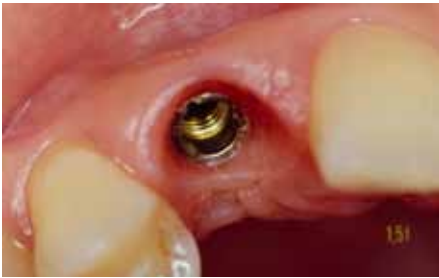

Fig. 22: Abutment connection and soft-tissue contour.

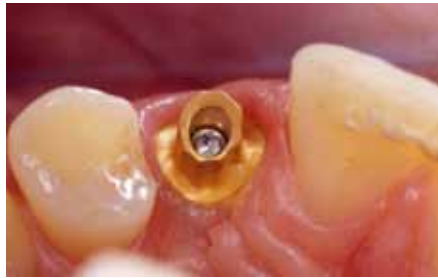

Fig. 23: Detailed view.

Restorative phase

In order to achieve a satisfying final esthetic outcome, it is necessary to also restore the distal aspects of the central incisors and the right-hand first premolar. Metal-ceramic restorations are chosen for the implant restorations because of mechanical reasons, porcelain-laminate veneers for the other teeth for a conservative approach.

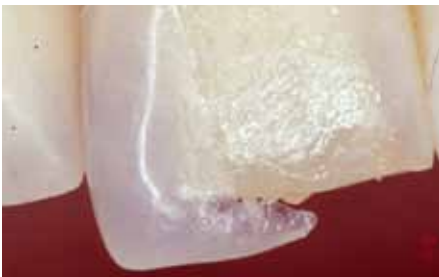

Fig. 24: The veneers are tried in.

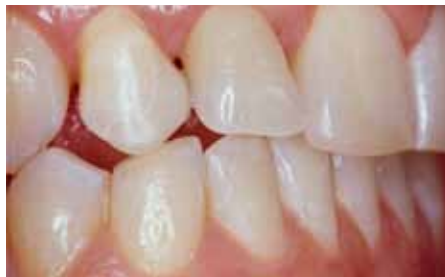

Fig. 25: The mandibular excursions are checked. The right-hand canine functions as a protection guide for the premolar veneer.

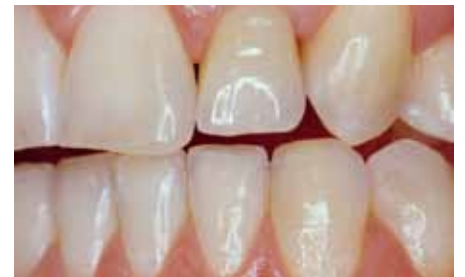

Fig. 26: The left-hand side mandibular excursion is checked.

Final outcome

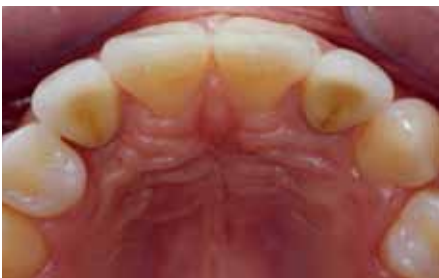

Fig. 27: Occlusal view of the final restorations.

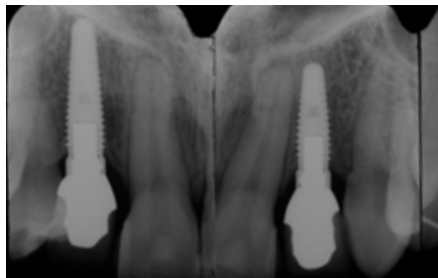


Fig. 28: Final radiograph. The palatal splint between the two central incisors was eliminated and no protection devices were provided.

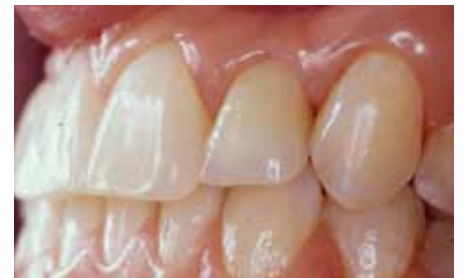

Fig. 29: Two weeks post-op. Note the proportions of the teeth and the dentogingival complex.

Long-term results

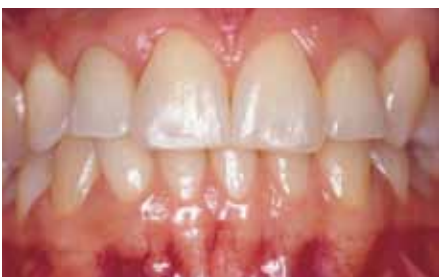

Fig. 30: Two weeks post-op. Note the proportions of the teeth and the dentogingival complex.

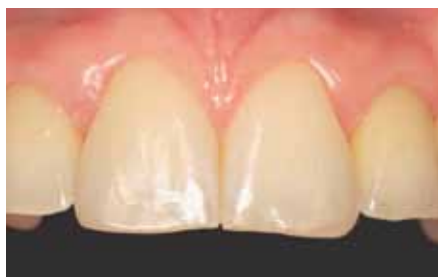

Fig. 31: Three-year follow-up.

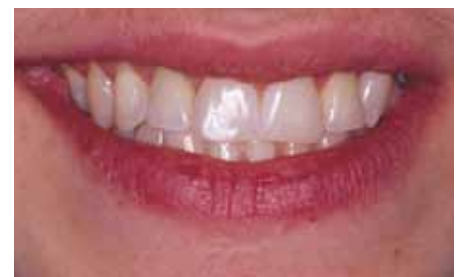

Fig. 32: Final result and smile line relations.

CONCLUSIONS

This article presents a systematic approach for restoring anterior teeth in the esthetic zone using a diagnostic additive wax-up and an interdisciplinary approach to optimize the final esthetic outcome. The case is a typical example of a previous orthodontic treatment, that did not address all existing problems with an interdisciplinary approach. The patient needed to be retreated, and communication and coordination among the operators were key factors for a satisfying esthetic result. Coordinated treatment by the orthodontist, periodontist, prosthodontist, and dental technician, with careful consideration of patient expectations and requests, were critical for the successful outcome and patient satisfaction. Comfort and esthetic outcome were ensured by a specially developed strategy to redefine an adequate smile line, that would match the unique and individual character and personality of the patient.

Initial situation

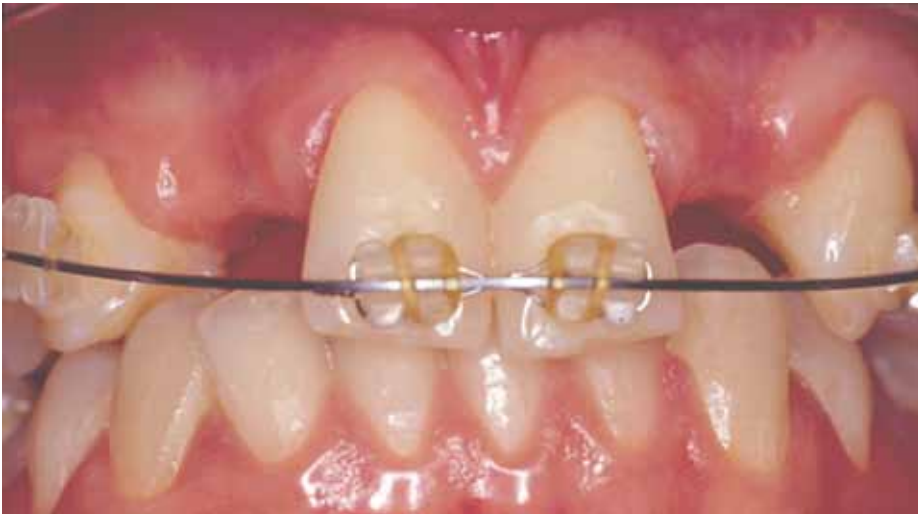

Fig. 33: Pre-surgical view.

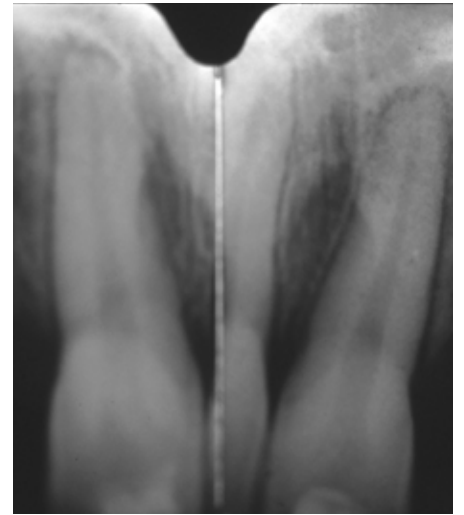


Fig. 34: Radiograph taken in the initial phase of the orthodontic treatment.

Final restoration

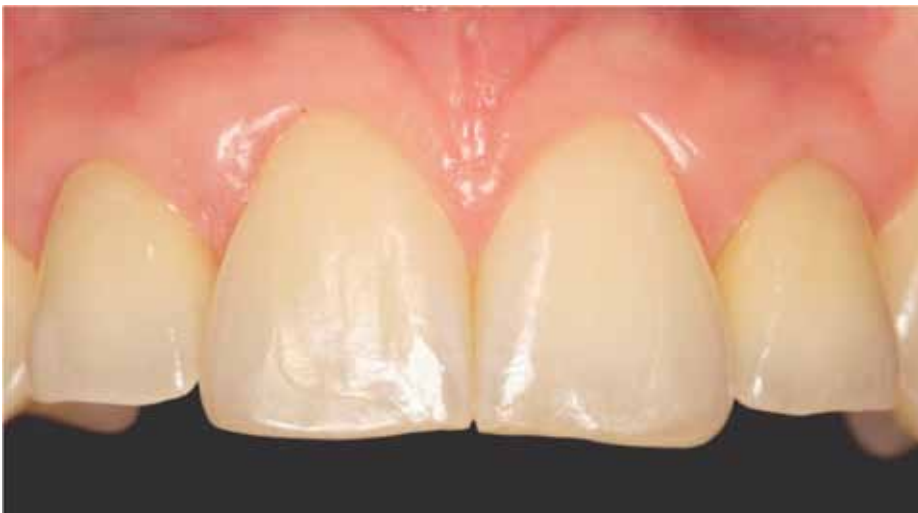

Fig. 35: Final restoration at three-year follow-up.

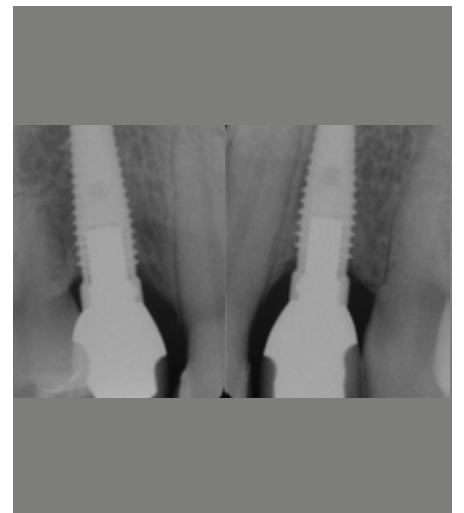


Fig. 36: Radiographic outcome at eight-year follow-up.

Based on the current concepts of implant prosthodontics, it is no longer sufficient to merely attach a prosthetic device to an underlying fixture. In fact, it has become essential to reconstruct the site with a three-dimensional approach, where the soft-tissue profile plays a crucial esthetic role. This approach invariably involves hard-tissue regeneration, which allows implant placement in the desired position, as determined by the restoration. The soft-tissue profiles are in turn generated by the actual form and contours of the prosthesis. With the impression technique presented here (Figs. 13 – 18) it is possible to preserve the transmucosal profile previously obtained and increase the stability of the transfer copings during the removal of the impression from the mouth. Moreover, the microhorizontal rotation of the transfer copings, when the laboratory implant analogs are screwed into the transfer copings, is bypassed, and the implant master cast is more accurate.

REFERENCES

SIMEONE P ET AL.

Dimensional accuracy of pick-up implant impression: an in-vitro comparison of novel modular versus standard custom trays. *Int. Journal of Oral & Maxillofac. Implants* **2011** (in press May/June).

SGRÒ S

Accurate positional impression, accurate positional cast, and antirotational transfer and positioning key in the fabrication of implant-supported prostheses. *Quintessence Dental Technology* **2005**; 27-48.

SIMEONE P, PILLONI A

Temporary Crowns: Repositioning Key as a New Technical Approach in the Clinical Relining Phase. *J Esthet Restor Dent* **16**: 284-289; **2004**.

VIGOLO P, MAJZOUB Z, CORDIOLI G

Evaluation of the accuracy of three techniques used for multiple implant abutment impressions. *J Prosthet Dent* **2003**; 89: 186-192.

GUREL G

The science and art of porcelain laminate veneers. Chicago: Quintessence Publishing Co, **2003**.

CHERUKARA GP, SEYMOUR KG, ZOU L, SAMARAWICKRAMA DY

Geographic distribution of porcelain veneer preparation depth with various clinical techniques. *J Prosthet Dent* **2003**; 89: 544-550.

CHERUKARA GP, SEYMOUR KG, SAMARAWICKRAMA DY, ZOU L

A study into the variations in the labial reduction of teeth prepared to receive porcelain veneers: a comparison of three clinical techniques. *Br Dent* **2002**; 192: 401-404.

SGRÒ S

Principles of the metal framework design in metal-ceramic reconstructions. *Quintessence Dental Technology* **2002**; 21: 52.

LANG LA, WANG RF, MAY KB

The influence of abutment screw tightening on screw joint configuration. *J Prosthet Dent* **2002**; 87: 74-79.

MAGNE P, BELSER U

Bonded porcelain restorations in the anterior dentition: a biomimetic approach. Chicago Quintessence Publishing Co, **2002**.

EDELHOFF D, SORENSEN JA

Tooth structure removal associated with various preparation designs for anterior teeth. *J Prosthet Dent* **2002**; 87: 503-509.

ZACHRISSON BU, ROSA M

Integrating esthetic dentistry and space closure in patients with missing maxillary lateral incisors. *J Clin Orthod* **2001**; 35: 221-234.

GERNHARDT CR, ULBRICH J

Aspetti morfologici del tessuto perimplantare rispetto al tessuto parodontale di denti naturali. *La Quintessenza Odontotecnica* **2000**; 11: 781-787.

WEE A

Comparison of impression materials for direct multi-implant impressions. *J Prosthet Dent* **2000**; 83: 323-331.

MAGNE P, DOUGLAS WH

Cumulative effects of successive restorative procedures on anterior crown flexure: Intact versus veneered incisors. *Quintessence Int* **2000**; 31: 5-18.

BINON PP

Implants and components: Entering the new millennium. *Int J Oral & Maxillofac Implants* **2000**; 15: 76-94.

MAGNE P, PER ROUND R, HODGES JS, BELSER UC

Clinical performance of novel-design porcelain veneers for the recovery of coronal volume and length. *Int J Periodontics Restorative Dent* **2000**; 20: 441-457.

WEE AG, AQUILINO SA, SCHNEIDER RL

Strategies to achieve fit in implant prosthodontics: A review of the literature. *Int J Prosthodont* **1999**; 12: 167-178.

MAGNE P, DOUGLAS WH

Porcelain veneers: Dentin bonding optimization and biomimetic recovery of the crown. *Int J Prosthodont* **1999**; 12: 111-121.

TAKAHASHI J, KITAHARA K, TERAOKA F, KUBO F

Resin pattern material with low polymerization shrinkage. *Int J Prosthodont* **1999**; 12: 325-329.

SGRÒ S, ELISEO M

Silver galvano-plastic. Optimising the method. *Dental Labor* **1998**; 5: 449-456.

SALAMA H, SALAMA M, GARBER D, ADAR P

The interproximal height of bone. A guidepost to predictable aesthetic strategies and soft-tissue contours in anterior tooth replacement. *Pract. Periodontics Aesthet Dent* **1998**; 10,9: 1131-1141.

MEIJERING AC, CREUGERS NH, ROETERS FJ, MULDER J

Survival of three types of veneer restorations in a clinical trial: A 2.5-year interim evaluation. *J Dent* **1998**; 26: 563-568.

SPEAR F, MATHEWS D, KOKICH VG

Interdisciplinary management of single-tooth implants. *Semin Orthod* **1997**; 3: 45-72.

MEIJERING AC, ROETERS FJ, MULDER J, CREUGERS NH

Patients' satisfaction with different types of veneer restorations. *J Dent* **1997**; 25: 493-497.

FREEMAN JE, MASKARONI AJ, LORTON L

Frequency of Bolton tooth-size discrepancies among orthodontic patients. *Am J Orthodont* **1996**; 110: 24-27.

ASSIF D, MARSHAK B, SCHMIDT A

Accuracy of implant impression techniques. *Int J Oral Maxillofac Implants* **1996**; 11: 216-222.

LEHNER CR, MARGOLIN MD, SCHARER P

Crown and laminate preparations. Standard preparations for esthetic ceramic crowns and ceramic veneers. Schweiz Monatsschr Zahnmed **1995**; 105: 1560-1575.

BINON PP

Evaluation of machining accuracy and consistency of selected implants, standard abutments and laboratory analogs. Int J Prosthodont **1995**; 8: 162-178.

NATTRESS BR, YOUNGSON CC, PATTERSON CJ, MARTIN DM, RALPH JP

An in-vitro assessment of tooth preparation for porcelain veneer restorations. J Den **1995**; 23: 165-170.

REEH ES, ROSS GK

Tooth stiffness with composite veneers: A strain gauge and finite elements evaluation. Dent Mater **1994**; 10: 247-252.

GARBER DA

Porcelain laminate veneers: ten years later: Part I: tooth preparation. J Esthet Dent **1993**; 5: 57-61.

LACY AM, WADA C, DU W, WATANABE L

In-vitro micro-leakage at the gingival margin of porcelain and resin veneers. J Prosthet Dent **1992**; 67: 7-10.

CHRISTENSEN GJ, CHRISTENSEN RP

Clinical observation of porcelain veneers: a three-year report. J Esthet Dent **1991**; 3: 174-179.

SHEERS CG, TANIGUCHI T

Advantages and limitations in the use of porcelain veneer restorations. J Prosthet Dent **1990**; 64: 406-411.

WEINBERG LA

Tooth preparation for porcelain laminates. NY State Dent J **1989**; 55: 25-28.

GARBER DA, GOLDSTEIN RE, FEINMAN RA

Porcelain laminate veneers. Chicago: Quintessence Publishing Co, **1988**.

LEVIN EL

Dental esthetics and the golden proportion. J Prosthet Dent **1978**; 40: 244-252.

LOMBARDI RE

The principles of visual perception and their clinical application to denture esthetics. J Prosthet Dent **1973**; 29: 358-382.

ACKNOWLEDGMENTS:

Thanks to:

Dr S. De Paoli, C. De Paoli, G. Leofreddi, Mr. S. Sgro CDT
for the daily cooperation!

CONTACT

Dr Piero Simeone, Prosthodontist
Via Bertoloni 1/E-Pal.F
00197 Rome
Italy
Tel. +34 06 806912899
Fax +34 06 80692066
e-mail: pierosimeone@hotmail.it

This case was first published:

Simeone P, De Paoli C, De Paoli S, Leofreddi G, Sgrò S
J Esthet Restor Dent 2007; 19: 79-89.

(Reprinted with kind permission of the publisher).

HEADQUARTERS

CAMLOG Biotechnologies AG | Margarethenstrasse 38 | CH-4053 Basel | Switzerland
Telefon +41 61 565 41 00 | Fax +41 61 565 41 01 | info@camlog.com | www.camlog.com

camlog