

Implant suprastructure restoration using CoCr CAM blanks

Stable, customised, precise—Enhancing aesthetic and functional outcomes

Prof. Maurizio Grande, Italy

Originality and individuality play a role in product development at Camlog. To meet requirements for compatibility, CoCr blanks are designed with abutment connections compatible with various implant systems, including those with Internal Hex connections.

These CoCr alloy CAM blanks enable the production of custom-milled precisely fitting non-precious metal (NPM) abutments using in-house milling machines. Based on intra-oral or model scans, both the abutment shape and the crown emergence profile can be designed and subsequently fabricated to meet individual patient requirements. In double-crown technology, CoCr offers improved sliding properties between the primary and secondary components compared to titanium.

Cobalt-chromium (CoCr) is a material widely used in dentistry due to its material properties such as high strength, durability, biocompatibility and corrosion resistance, and is not limited to model casting prostheses. With the introduction of digital technologies, the major disadvantages previously associated with the casting technique required for CoCr, such as cumulative distortion, porosity, high labour and production costs, which made finishing restorations difficult due to the material's structural hardness³, have become a thing of the past. Digital processes now allow for the production of large frameworks with greater precision and accuracy of fit, eliminating most of the disadvantages thanks to subtractive and additive manufacturing technologies.

A thorough understanding of the design of dental prostheses, their effective-

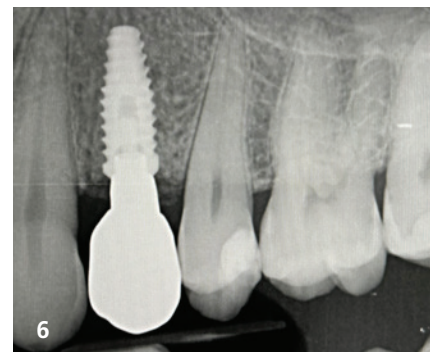
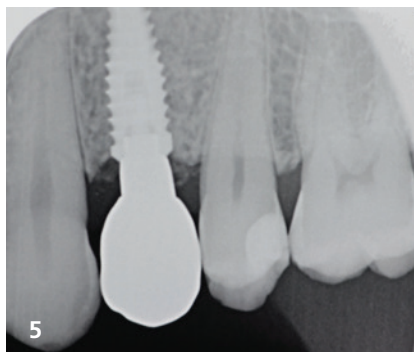
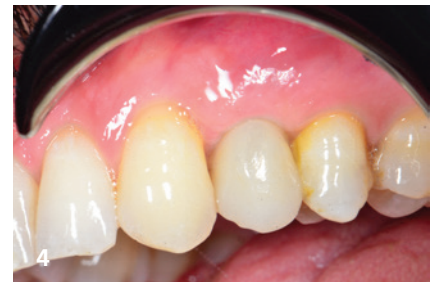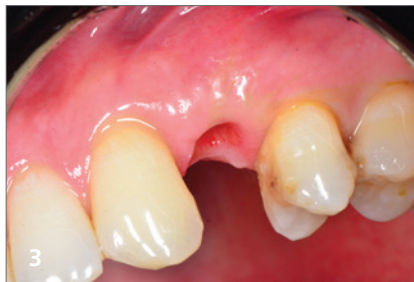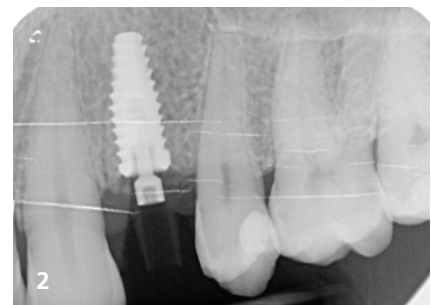
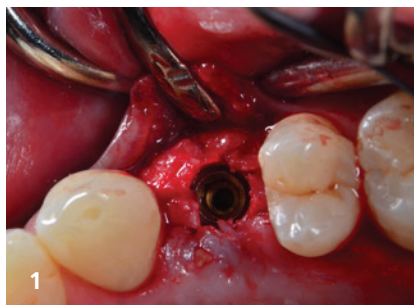


Fig. 1: Immediate implant placement with subsequent temporary immediate restoration. **Fig. 2:** X-ray control image of the immediate implant placement. **Fig. 3:** Mature peri-implant tissue before definitive restoration. **Fig. 4:** Definitive restoration. **Fig. 5:** X-ray of the abutment and the bonded zirconia crown with a hole to allow access to the screw of the CoCr abutment. **Fig. 6:** Follow-up nine months after implantation.

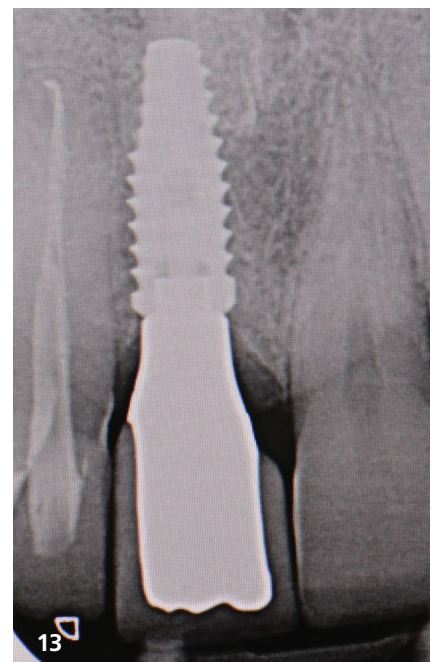
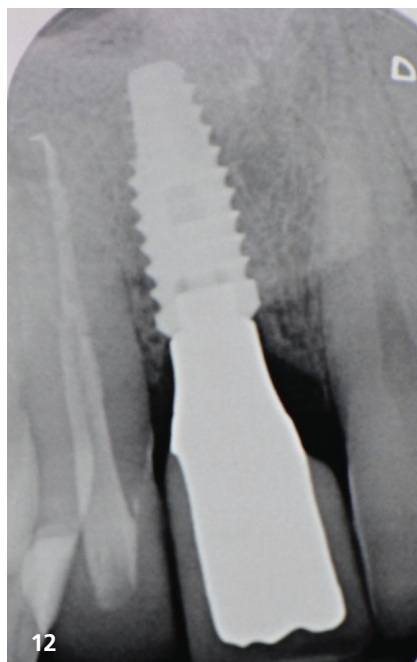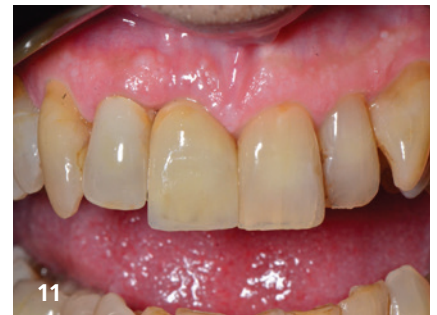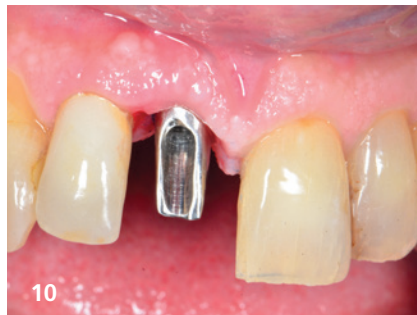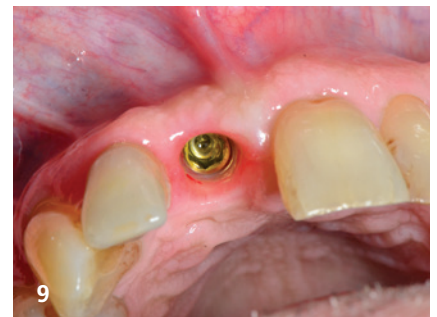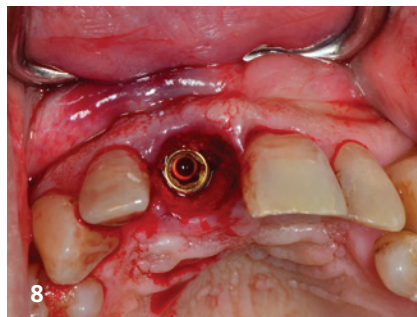
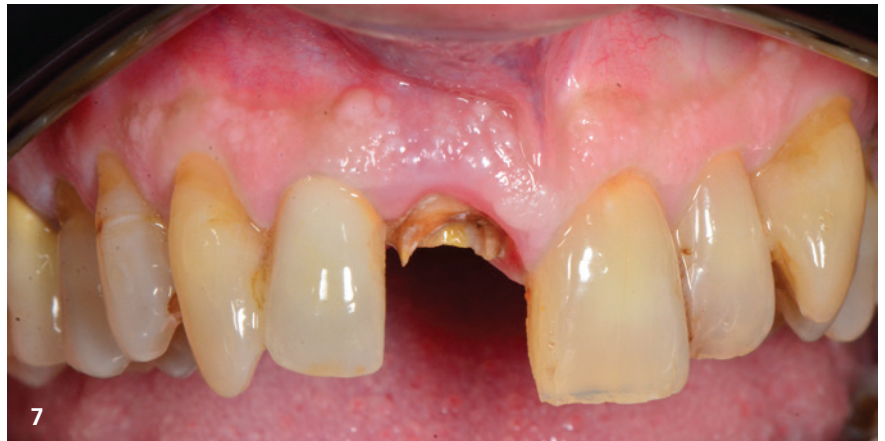ness, and potential weaknesses is essential for restoring masticatory function. CoCr alloy is particularly advantageous when it comes to aesthetically demanding removable dentures using telescopic restorations. Compared to double-crown techniques with gold alloys, which are now scarcely affordable, or electroformed secondary copings requiring reinforcement with tertiary structures. CoCr allows for the wall thicknesses of both primary and secondary components to be minimised without compromising stability. In general, CoCr alloy is easier to polish than titanium. CoCr CAM blanks are suitable for the production of digitally designed abutments with anatomical emergence profiles for crowns and bridges, as well as telescopic abutments for removable, implant-supported prostheses as strategic pillars.

The following two case reports explain the advantages of CoCr abutments in restorative and implant superstructure applications. These reports highlight the excellent workability of CoCr, which allows for a smooth, polished surface finish and the precise milling of thin walls. Due to these properties, CoCr abutments are ideally suited for demanding clinical applications and contribute to the stability and long-term durability of implant restorations.

Case 1

A 42-year-old male, non-smoker with excellent oral hygiene, received a dental implant at position #24. The inserted implant was a BioHorizons TLXP, Ø 4.6 mm x

Fig. 7: Patient presented with a broken tooth crown. **Fig. 8:** An immediate implant was inserted after the root removal. **Fig. 9:** Situation after the healing period and complete osseointegration, at the time of the final anterior restoration. **Fig. 10:** Insertion of a digitally customised CoCr abutment. **Fig. 11:** Two and a half months after insertion, the gums are perfectly adapted and completely free of inflammation. **Figs. 12 & 13:** Less crestal bone loss was recognised during the nine-month observation period; the bone at the implant shoulder is in close contact with the abutment.



L12 mm. The implant was immediately loaded on the day of surgery with a temporary restoration.

Five months post-op, a screw-retained zirconia crown was fabricated on a milled CoCr abutment, utilising a fully digital workflow and original CAM blanks from BioHorizons Camlog.

At a follow-up examination conducted two months later, the gingival tissue demonstrated ideal adaptation, with no signs of inflammation and a favourable marginal bone response. No crestal bone loss was observed during the nine-month observation period. Additionally, a reduction in probing depth was noted three months after the placement of the CoCr abutment and zirconia crown (Figs. 1–6).

Case 2

A 62-year-old male patient, non-smoker with a very good oral hygiene, presented with a dental implant at #11. The selected implant was a BioHorizons TLXP with dimensions Ø 4.6 mm x L 10.5 mm. The surgical procedure took place on 31 July 2023 and included the tooth extraction

followed by the immediate placement of the implant.

To promote optimal osseointegration while allowing for immediate functional and aesthetic results, a temporary crown was affixed on the same day of the surgery. This approach facilitated immediate loading, providing the patient with an interim restoration during the healing phase.

At the six-month mark, after sufficient healing and integration of the implant, the final restoration was completed. A custom-milled CoCr abutment was fabricated using a fully digital workflow, ensuring precision and an excellent fit. This abutment supported a cemented zirconia crown, chosen for its durability and aesthetic qualities, thereby achieving a natural and long-lasting outcome for the patient (Figs. 7–13).

Conclusion

From a dental technician's perspective, CoCr abutments offer significant advantages due to their high workability. This material allows for the creation of a smooth, polished surface finish and the

precise milling of thin walls, which is essential for many clinical applications. These characteristics make CoCr abutments ideal for achieving a refined fit and finish, enhancing both functional and aesthetic outcomes.

Clinically, hard tissue often remains in close contact with CoCr abutments, with no observable signs of crestal bone loss or marginal bone resorption. The soft tissue surrounding these abutments typically appears healthy, with no inflammation or other adverse reactions. Minimal probing depths have been recorded, and a reduction in probing depth was noted between the initial and three-month follow-up examinations. This suggests maturation of the peri-implant soft tissue, which is adapting well to the CoCr abutment.

CoCr abutments also demonstrate excellent biocompatibility, and current observations indicate that they are well-suited for clinical use. Nevertheless, while these preliminary findings are promising, extended studies and a longer observation period are necessary to confirm the long-term performance and stability of CoCr abutments.

About...

Prof. Maurizio Grande graduated in dentistry and honed his expertise in aesthetic prosthetics. He holds a postgraduate degree in prosthetics and prosthetic materials and has specialised in implant prosthetics. Over the years, he has collaborated on numerous clinical and research projects related to implant surgery. As an accomplished author, he has published extensively in national and international journals and is a sought-after speaker at various conferences and courses.

In 2004, he received the jury prize for the best original research in the dental materials section at the 11th National Congress of the College of Dentistry Teachers. Four years later, in 2008, an international jury awarded him the 1st Prize for the Esthetic Dental Care Award. Since 2012, he has been a member of the Chicago Dental Society and serves on the Editorial Board of the *International Journal of Experimental Dental Science*.

From 2016 to 2018, he was a professor at the University of Camerino. In 2018, he founded and became the president of the scientific association AGISI. Since 1996, he has been working as a freelance dentist in Rome.



Contact address

Prof. Maurizio Grande

Rome, Italy

studiomauriziogrande@libero.it

www.dottorgrande.com